

---

# FEEDLOT LAMB PATHOLOGY ATLAS

---



JOYCE VAN DONKERSGOED, DVM, MVS  
MADHU B. RAVI, BVSc, MSc, MVSc, DACVP



---

# Feedlot Lamb Pathology Atlas

---

## Contributors

### **Leo Camacho**

MVZ, Alberta Beef Health Solutions,  
Picture Butte, Alberta, Canada

### **Sydney Crosby**

DVM, MFAM, Alberta Beef Health Solutions,  
Picture Butte, Alberta, Canada

### **Joyce Van Donkersgoed**

DVM, MVS, Alberta Beef Health Solutions,  
Picture Butte, Alberta, Canada

### **Laurie Morman**

DVM, Alberta Beef Health Solutions,  
Picture Butte, Alberta, Canada

### **Jagdish H. Patel**

BVM, Diplomate ACT, Alberta Agriculture and Forestry,  
Edmonton, Alberta, Canada

### **Madhu B. Ravi**

BVSc & AH, MSc, MVetSc, Diplomate ACVP (Anatomic Pathology)  
Alberta Agriculture and Forestry,  
Edmonton, Alberta, Canada

### **Devon Wilson**

DVM, MSc student, University of British Columbia,  
Vancouver, British Columbia, Canada







To my parents, Gerrit and Johanna, who encouraged me to follow my dreams and become a food animal veterinarian; to Dr. Otto Radostits, who encouraged me to be a critical scientific thinker; and to Drs. Eugene Janzen and Ted Clark, who shared with me their passion for disease investigations and pathology. - **Joyce Van Donkersgoed**

Joyce Van Donkersgoed was raised on a mixed beef cattle and grain farm in southern Alberta. She graduated from the Western College of Veterinary Medicine in Saskatoon in 1985. After practicing 2 years in beef practice, she returned to Saskatoon to complete a Master of Veterinary Science degree at WCVM. Following that she worked as an associate professor in the Department of Herd Medicine and VIDO (Vaccine Research Institute) as a beef practitioner and researcher. She returned to Alberta and developed a consulting practice, working for the provincial government and cattle industry associations, both provincial and national, on beef quality, food safety, and environmental matters, developing producer programs, extension materials, and doing research. She returned home and started a feedlot veterinary practice which she owns and manages, providing herd health, production management, regulatory, emergency, and research services to several large feedlots, including one large lamb feedlot. Pathology is an important component of the herd health management services they provide clients as it is the most objective tool currently to understand disease processes in a feedlot, cattle or lamb and help feedlot producers prevent, treat, and control diseases, both infectious and non-infectious.



To my parents, Venkata Seshaiyah and Seetharamamma who helped me become a veterinarian; to my wife, Madhavi, for her endless support through the years; to my children, Swetha and Shreya, who are constant motivators; to all my respected teachers and mentors who encouraged me all these years; and to all who strive for improving the health and welfare of animals. - **Madhu B. Ravi**

Dr. Madhu Ravi has over 15 years of experience in veterinary pathology, including graduate studies, and over 20 years of experience as a veterinarian. He began his career in veterinary medicine in Andhra Pradesh state Animal Husbandry department, India, after receiving his BVSc & AH and MVSc (Veterinary Microbiology) degrees from ANGRAU University (presently SV Veterinary University, Tirupathi). Following immigration to Canada, he obtained a Master's degree in veterinary pathology in 2006 from the University of Saskatchewan, Saskatoon and successfully completed the national veterinary licensing board exams. He then started residency training in veterinary anatomic pathology at Western College of Veterinary Medicine, Saskatoon and attained Diplomate status in veterinary anatomic pathology from American College of Veterinary Pathologists (ACVP). Dr. Ravi worked as a Veterinary Pathologist for the University of Wisconsin School of Veterinary Medicine before joining Alberta Agriculture and Forestry in 2012. He is a published author in multiple journals and invited speaker at various meetings. He has particular interest in diagnostic pathology of food animal species with special emphasis on pathogenesis of infectious diseases. He currently resides in Edmonton with his wife, and two daughters and a canine companion.



## Preface

*“Seek and ye shall find”* (Bible) and *“You miss more for not looking than not knowing”* (Dr. Otto Radostits), are true statements when it comes to accurate disease diagnosis either in individual animals or in herd or flock disease outbreak investigations. In feedlot production medicine, whether beef cattle or lambs, a critical diagnostic tool for veterinary practitioners is gross necropsy examinations (post mortems). Complete necropsy examination entails assessing clinical, gross and microscopic lesions, looking for primary/dominant pathologies, seeking underlying contributing factors, and correlating with the observed clinicopathological aspects. The aim of this atlas is to provide small ruminant veterinarians and veterinary students with reference photographs of both gross pathology and histopathology (microscopic) lesions to help them identify disease conditions in lamb production. Pathology is the foundation of evidence-based medicine in feedlot production medicine to help veterinarians understand causes of morbidity and mortality and their epidemiology (occurrence) so that we can advise our producer clients appropriately on disease prevention, treatment, and control management strategies. This atlas is also being made available to sheep producers to help them recognize “diseased” organs when they open up a carcass and take digital photographs of tissues to share with their veterinarian. Producers are requested to use the information contained herein as general guidelines only and they should always consult their veterinarian for advice. This forward step in digital technology enables flock veterinarian to make a diagnosis remotely when distance or other factors preclude the ability of the veterinarian to do on-site necropsy.

This atlas consists of 9 chapters showing common diseases in Canadian lamb feedlots of the cardiovascular (heart and circulatory), respiratory (lungs), hepatic (liver), urinary (bladder, kidneys), nervous (brain), integumentary (skin) and musculoskeletal (muscle, bones), reproductive (uterus, neonatal lambs) systems, and miscellaneous. Images of gross pathology lesions are presented along with histopathology pictures showing microscopic lesions in tissues. In most cases small ruminant veterinarians will make clinical diagnoses based on gross pathology lesions observed during a necropsy. In cases where the veterinarian is not sure of a diagnosis, they may submit tissue samples to a pathology laboratory for confirmation of a diagnosis by a pathologist. The histopathology pictures are there to remind veterinarians what the lesions look like microscopically in various disease conditions.

We hope this atlas provides value to the Canadian sheep industry and small ruminant veterinarians.

## Acknowledgments

The authors gratefully acknowledge the Alberta Agriculture and Forestry pathology laboratory staff, Korina Smith, Laura Elliott, Nancy Perrin, Ludovic Silasi (retd.), Sheila Hart-Lehman and Lynne Becker for their participation in the lamb mortality project. Our thanks to Lisa Zeldenrust, histotechnologist, Agri-Food laboratories for preparing high-quality histological sections. We thank Karen Schwartkopf-Genswein and fellow researchers from the Lethbridge Research Station for contributing photos of lame sheep. Maria Spinato, Paula Menzies, Andrew S. Peregrine, and Chanel Schwartztruber from the University of Guelph, Alex Reid from OMAFRA, and Fiona Lovatt from the UK are gratefully acknowledged for their contributing photos. The Canada Gold Lamb Feedlot, and in particular Alfonso Osornio, feedlot foreman, is thanked for participating in both the Lamb Mortality Project and the Lamb Lameness project where the majority of these images were collected. Alberta Livestock Marketing Agency (ALMA) and Alberta Agriculture and Forestry are thanked for their financial contributions to both the Lamb Mortality and Sheep Lameness Research projects at the lamb feedlot that resulted in the collection of these digital images. Merck Animal Health is acknowledged for publishing this atlas to help us disseminate information to the Canadian sheep industry, including producers, small ruminant veterinarians, and veterinary and pathology students.



---

# Feedlot Lamb Pathology Atlas

---

## C O N T E N T S

I.	DISEASES OF CARDIOVASCULAR AND HEMOLYMPHATIC SYSTEMS .....	1
II.	DISEASES OF THE RESPIRATORY SYSTEM ..	29
III.	DISEASES OF THE GASTROINTESTINAL SYSTEM .....	91
IV.	HEPATOBIILIARY SYSTEM .....	131
V.	URINARY SYSTEM .....	157
VI.	REPRODUCTIVE AND ENDOCRINE SYSTEMS .....	173
VII.	NERVOUS SYSTEM.....	195
VIII.	INTEGUMENTARY AND MUSCULOSKELETAL SYSTEMS.....	203
IX.	MISCELLANEOUS.....	227

© 2018. All rights reserved.

Intervet Canada Corp., subsidiary of Merck & Co., Inc.  
16750, route Transcanadienne  
Kirkland, QC H9H 4M7  
1 866-683-7838

# I. DISEASES OF CARDIOVASCULAR AND HEMOLYMPHATIC SYSTEMS

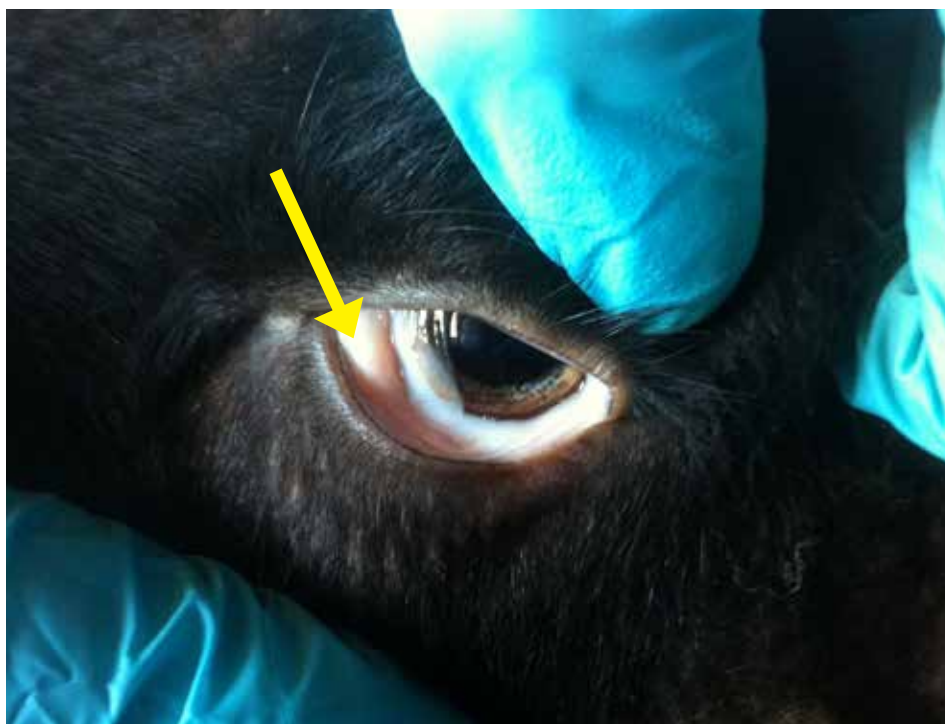1. Anemia due to <i>Haemonchus contortus</i> .....	2
2. Arterial Aneurism and Rupture .....	7
3. Caseous Lymphadenitis .....	9
4. Cysticercosis .....	10
5. Right Side Heart Failure .....	13
6. Left side Heart Failure .....	21
7. Pericarditis and Epidarditis .....	21
8. Interstitial Myocarditis.....	24
9. Myocardial Abscessation .....	25
10. Necrotizing Myocarditis .....	28



## I. DISEASES OF CARDIOVASCULAR AND HEMOLYMPHATIC SYSTEMS

### 1. Anemia due to *Haemonchus contortus*

Anemia is a condition that develops when animals lack enough healthy red blood cells and haemoglobin. Anaemia is manifested clinically as pale mucous membranes of gums and palpebral conjunctiva, lethargy and reluctance to move around. Moderate to severe infection with *Haemonchus contortus*, a blood sucking nematode of the abomasum, commonly called the Barberpole Worm (Haemonchosis) is a common cause of anaemia in pastured lambs and sheep. In acute and chronic cases lambs develop generalized edema (fluid accumulation) secondary to hypoproteinemia, along with mild to very severe anemia. Haematocrit (indicator of red blood cell count) values are often  $< 15\%$  (normal 25 – 35%). The FAMACHA<sup>®</sup> scoring method of determining level of anaemia and the need to treat with an anthelmintic, uses a card developed by South African researchers to assess the colour of the palpebral conjunctivae. Scores of 1 and 2 indicate no anaemia; 3 possible anaemia and 4 and 5 of severe anaemia; this information is used to implement targeted treatment of affected animals. This also allows producers to maintain a “refugia” of untreated parasites; this reduces the development of anthelmintic resistance on a farm. ‘Refugia’ is a proportion of the total parasite population that was not selected for antiparasite treatment.



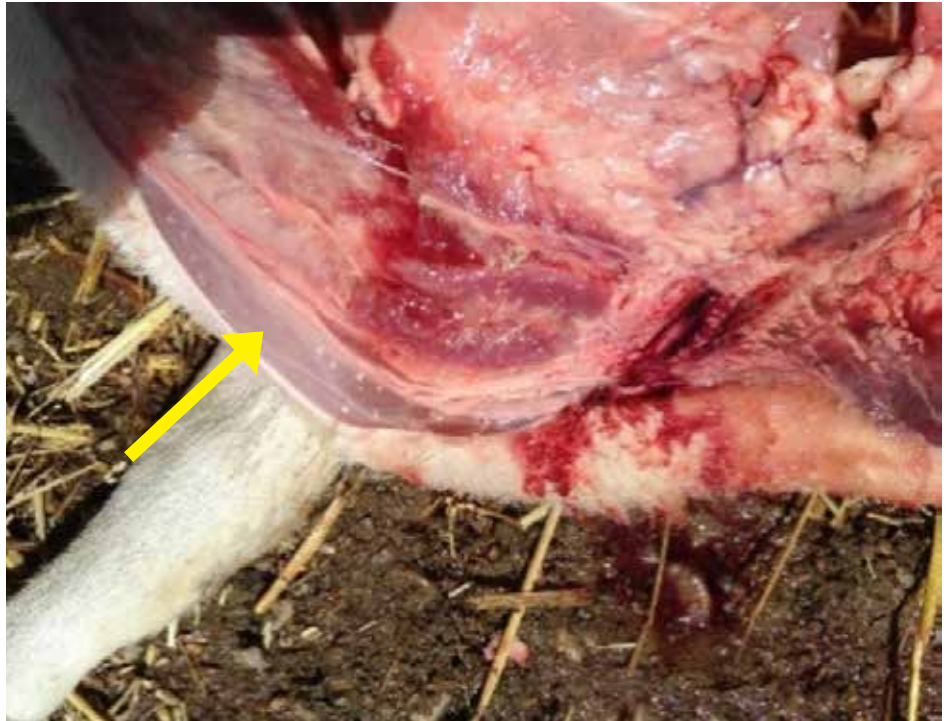**Figure 1.1.1.**

Paler palpebral conjunctiva in an anemic lamb. Severity of anemia can be estimated by assessing the colour of the palpebral conjunctiva (yellow arrow). PCV (blood packed cell volume) and FAMACHA scores of 4 or 5, are good indicators to identify anemic animals caused by *H. contortus* (barberpole worm) infestation. American Consortium for Parasite Control ([www.wormx.info](http://www.wormx.info)) is an excellent online source for information on FAMACHA<sup>®</sup> scoring and general parasite control.

*Photo courtesy of Chantel Schwarzentruher.*

**Figure 1.1.2.**

Brisket edema in a lamb died due to severe haemonchosis.

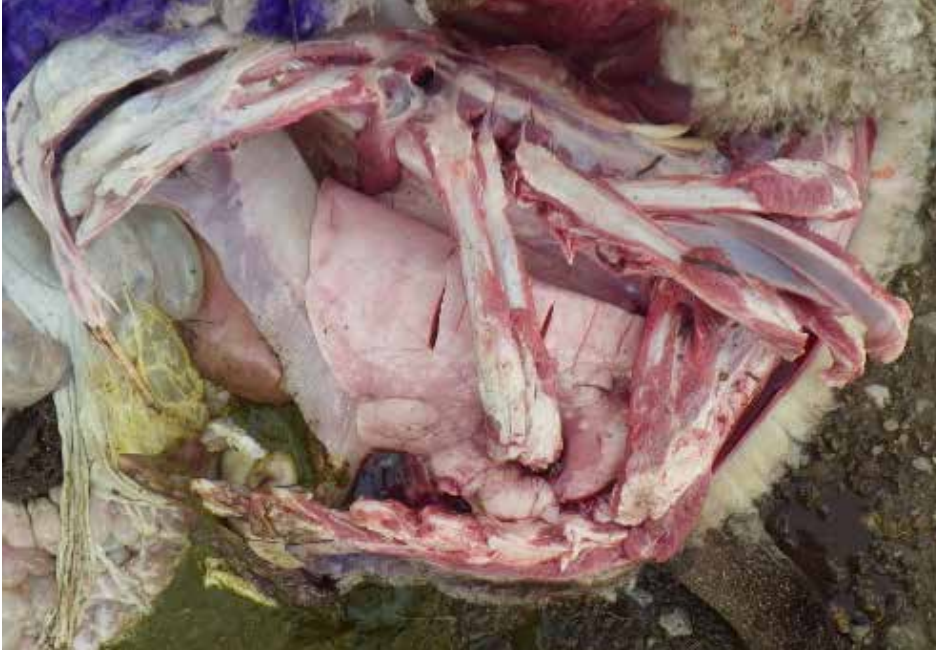

**Figure 1.1.3.**

Edema of submandibular tissues in a lamb due to hypoproteinemia as a result of haemonchosis.







**Figure 1.1.4.**

Lung and tissue pallor is a common finding in anemic lambs died of severe haemonchosis.

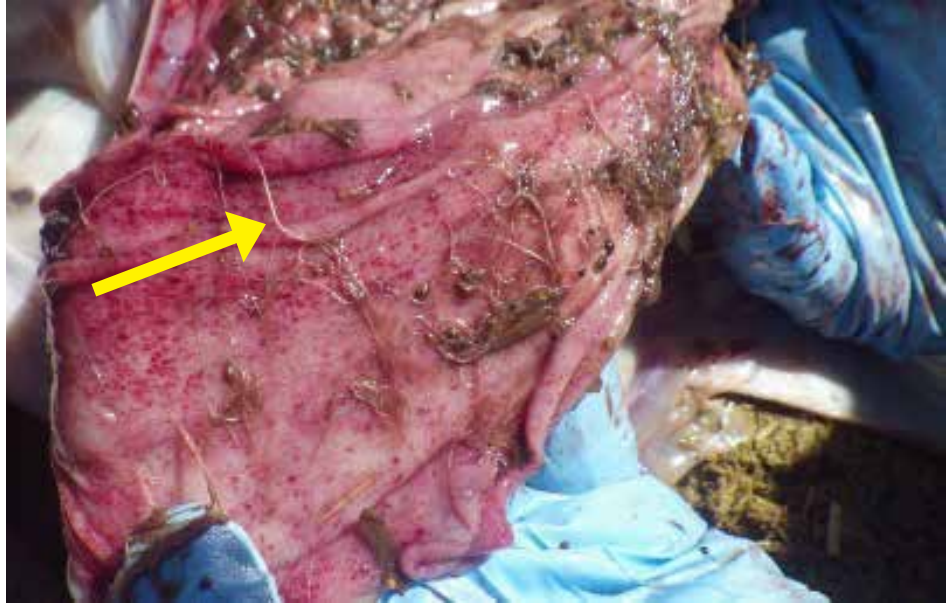

**Figure 1.1.5.**

Many *Haemonchus contortus* worms in the abomasal contents.

**Figure 1.1.6.**

*Haemonchus contortus* infestation in the abomasum of a sheep. *H. contortus* feeding causes abomasitis.

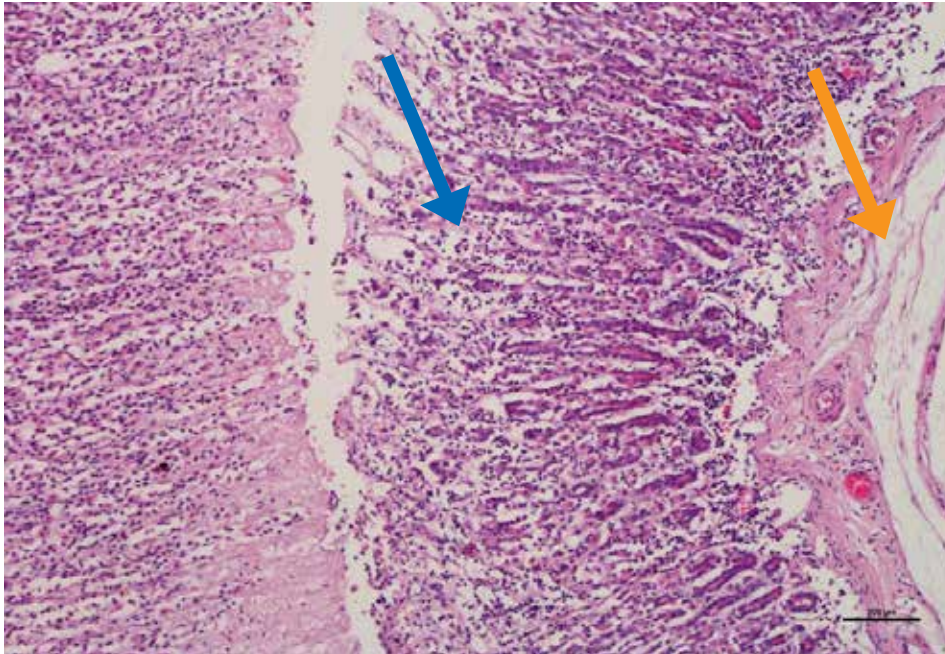


**Figure 1.1.7.**

*Haemonchus contortus* or “Barber Pole” worm. Female worms appear striped due to the blood-filled intestinal tract wrapped around the pale reproductive tract.







**Figure 1.1.8.**

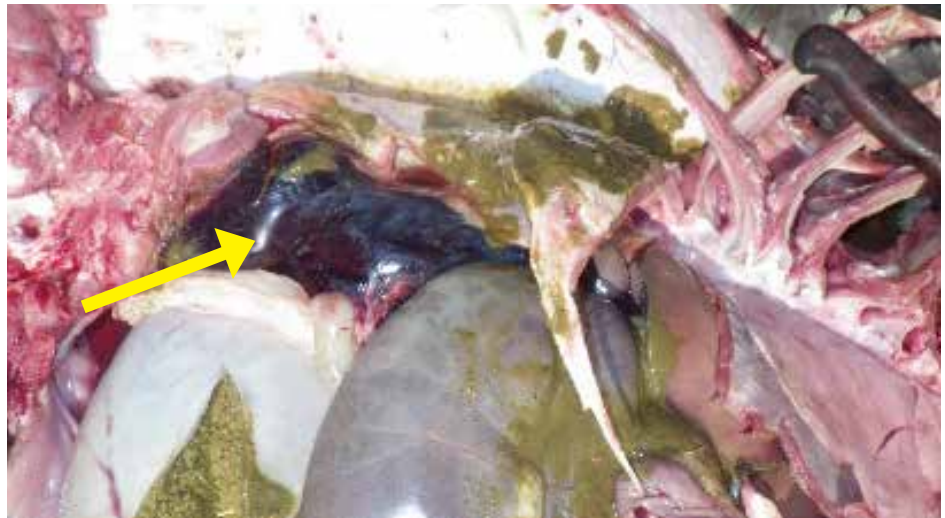Histologically there is evidence of abomasitis with inflammatory cells (blue arrow) infiltrating the mucosa in lamb with Hemochrosis. Additionally, there is and edema of the abomasal wall (orange arrow) which is a common finding in lambs died due to heavy stomach worm infestation due to protein loss.

## 2. Arterial Aneurism and Rupture

Rupture of major arteries and resultant death is rare in sheep. It usually occurs at the site of aneurism. The cause of arterial aneurism and rupture is not completely understood. Copper deficiency has been proposed as a possible causative factor for arterial aneurism and rupture in cattle. It may also be induced by trauma or gas or frothy bloat.

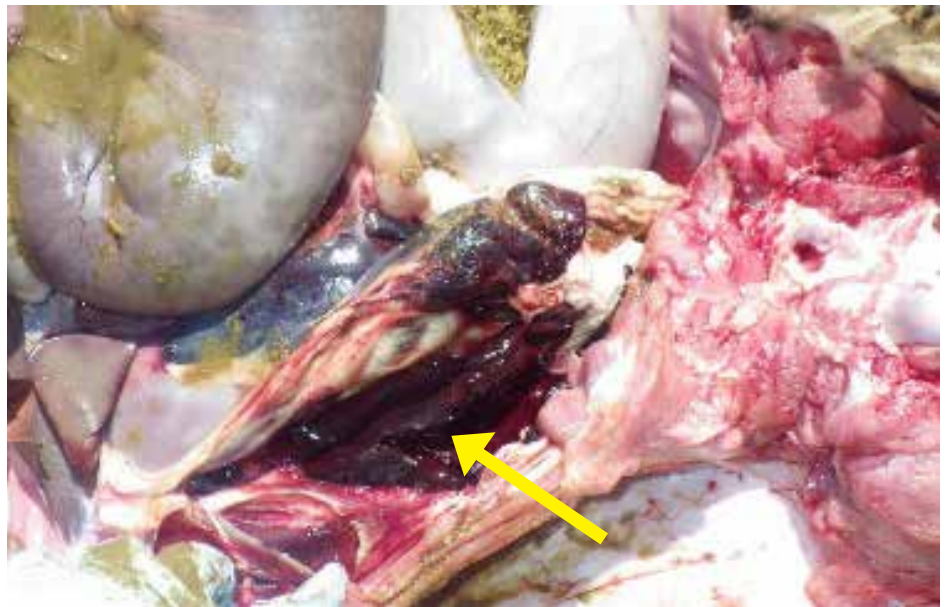
**Figure 1.2.1.**

Blood clot in the abdomen was traced back to a ruptured aorta in a feeder lamb that died due to internal bleeding.

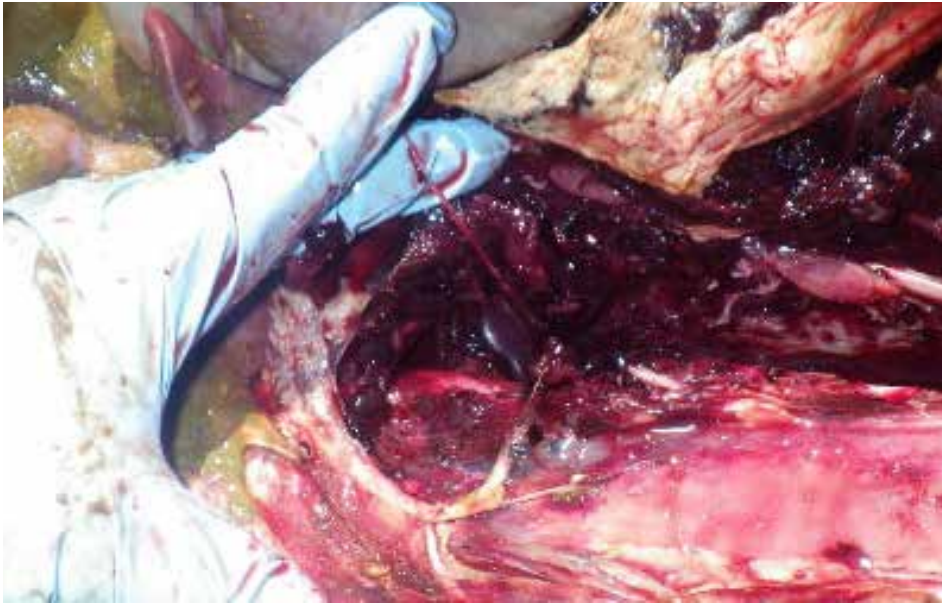


**Figure 1.2.2.**

Large blood clots in the abdomen can be caused by a rupture in a large blood vessel like the renal artery.

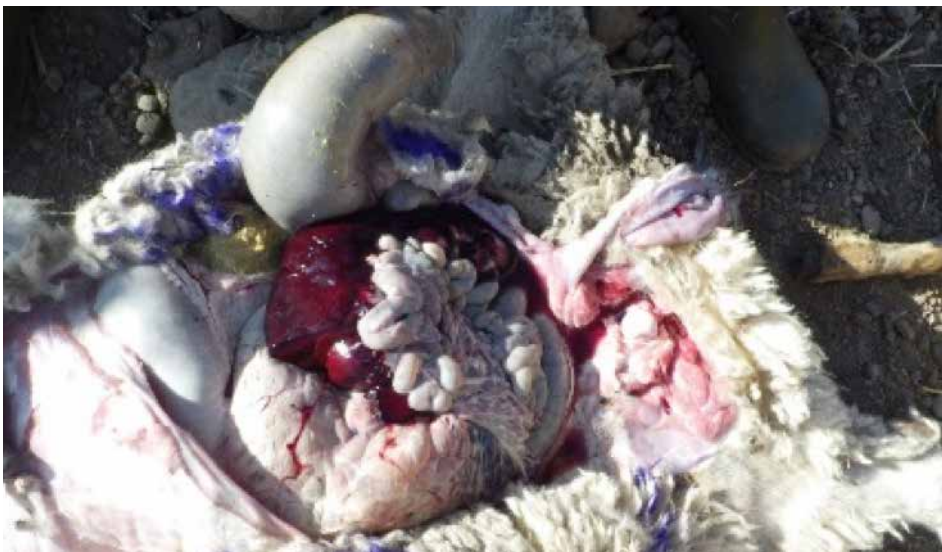





**Figure 1.2.3.**

Large blood clots in the chest can be caused by a rupture in a large blood vessel like a pulmonary artery.



**Figure 1.2.4.**

Large blood clots in the abdomen can be caused by a rupture in a large blood vessel like renal artery or caudal aorta. Hepatic (liver) rupture can also cause blood in the abdomen. This may be due to trauma.



### 3. Caseous Lymphadenitis

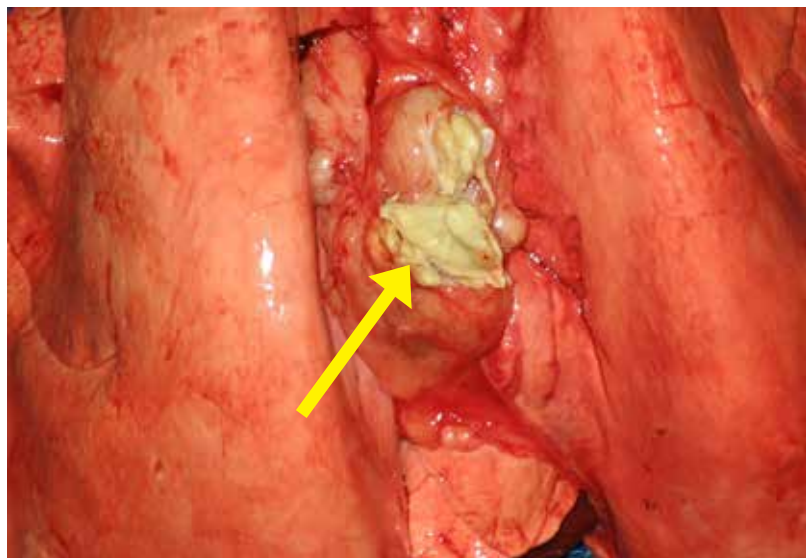
**Figure 1.3.1.**

Note swollen submandibular lymph nodes in a sheep. Caseous lymphadenitis (CL) is a chronic, contagious disease caused by the bacterium *Corynebacterium pseudotuberculosis*. The disease is characterized by abscessation of peripheral (external) and internal lymph nodes as well as internal organs such as the lungs, liver and kidneys, pituitary gland and vertebral body abscesses.

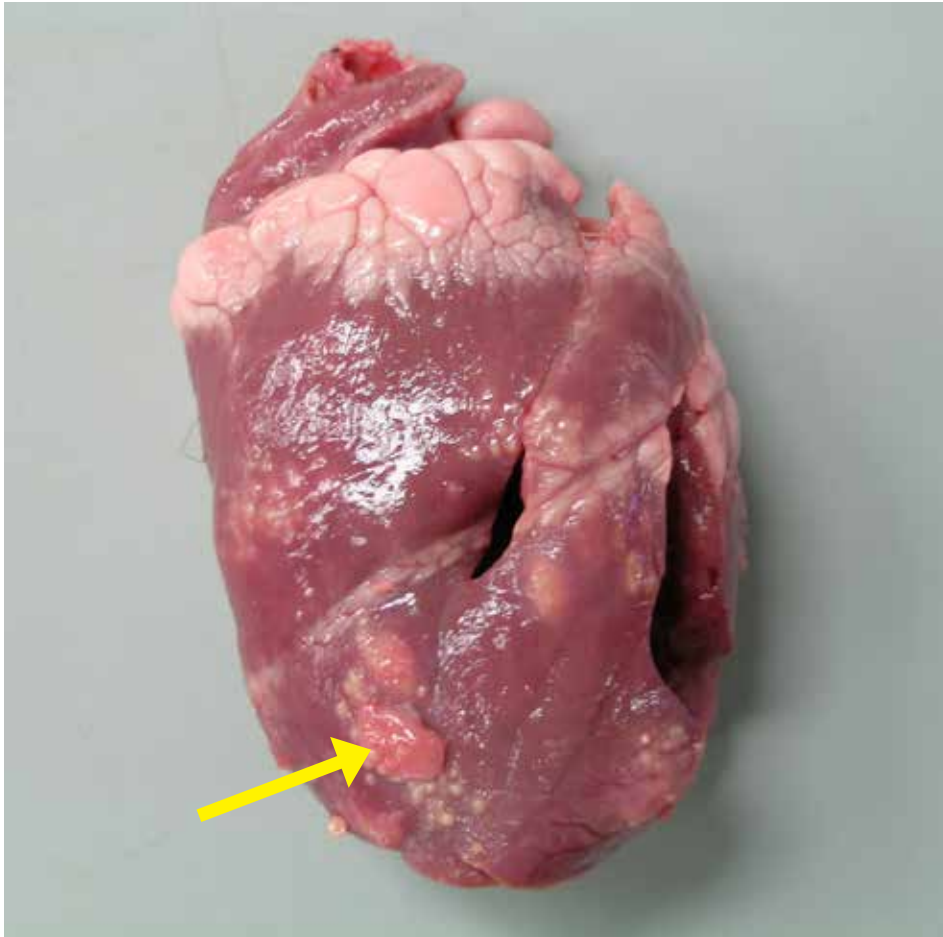


**Figure 1.3.2.**

Caseous lymphadenitis (CL) in a ewe showing abscessation of mediastinal lymph node (arrow).  
*Photo courtesy of Dr. Paula Menzies.*



#### 4. Cysticercosis (Sheep Measles)



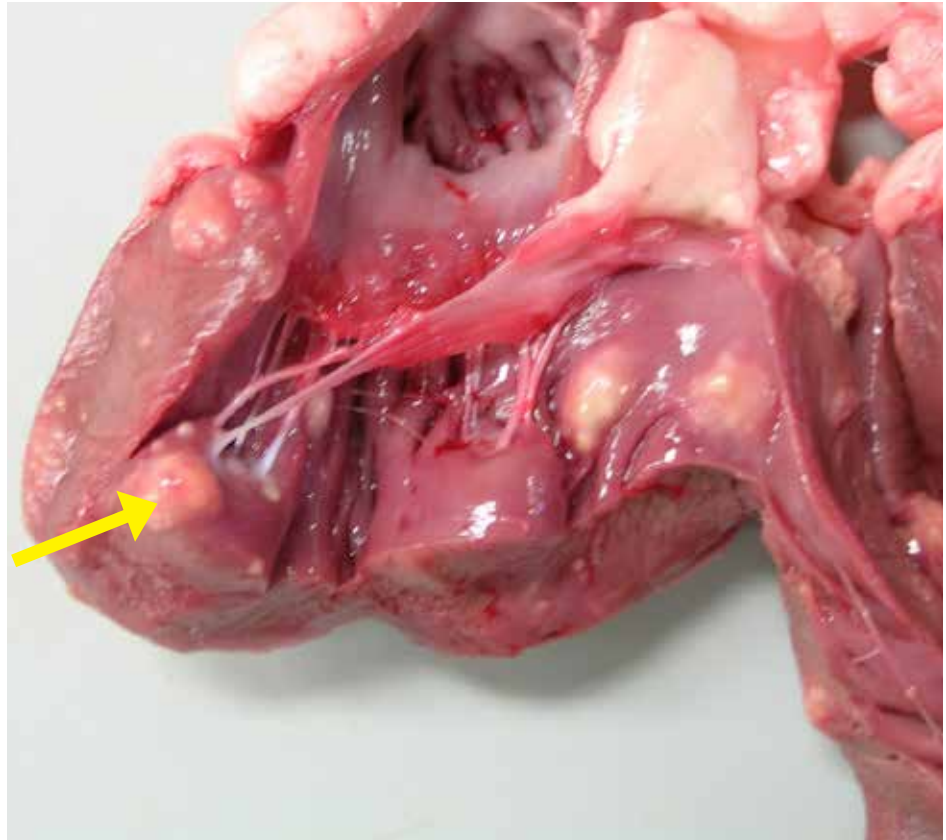
**Figure 1.4.1.**

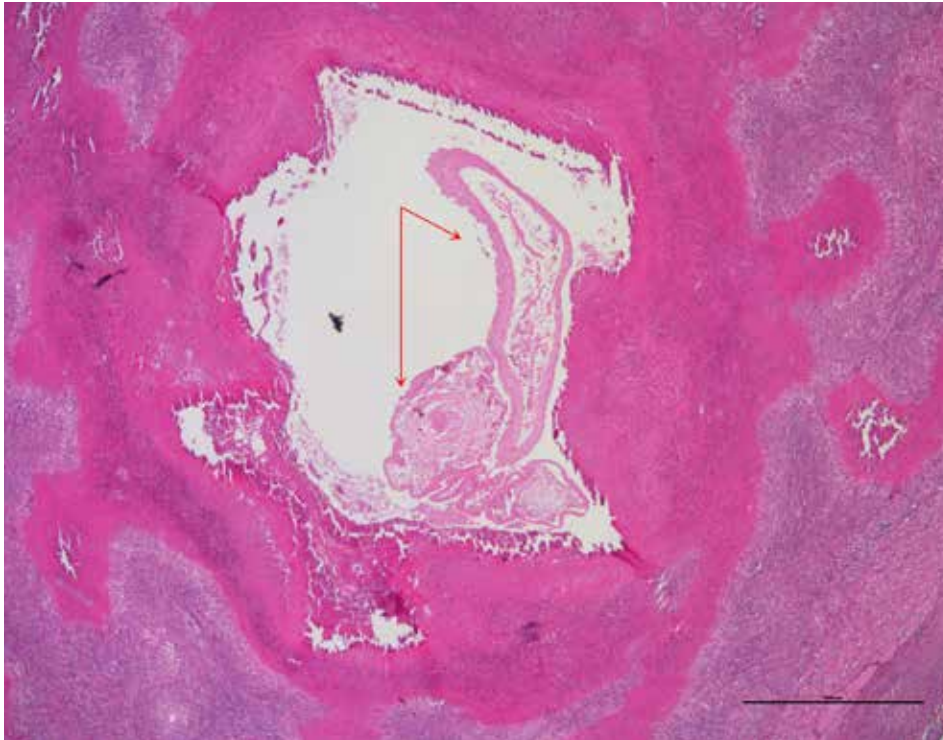
Heart from a feeder lamb showing nodular lesions caused by larval migration of *Taenia ovis*. The adult tapeworm lives in the intestines of domestic dogs and wild canids (i.e. coyotes, foxes, wolves). Infections have been documented rarely in cats. Tapeworm segments, which contain thousands of eggs, are passed in the feces and contaminate the environment including bedding and pasture. Eggs can survive in the environment for three to twelve months and are ingested by sheep/ goats. Eggs hatch in the intestine and the larvae penetrate the intestinal wall and are carried through bloodstream to skeletal and cardiac muscles (e.g. tongue, masseter muscles, heart, diaphragm and skeletal muscles). Each larva develops into fluid filled cyst that can be seen grossly. These cysts over time degenerate and the dead cysts are often seen as hard calcified nodules due to inflammatory response at slaughter inspection in the muscles as shown here in the heart. This condition causes condemnation of lamb carcasses due to public health risk and the tissue's esthetic appearance.

**Figure 1.4.2.**

Heart dissected from the same lamb with variably sized firm nodular lesions in the heart walls. In heavy *Cysticercosis* infestations, the affected carcass will be condemned and lightly infected carcasses will be passed for consumption after trimming the affected tissues.

If a canid e.g. dog, eats raw infected meat from sheep that contain live cysts, the larval tapeworm will develop into an adult in the intestines of canids e.g. dogs, coyotes, and the cycle will continue. Once the lamb is infected there is no treatment that can remove the cysts. Most important control measure is periodic deworming of dogs for tapeworms, proper disposal of deadstock to prevent scavenging by dogs/coyotes and proper storage of feed to prevent contamination of feed with dog/canid feces.





**Figure 1.4.3.**

Histologically chronic granulomatous and eosinophilic myocarditis with intra-lesional degenerate *Cysticercus* cestode larvae (arrow) are seen in the heart muscles sections.

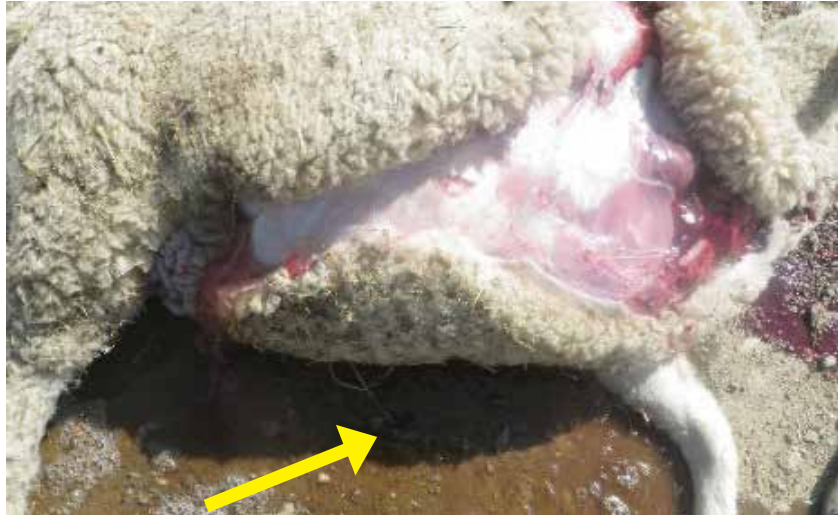

## 5. Right Side Heart Failure

Sudden death due to heart failure is occasionally seen in growing lambs. Grossly, ascites (fluid in the abdominal cavity), hydrothorax (fluid in the chest cavity), and a congested liver were noted. Clear yellow fluid on ground (arrow) that came from the belly and chest.

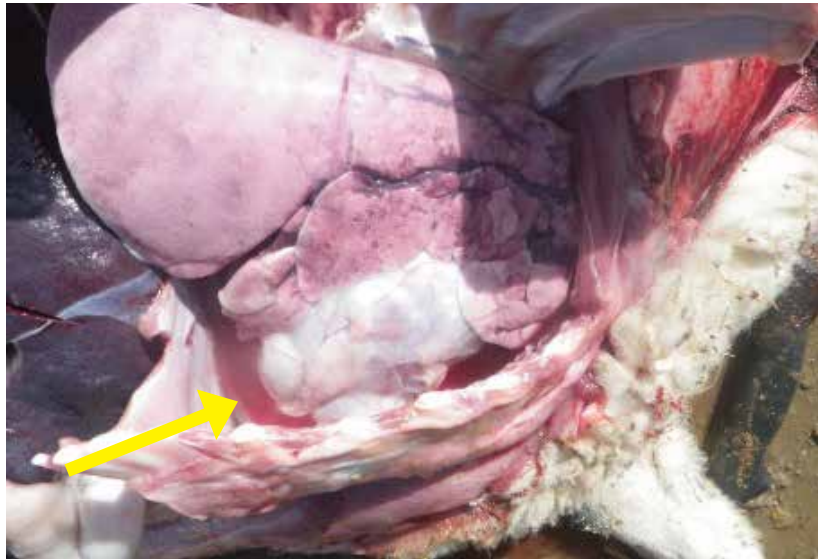
**Figure 1.5.1.**

Lamb died due to heart failure. White muscle disease was diagnosed in this lamb. Arrow shows fluid coming out of abdomen through incision.



**Figure 1.5.2.**

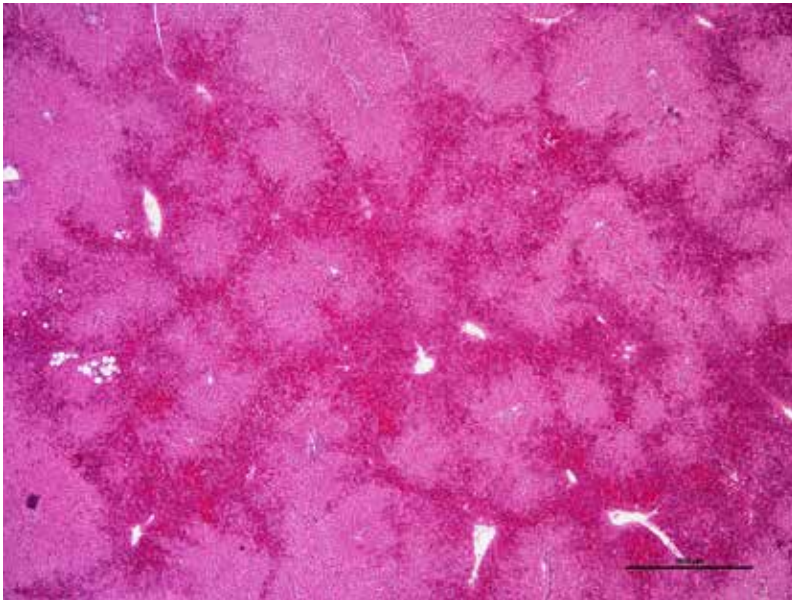
Hydrothorax with fluid accumulation in the thoracic cavity was noted.





**Figure 1.5.3.**

Enlarged heart with dilated ventricles.

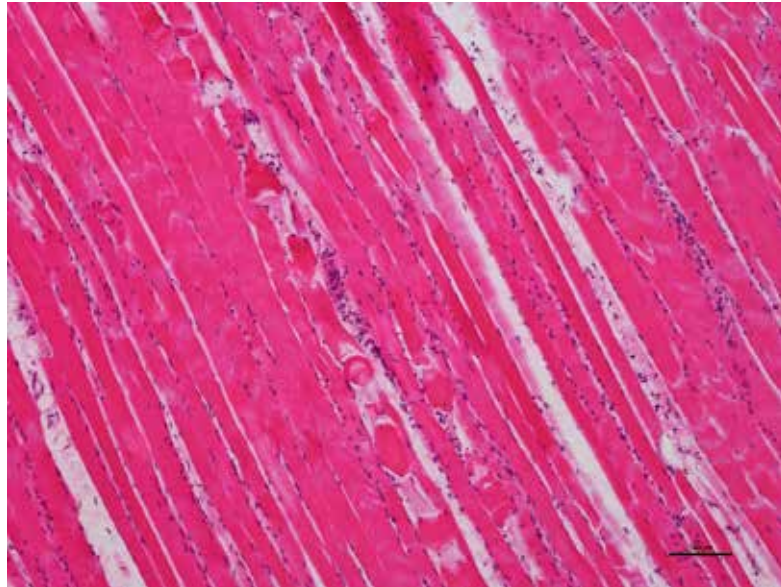


**Figure 1.5.4.**

Liver showing acute passive centrilobular congestion in the lamb that died due to right heart failure.

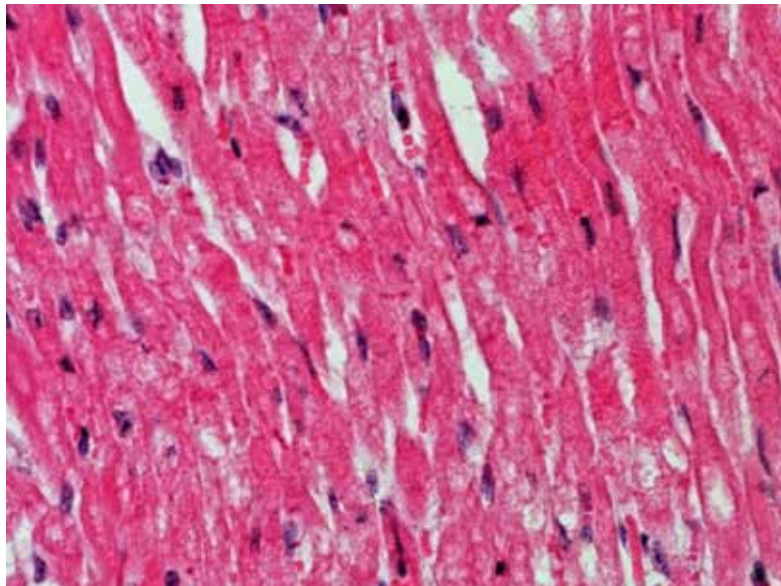
**Figure 1.5.5.**

Histology of skeletal muscle (diaphragm) showing degenerative and necrotic changes with wavy muscle fibers, segmental granular and fragmented sarcoplasm with minimal inflammatory response. Similar changes are noted in the heart muscles fibers.

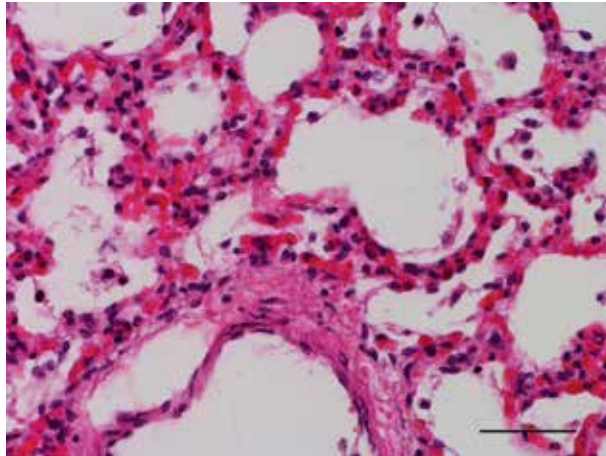


**Figure 1.5.6.**

Heart muscle showing acute myofiber degeneration and necrosis. The common differential diagnosis based on the histological lesions in skeletal and heart muscles include vitamin E/SE deficiency, exposure to high concentrations of ionophores in the diet and ingestion of cardiotoxic plants (white snake root, Xanthium etc.).

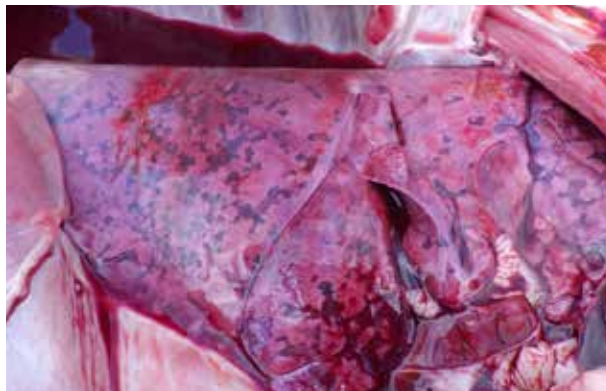





**Figure 1.5.7.**

Lung from a lamb that died due to congestive heart failure showing diffusely congested alveolar septae and alveolar lumen showing evidence of pulmonary edema with foamy macrophages.

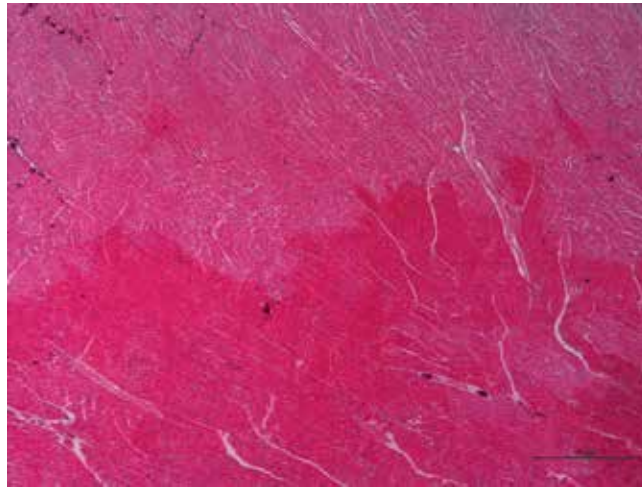


**Figure 1.5.8.**

An enlarged and congested lung (dark red areas) was noted in a lamb that died due to right heart failure.

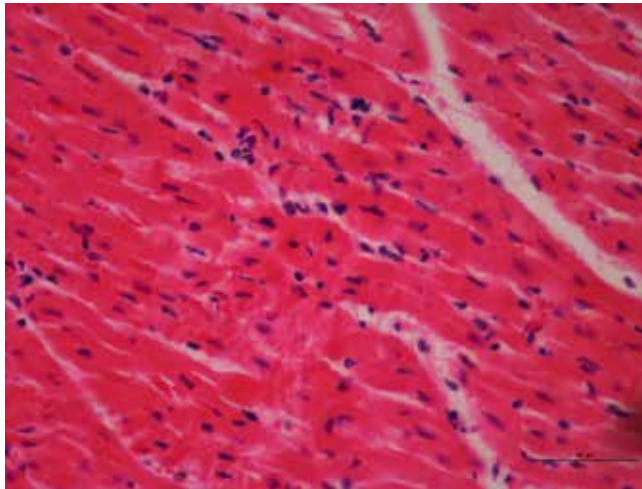
**Figure 1.5.9.**

Histologically, there were extensive areas of acute myocardial degeneration and necrosis in the heart.



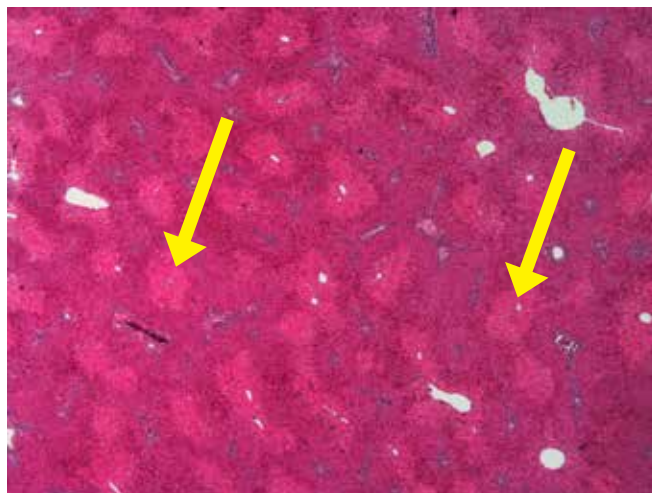
**Figure 1.5.10.**

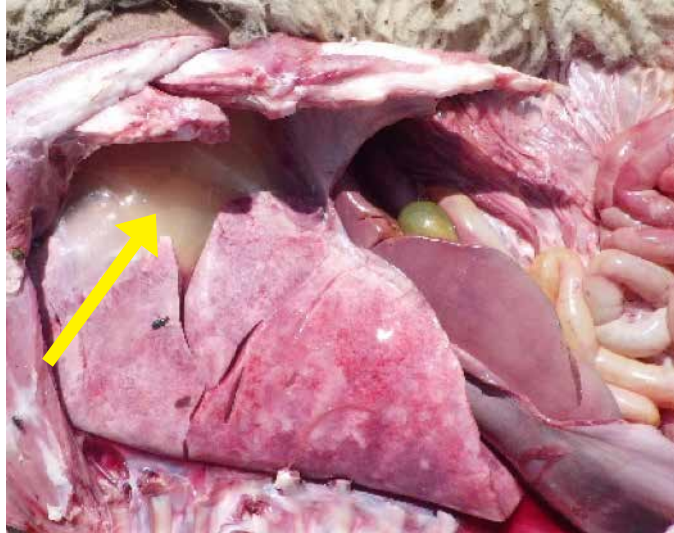
Close up view of myocardial degeneration and necrosis in the heart of a lamb that died due to right heart failure.



**Figure 1.5.11.**

Passive congestion of liver with paler centrilobular areas (arrows) noted histologically in the same lamb that died due to right heart failure.





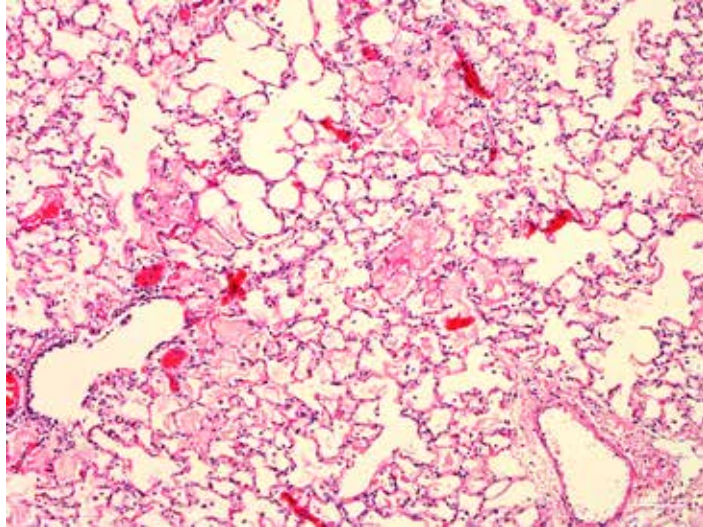
**Figure 1.5.12.**

Hydrothorax and hydropericardium in lamb died due to heart failure caused by selenium deficiency (white muscle disease/ Nutritional Myopathy). Lung lobes did not collapse and were heavy due to diffuse congestion and edema. White muscle disease is caused by a deficiency of selenium and/or vitamin E in animals. It causes two distinct syndromes in lambs: cardiac form and skeletal form. Both forms affect young, rapidly growing lambs. Neonates are most commonly affected with the cardiac form if their dams are deficient in selenium and / or vitamin E. Animals affected with the cardiac form typically show respiratory distress with foamy blood tinged nasal discharge, profound weakness, recumbency and sudden death due to heart failure. Post mortem findings include ascites (fluid in the abdominal cavity), hydrothorax (fluid in the chest cavity), hydropericardium (fluid around the heart), pale streaks in cardiac (heart) and skeletal muscles (e.g. diaphragm, intercostal and tongue) congested edematous lungs and congestion of liver.



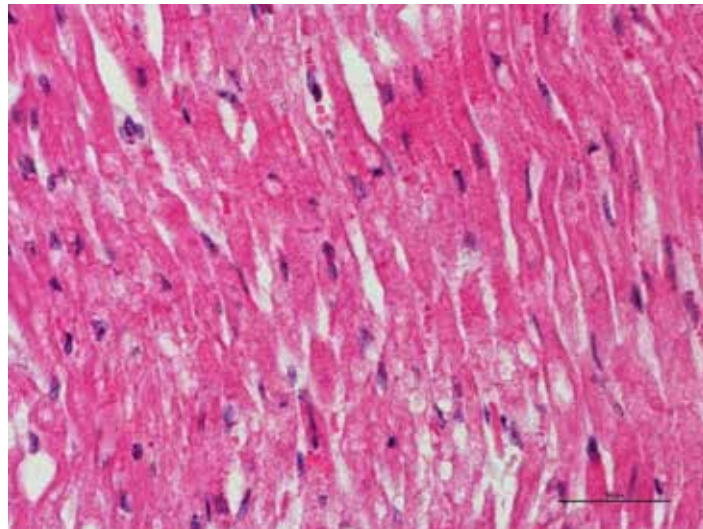
**Figure 1.5.13.**

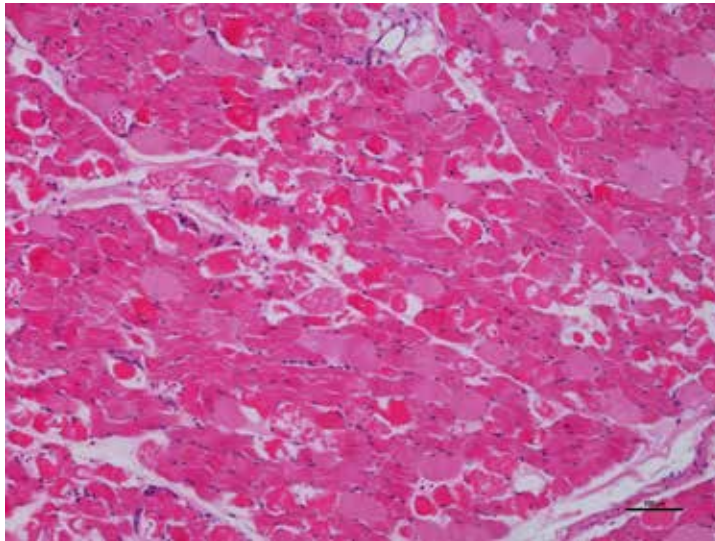
Histologically, lung tissue showing congested capillaries and alveolar lumina filled with pale eosinophilic homogenous material (edema) admixed with foamy macrophages.



**Figure 1.5.14.**

Histologically, heart muscle showing acute myocardial degeneration and necrosis with fragmentation of sarcoplasm, hypereosinophilia, loss of cross striations and nuclear changes. White muscle disease in live animals can be diagnosed by measurement of selenium in whole blood and serum, and vitamin E levels in the serum. Selenium and vitamin E levels in the body can be determined by analysis of liver tissue from dead animals.

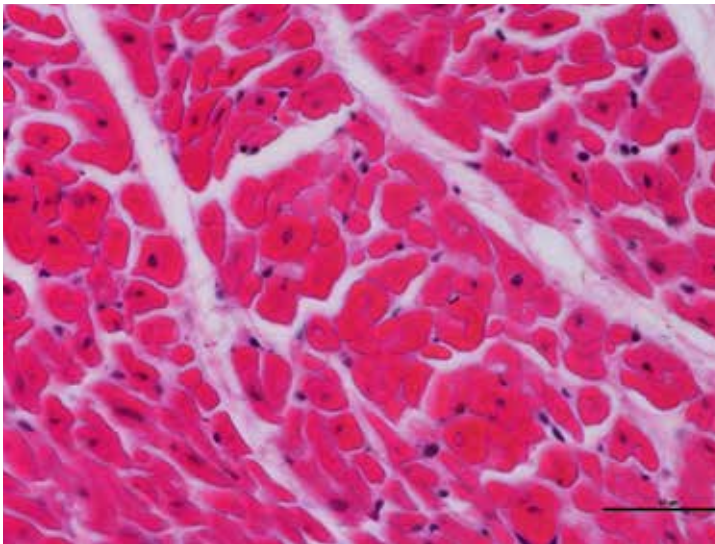




**Figure 1.5.15.**

Skeletal muscle showing degeneration and necrosis of muscle fibers in a lamb that died from heart failure due to nutritional myopathy. Similar lesions were noted in the myocardium. Trace mineral analysis of liver tissues revealed deficient levels of selenium. Growing lambs are more susceptible to sudden death from selenium deficiency. Selenium is an essential component of an important enzyme, glutathione peroxidase that plays a vital role in protecting cell membranes and preventing

damage and destruction of cells in different tissues and organs of the body. Lambs that survive are often down or have difficulty walking. They are very stiff and tremble; therefore, the disease is often referred to as “stiff lamb disease”. Affected older animals may have coffee-colored urine due to release of damaged muscle proteins into the urine. Other differentials for skeletal muscle damage include ionophore toxicity (monensin) and plant toxicities (*Senna* sp., Lupine (*Diaportha toxica*), water hemlock (*Cicuta douglasii*). Selenium toxicosis can also cause similar lesions in lambs that received a toxic dose of selenium by injection or feed.



**Figure 1.5.16.**

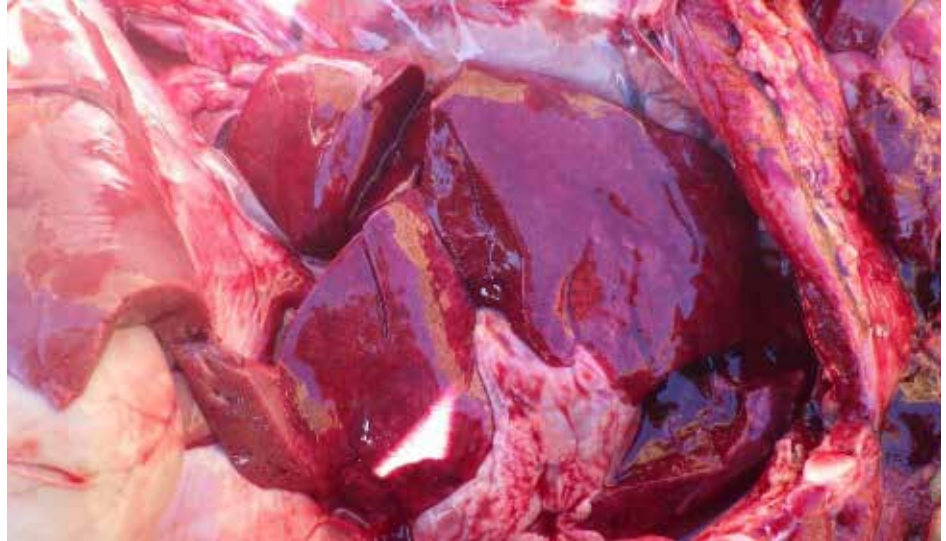Neonatal lamb: Heart muscle showing acute degeneration and necrosis. Deficient levels of selenium noted in the liver.



## 6. Left Side Heart Failure

**Figure 1.6.1.**

Pulmonary edema and congestion in a lamb that died due to left side heart failure.

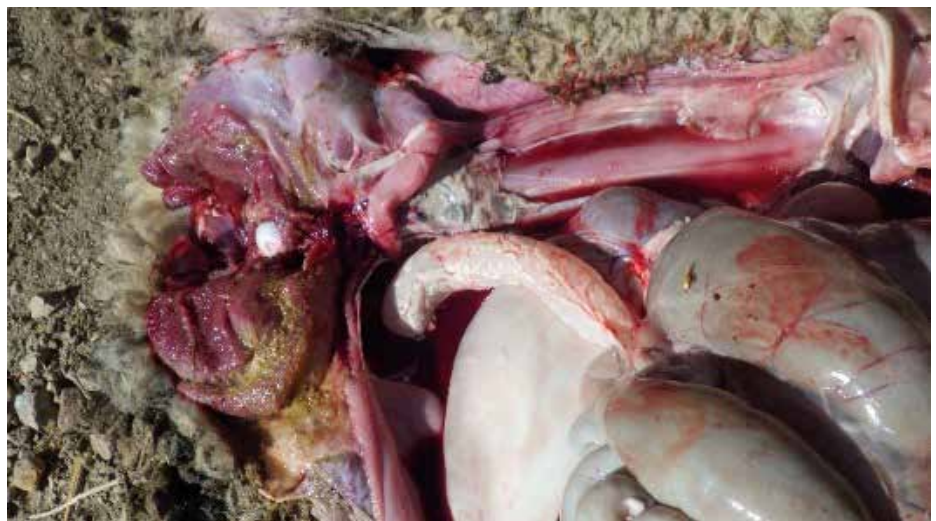

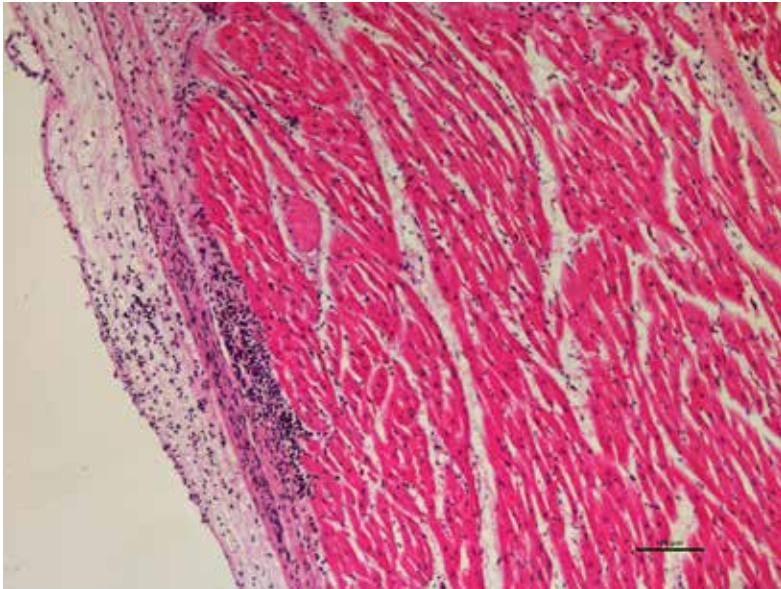
## 7. Pericarditis and Epicarditis

Pericarditis is rare in feedlot sheep. It can lead to secondary signs of congestive heart failure like pulmonary edema and a congested liver. Pericardial/epicardial inflammation can result in fluid or exudate accumulation in the pericardial sac. Some of the causes include haematogenous spread of bacterial infection (septicemia), extension of infection from the pleura, and trauma caused by penetration of ingested sharp foreign object (hardware disease).

**Figure 1.7.1.**

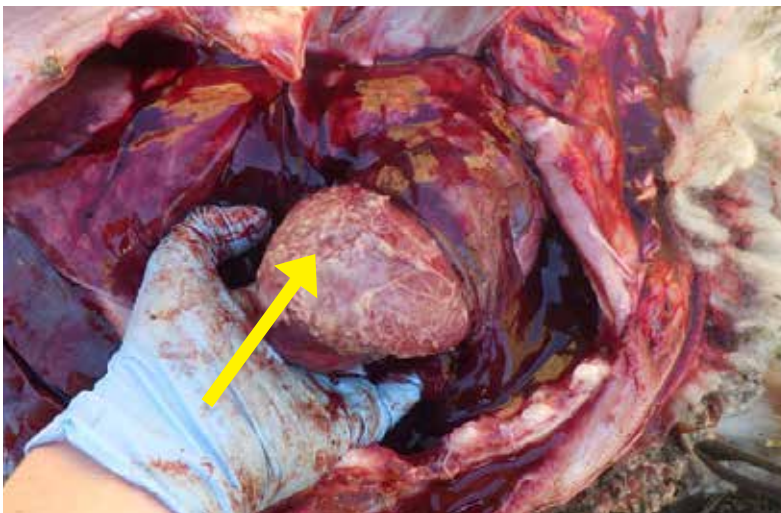
Thickened pericardial sac in a lamb that died due to hardware disease. This animal also had ascites (fluid accumulation in body).





**Figure 1.7.2.**

Epicardium is expanded and infiltrated with mixed inflammatory cells and edema.



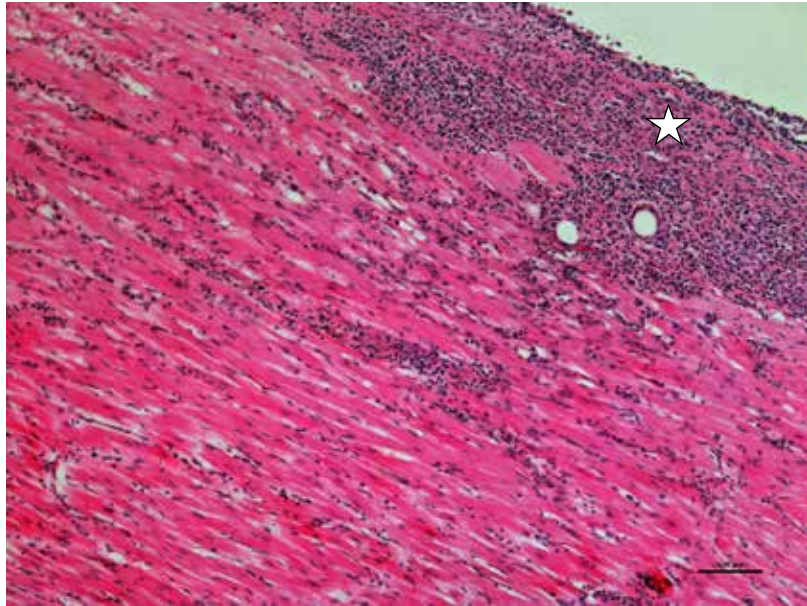
**Figure 1.7.3.**

Diffuse **pericarditis** and **epicarditis** in a lamb. Note the yellow fibrin on the surface of the heart.



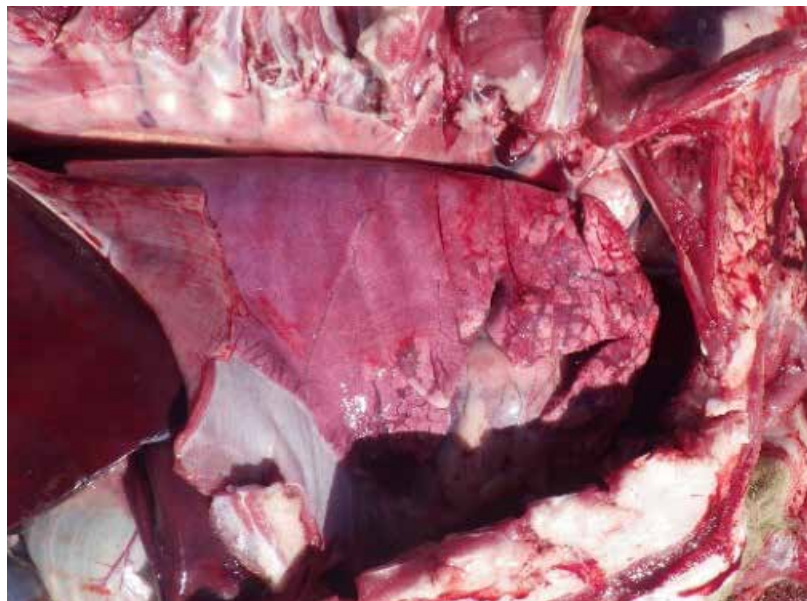
**Figure 1.7.4.**

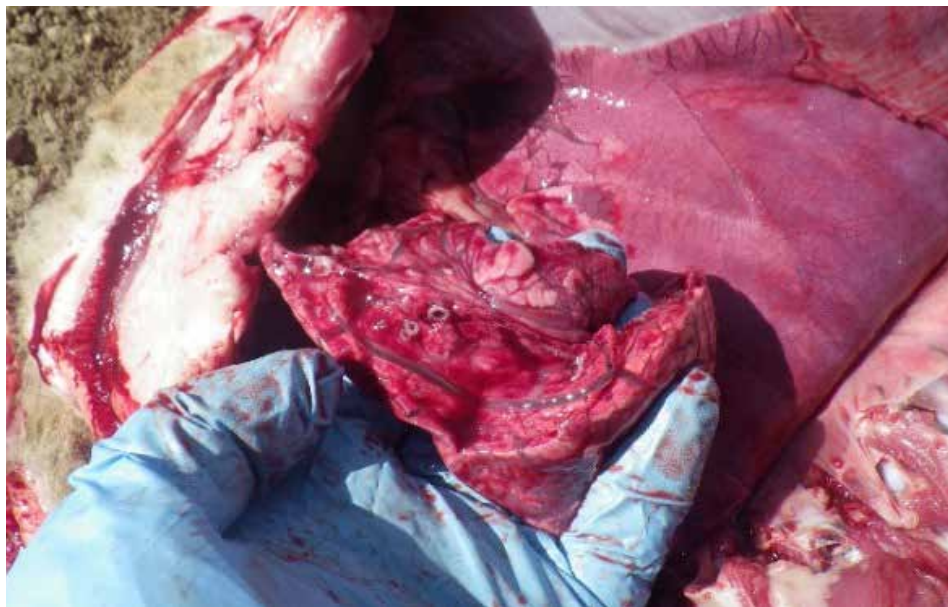Epicardium and adjacent myocardial interstitium is infiltrated with many mixed inflammatory cells.



**Figure 1.7.5.**

Lungs were enlarged (note rib impressions on surface), heavy and wet and failed to collapse.

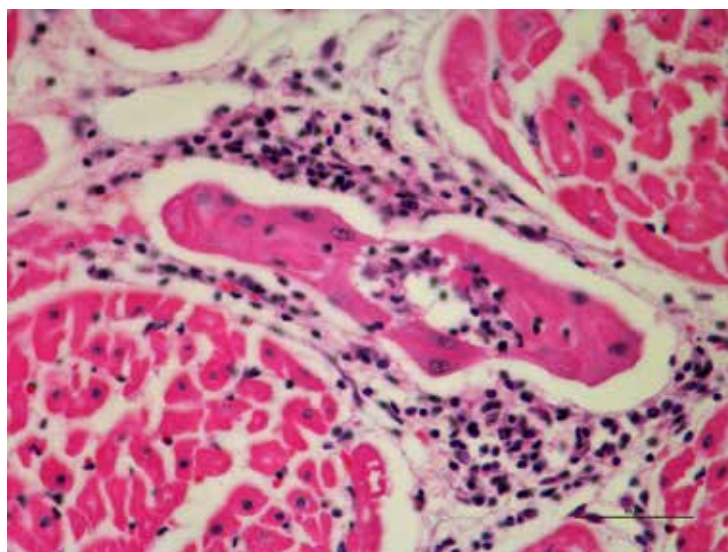




**Figure 1.7.6.**

Edematous wet lung with fluid oozing from cut surface. Airways are clear.

## 8. Interstitial Myocarditis



**Figure 1.8.1.**

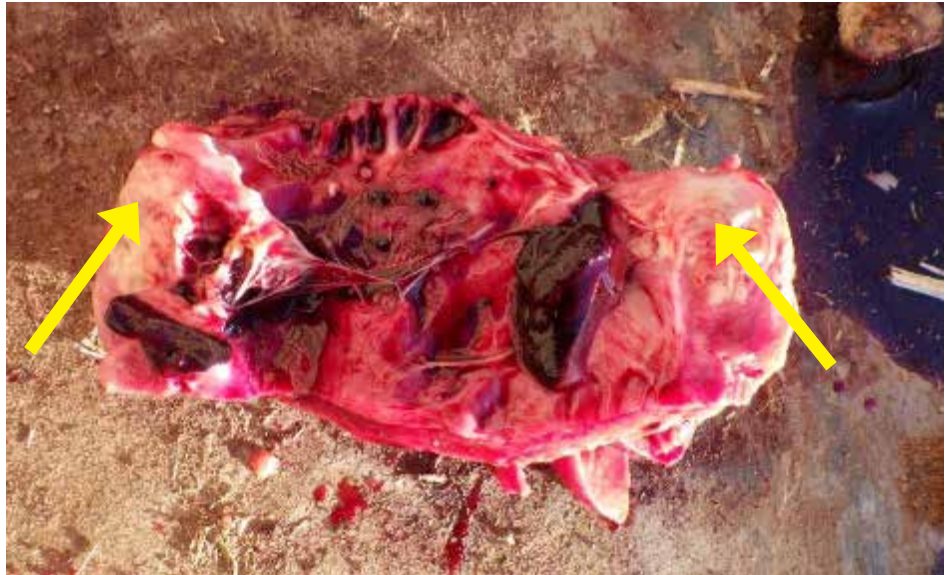Interstitial myocarditis with infiltration of mixed inflammatory cells extending to Purkinje fibers. Other lesions in this animal included portal hepatitis with pulmonary edema and congestion. This type of lesion is typically associated with bacterial septicemia. Pure culture of *E. coli* were isolated from the lung and liver.



## 9. Myocardial Abscessation

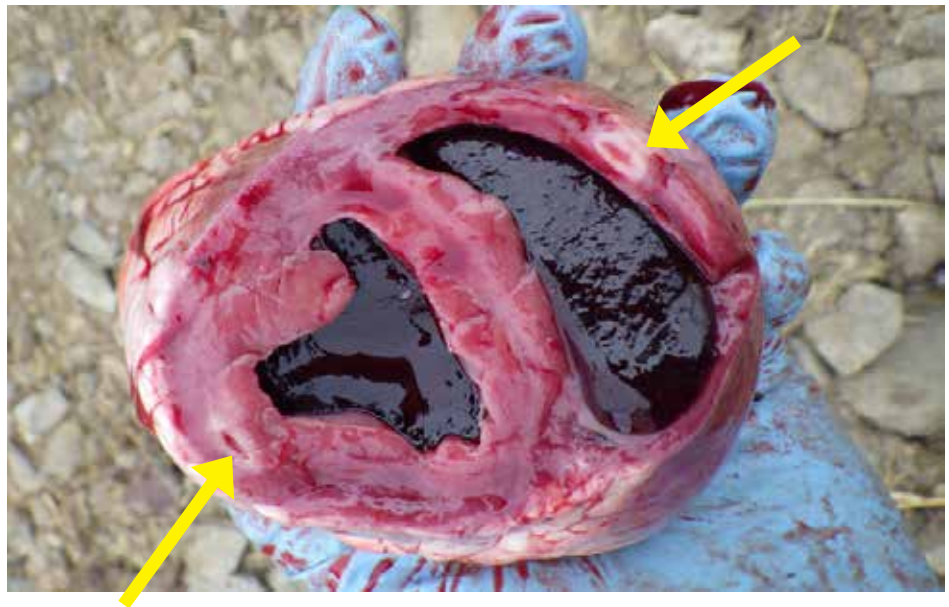
**Figure 1.9.1.**

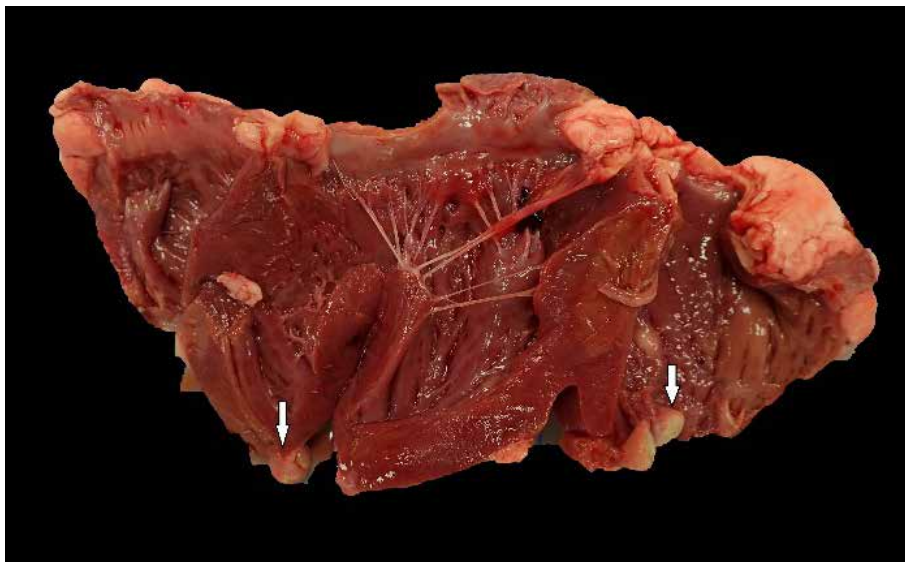
This animal had multifocal chronic myocardial abscessation with dilated ventricles and thickened ventricular walls.



**Figure 1.9.2.**

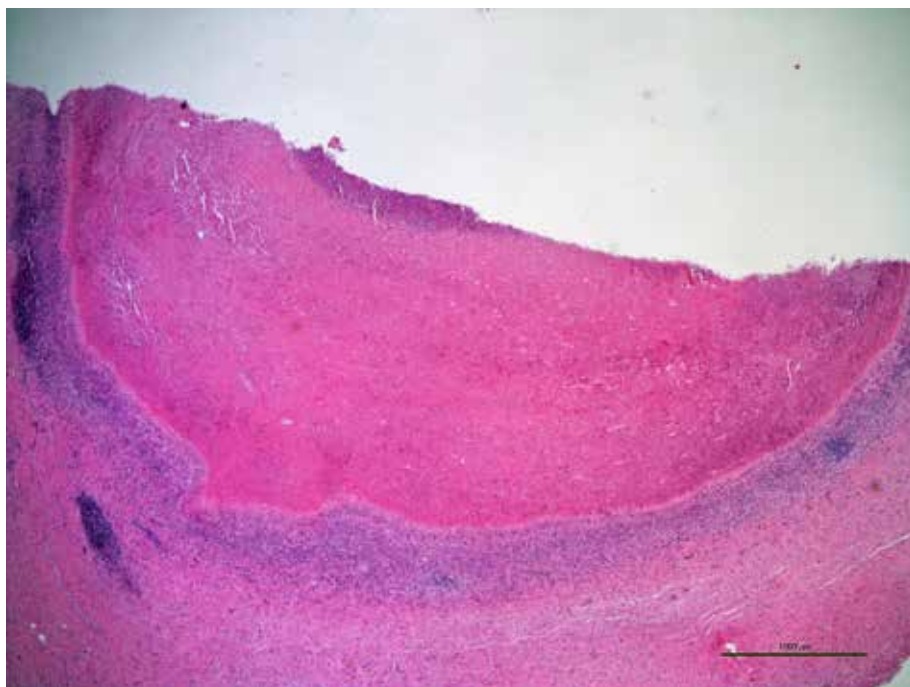
Multifocal chronic abscessation and thickened ventricular wall in a lamb.





**Figure 1.9.3.**

Multifocal chronic bacterial abscessation (arrows) in the heart of a lamb. Granulomatous lesions caused by tapeworm larvae migration are differentials for this type of lesions.



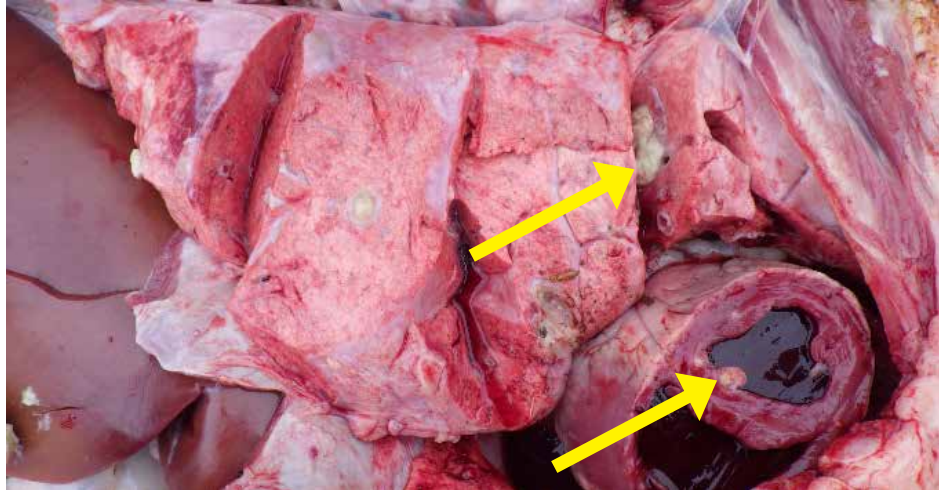
**Figure 1.9.4.**

Histologically, multifocal chronic abscessation (arrows) in the heart of lamb. No acid-fast positive bacteria seen in the tissues. The samples tested negative for *Mycobacterium* sp. by PCR testing. *Trueperella pyogenes*, *Staphylococcus* sp. and *Streptococcus* sp. are typically associated with abscessation.



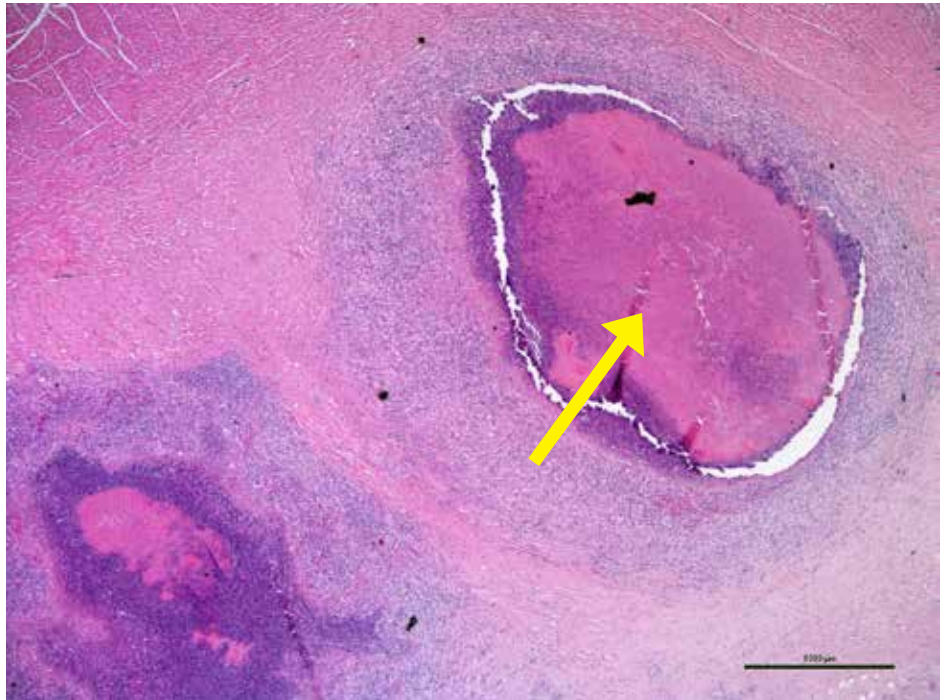**Figure 1.9.5.**

Grossly, abscesses observed in the heart muscle and in the lung.

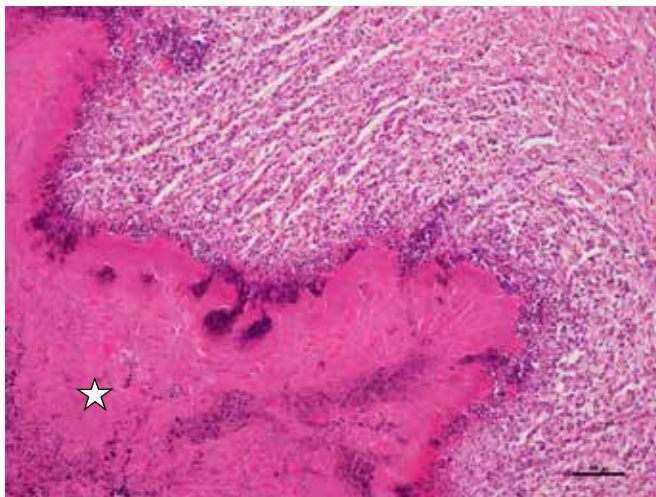


**Figure 1.9.6.**

Heart showing chronic suppurative abscessation and bacterial colonies.



## 10. Necrotizing Myocarditis



**Figure 1.10.1.**

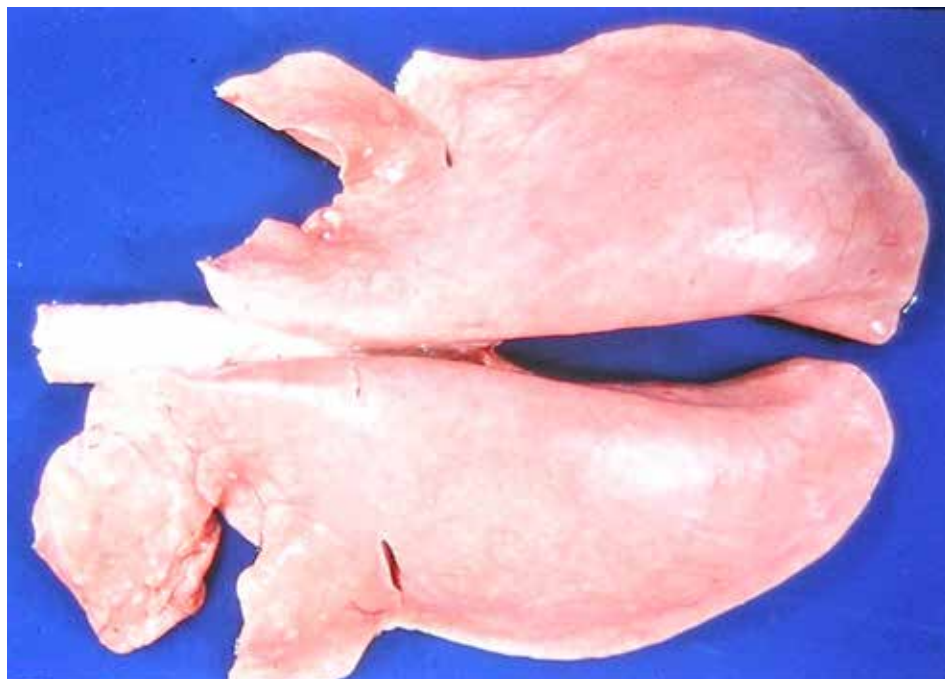
Myocardium contains several extensive areas of coagulative necrosis bordered by an irregular dark blue band of inflammatory cellular debris. Chronic bronchopneumonia with abscessation of lungs was also noted in this animal. *T. pyogenes* was isolated from lungs. Marginal liver levels of cobalt and vitamin E were found. Similar histological lesions can be rarely seen in lambs that die of *Clostridium* sp. (*Cl. chauvoei* and *Cl. septicum*) infections.

## II. DISEASES OF THE RESPIRATORY SYSTEM

1. Fibrinous Bronchopneumonia.....	31
2. Suppurative Bronchopneumonia.....	34
3. Chronic Bronchopneumonia .....	46
4. Pleuritis .....	59
5. Embolic Pneumonia .....	60
6. Interstitial Pneumonia .....	73
7. Verminous Pneumonia .....	76
8. Chronic Bronchitis/Bronchiolitis.....	78
9. Aspiration Pneumonia.....	80
10. Necrotic Laryngitis .....	82
11. Pulmonary Abscessation .....	84
12. Nasal adenocarcinoma .....	85
13. Ovine Progressive Pneumonia (OPP).....	87
14. Nose Bleed .....	89
15. Caseous Lymphadenitis .....	90

## II. DISEASES OF THE RESPIRATORY SYSTEM

Signs of respiratory disease in sheep are similar to cattle. Lambs may be isolated from the herd, have a dull demeanor, cough, and have mucus around their nose, and have an empty flank since they haven't been eating.



Normal lungs from a healthy sheep.

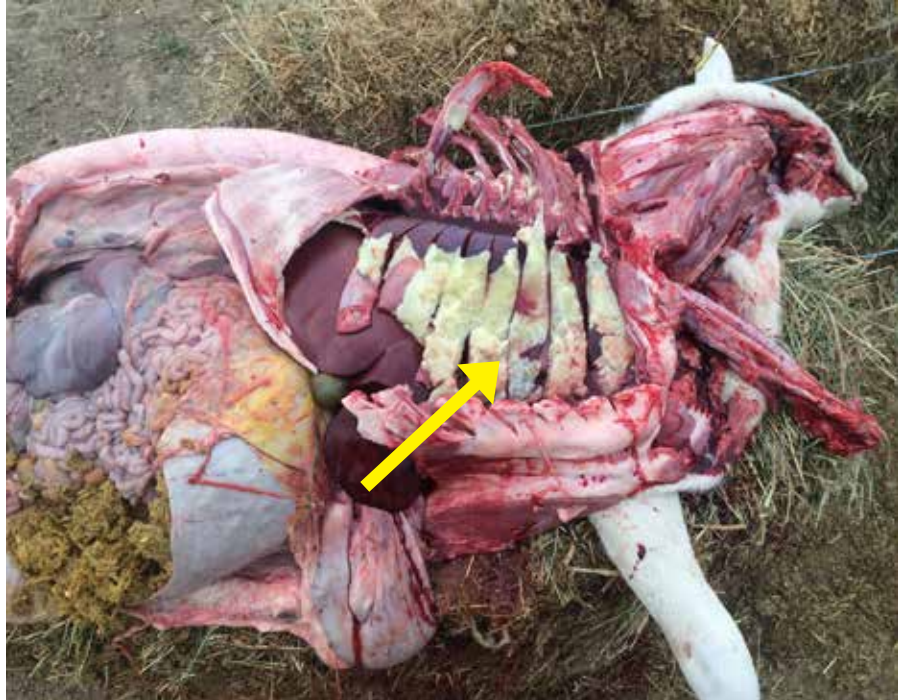


## 2.1. Fibrinous Bronchopneumonia

**Figure 2.1.1.**

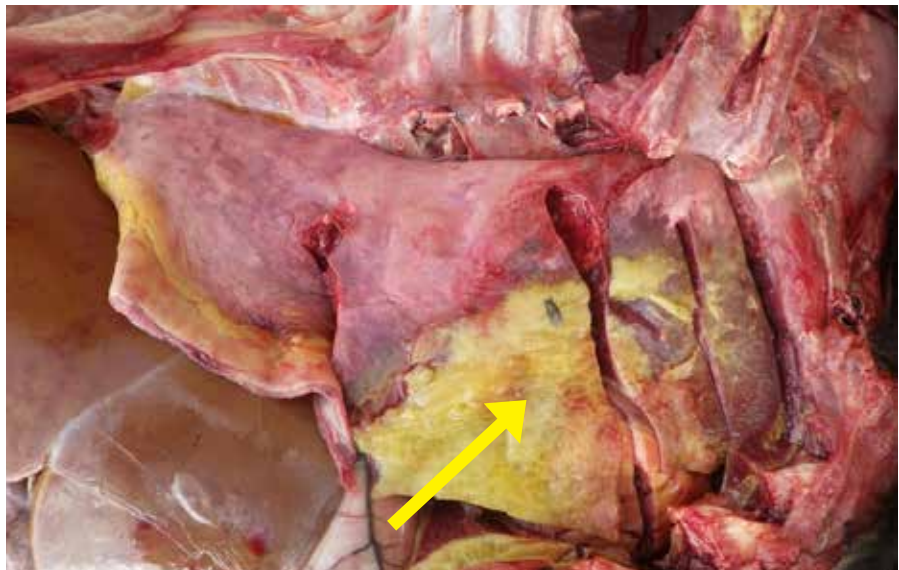
Lung from a lamb that died from fibrinous bronchopneumonia, showing pleural surface covered with yellow fibrin (inflammatory protein exudate). The lung underneath is dark red and consolidated (firm to touch).

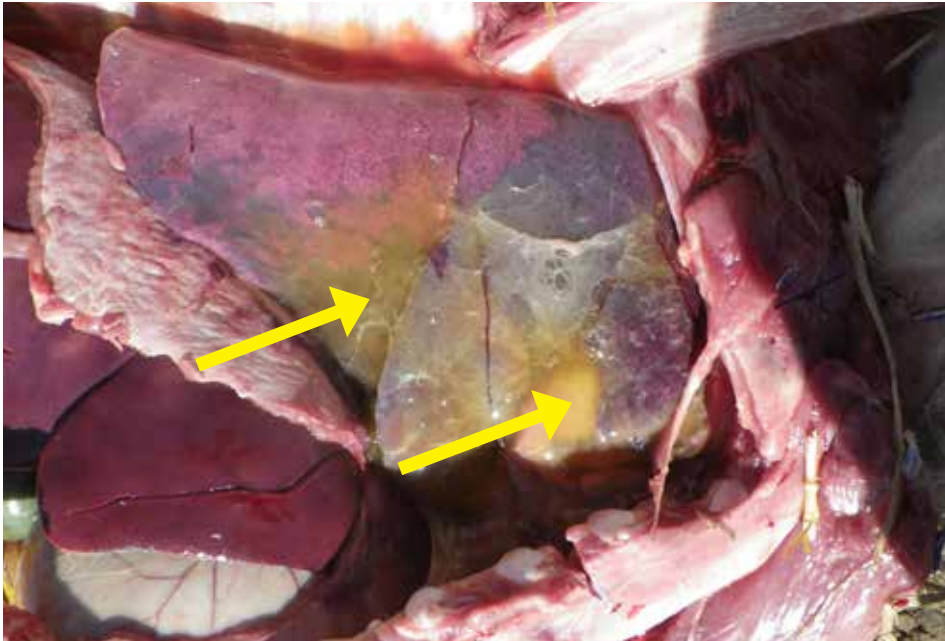
*Mannheimia haemolytica* bacteria is typically isolated from lungs with these types of lesions.



**Figure 2.1.2.**

Fibrinous bronchopneumonia in a lamb showing yellow fibrin on surface of lung lobe (arrow) and the affected anterior-ventral lung lobes are consolidated and dark red.





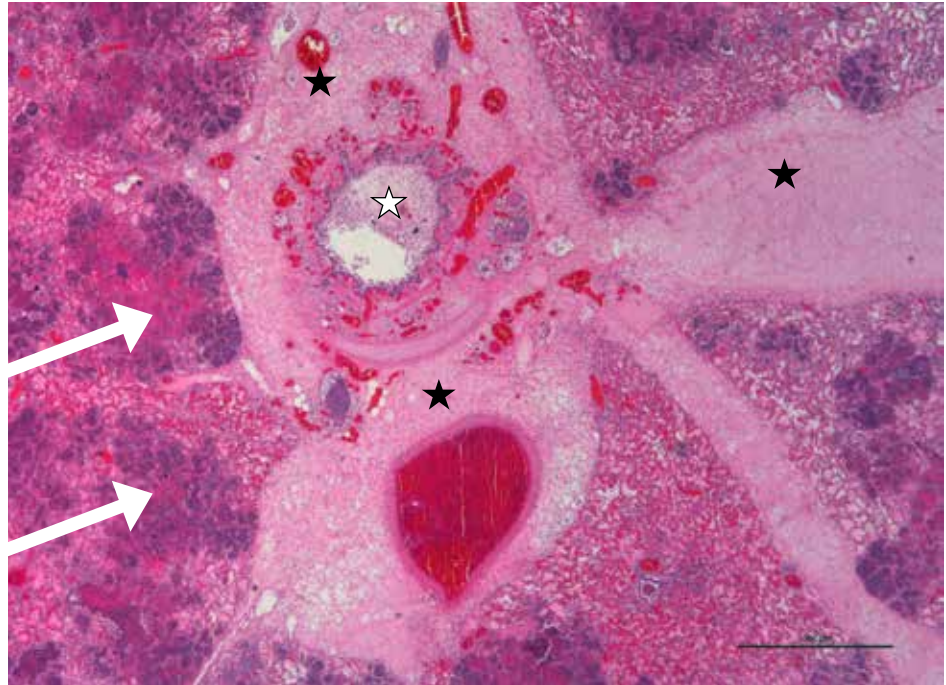
**Figure 2.1.3.**

Early fibrinous pneumonia in a lamb with yellow fibrin matted on the surface of the lung's anterior-ventral lobes (arrows) with dark discoloration of the lung lobes.

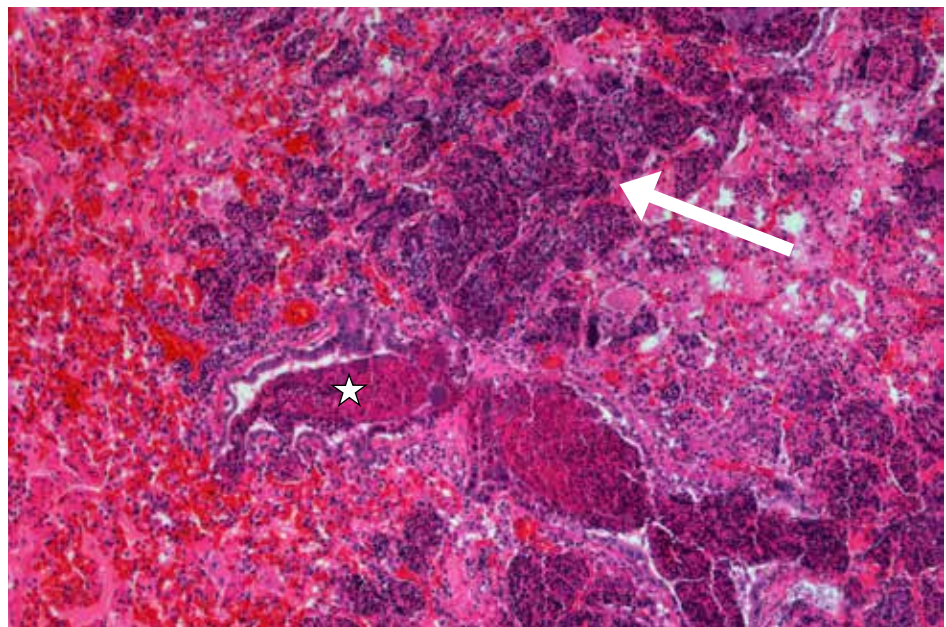


**Figure 2.1.4.**

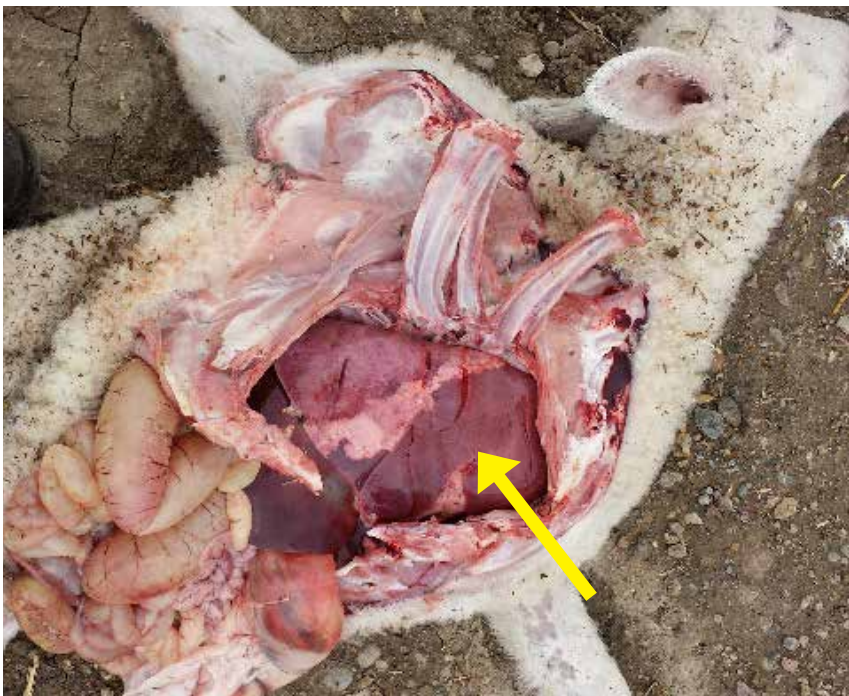Fibrinous bronchopneumonia in lungs of a lamb showing expanded interlobular septae, around airway and perivascular spaces with serofibrinous exudate (dark stars). Bronchi are filled with exudate (white star) Extensively, alveoli are filled with necrotic leukocytes cells (white arrows) and fibrinohemorrhagic exudate. These degenerating leukocytes often have streaming nuclear chromatin (oat-cells) typical of *Mannheimia haemolytica* infection.

**Figure 2.1.5.**

High power view of same lung with fibrinous bronchopneumonia showing small airways (bronchioles, white star) and alveoli (white arrow) filled with large numbers of necrotic streaming leukocytes (oat-cells) admixed with bacterial colonies, serofibrinous exudate and hemorrhage. *Mannheimia haemolytica* was isolated from bacterial culture of lung tissues. Microscopic finding of oat-cells in alveoli is of pneumonic lungs is typical of *Mannheimia haemolytica* infection.

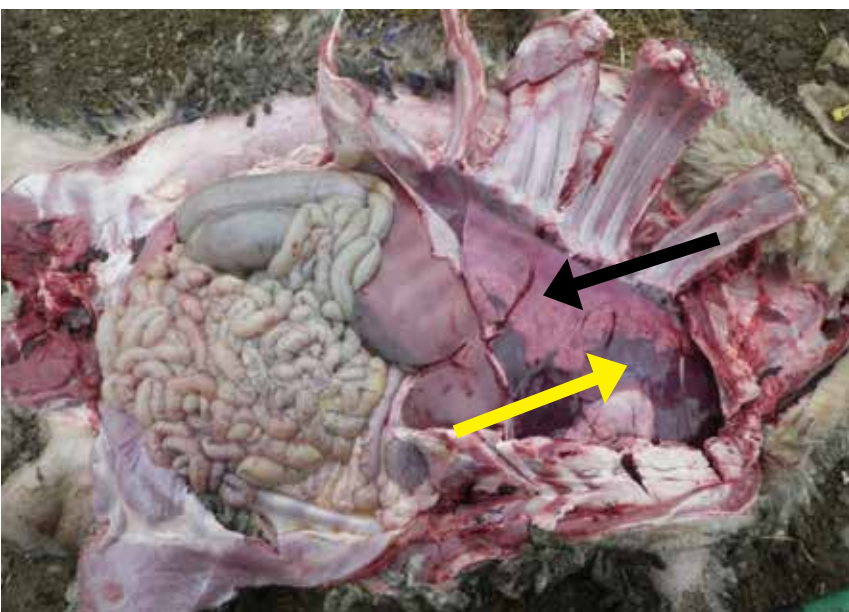


## 2.2. Suppurative Bronchopneumonia



**Figure 2.2.1.**

Anterior-ventral lobes dark red and consolidated with bronchopneumonia.



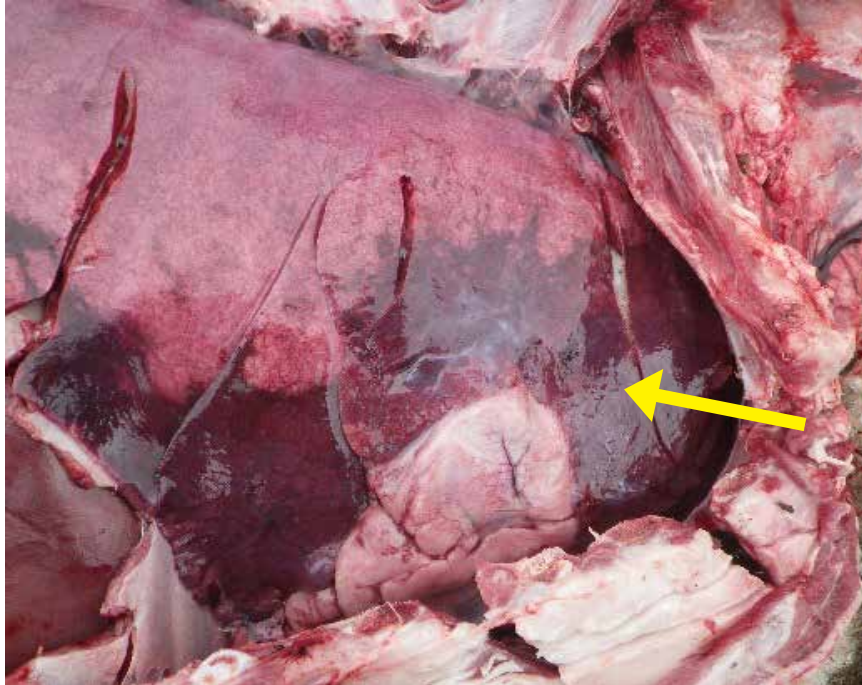
**Figure 2.2.2.**

Anterior-ventral lobes are dark red and consolidation with bronchopneumonia (yellow arrow). Normal pink spongy lung above as shown by black arrow.



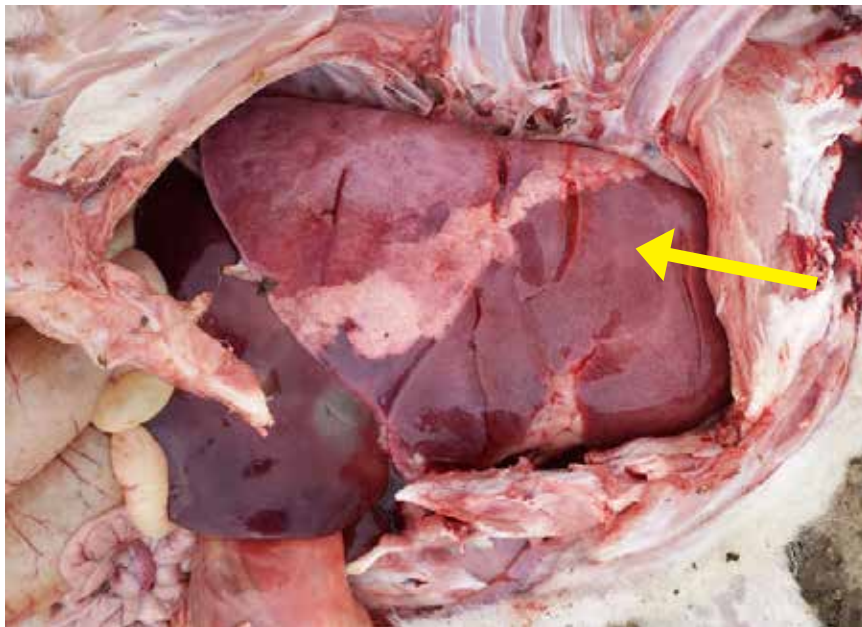
**Figure 2.2.3.**

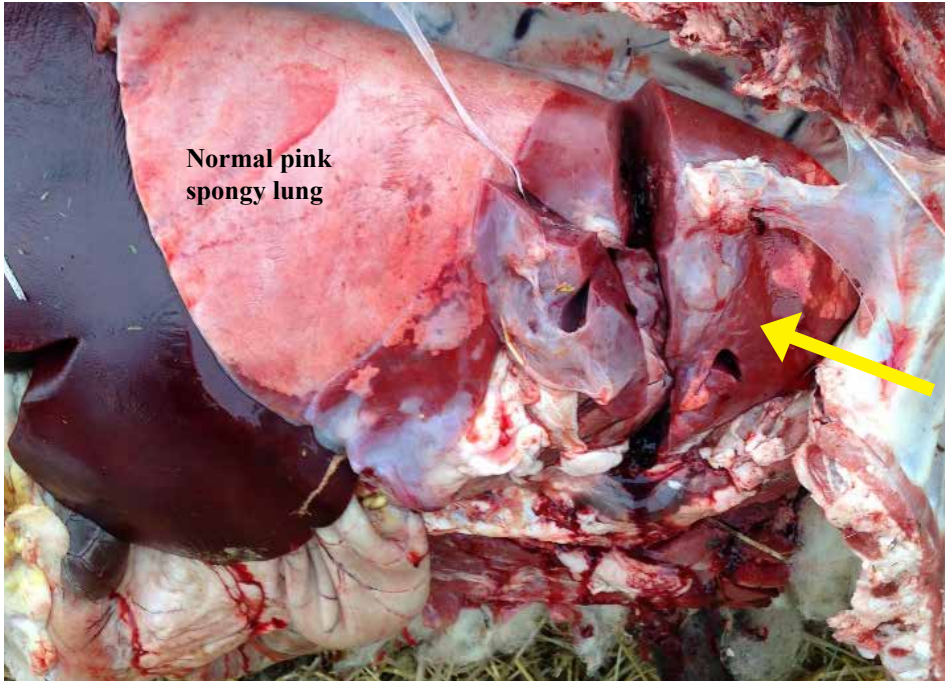
Moderate, acute broncho-pneumonia in a lamb showing (dark red, consolidated anterior-ventral lung lobes.



**Figure 2.2.4.**

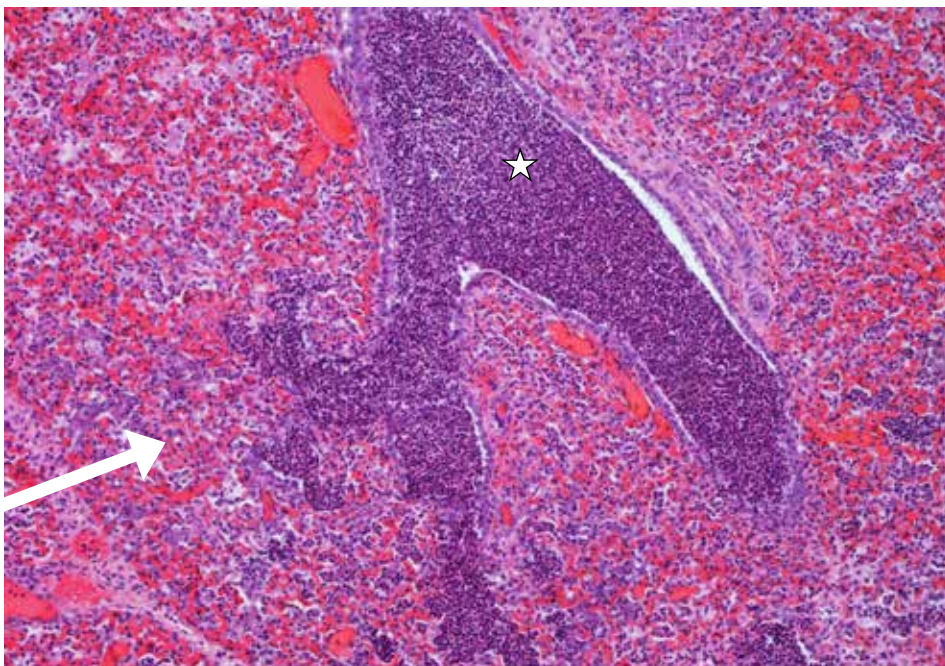
Severe, acute broncho-pneumonia in a lamb showing consolidated, dark-red anterior-ventral lung lobes.





**Figure 2.2.5.**

Dark red, consolidated anterior-ventral lung lobes from a lamb died due to severe, acute bronchopneumonia.



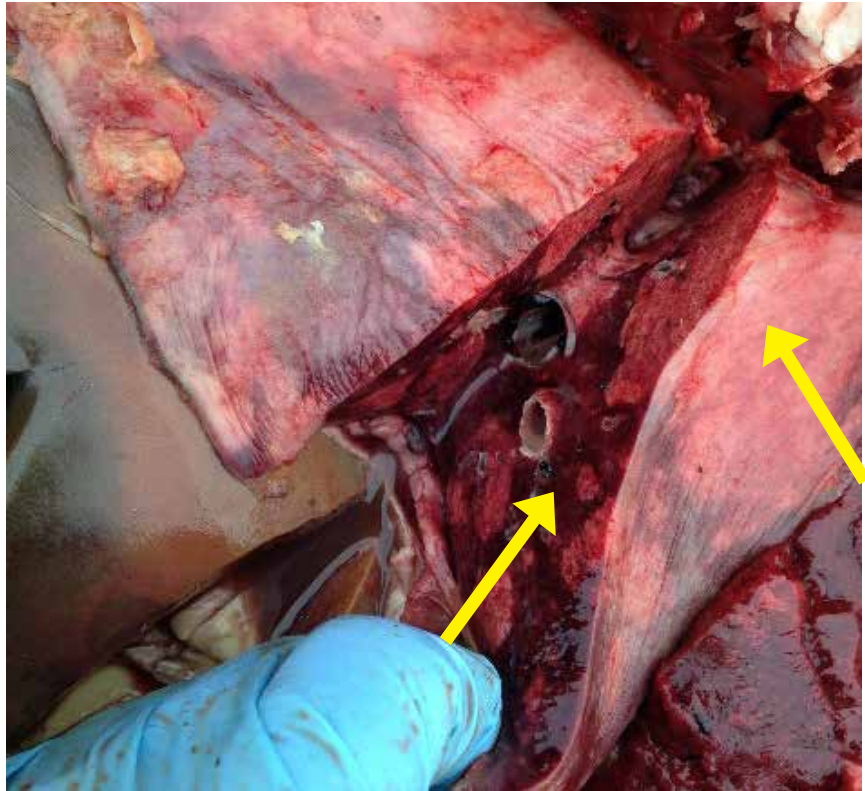
**Figure 2.2.6.**

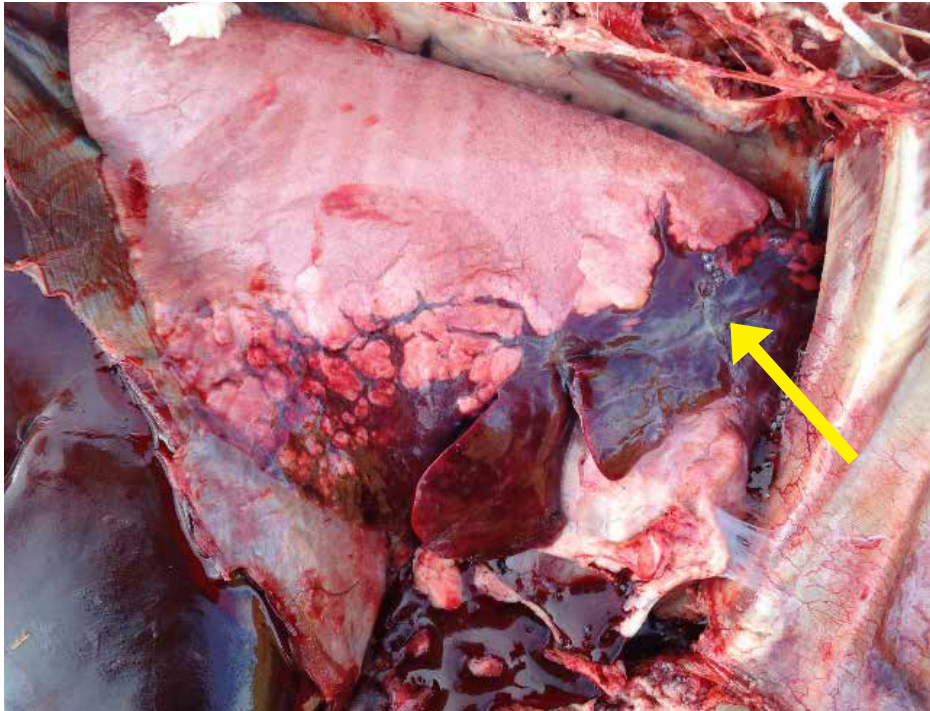
Suppurative bronchopneumonia in lungs of a lamb showing congestion and multifocal hemorrhages with large numbers of neutrophils filling the small airways (bronchioles, white star) and adjacent alveoli (white arrow). *Pasteurella multocida* isolated from bacterial culture of lung tissues.



**Figure 2.2.7.**

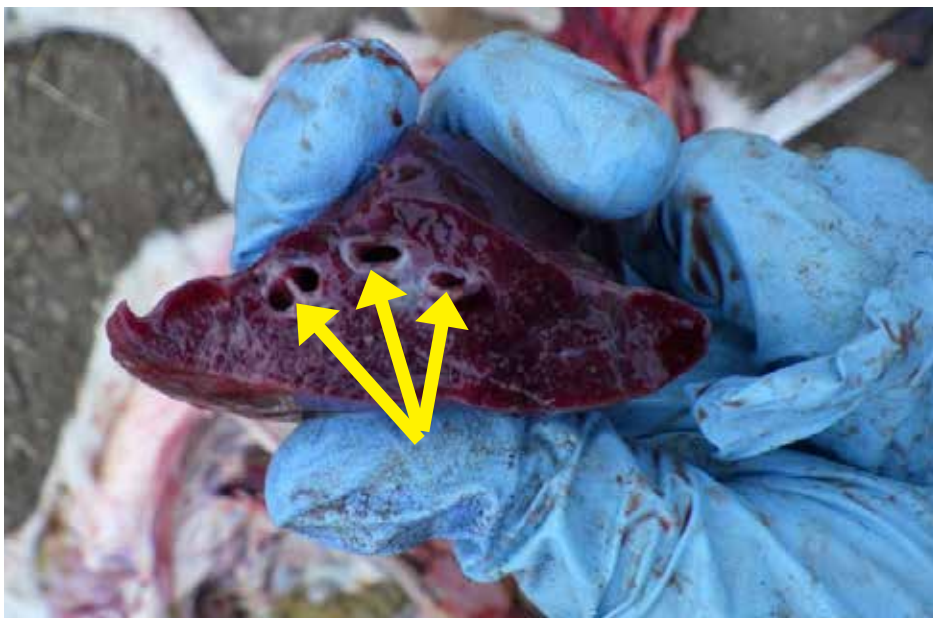
Cross section shows dark red (congested) lobes with bronchopneumonia and normal pale salmon color lobes.





**Figure 2.2.8.**

Dark red consolidated antero-ventral lobes of lung with acute bronchopneumonia.



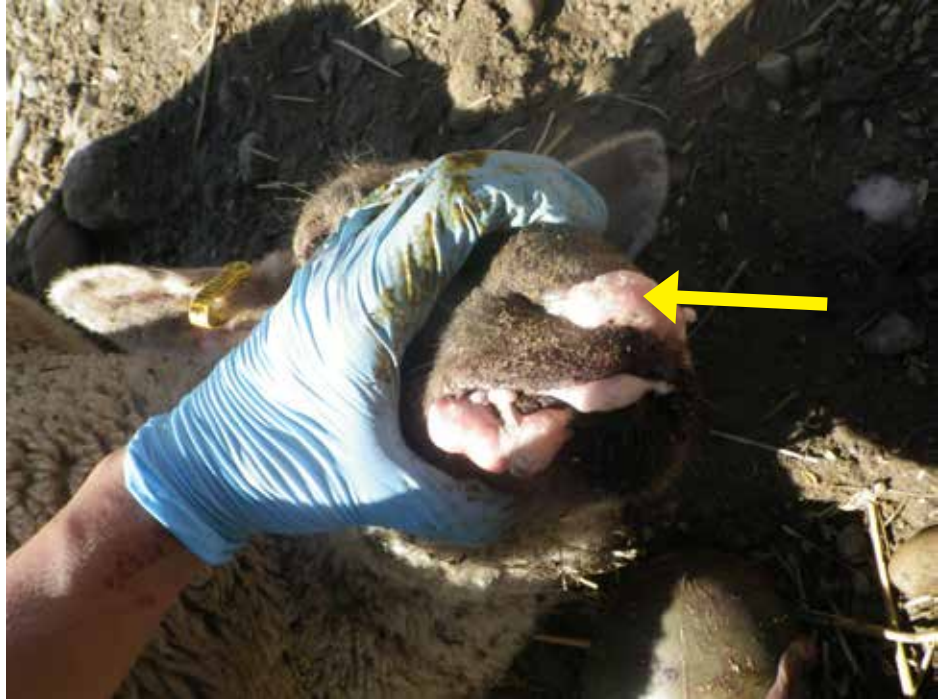**Figure 2.2.9.**

Dark red consolidated AV lobe on cross section. In bronchopneumonia a purulent exudate can often be squeezed out from airways (arrows) of the lung.



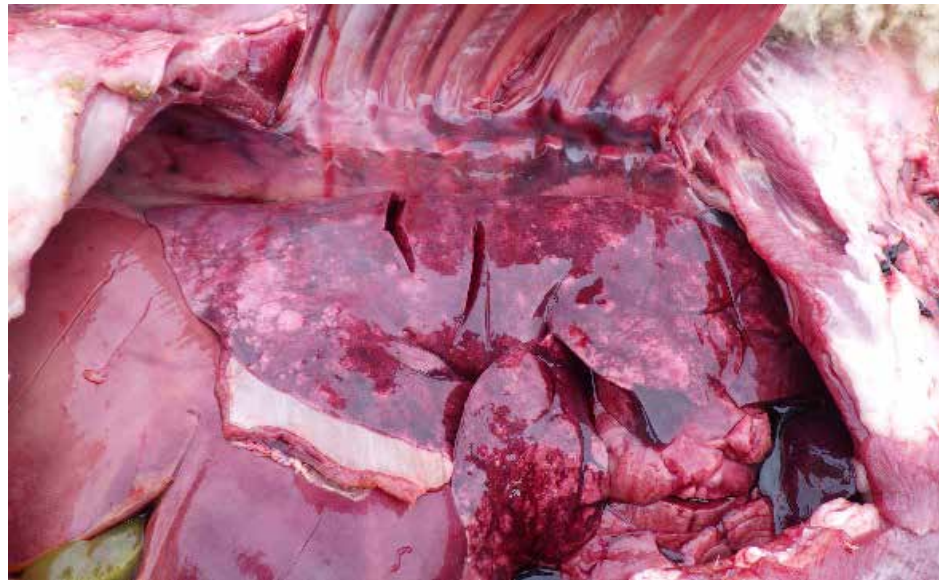**Figure 2.2.10.**

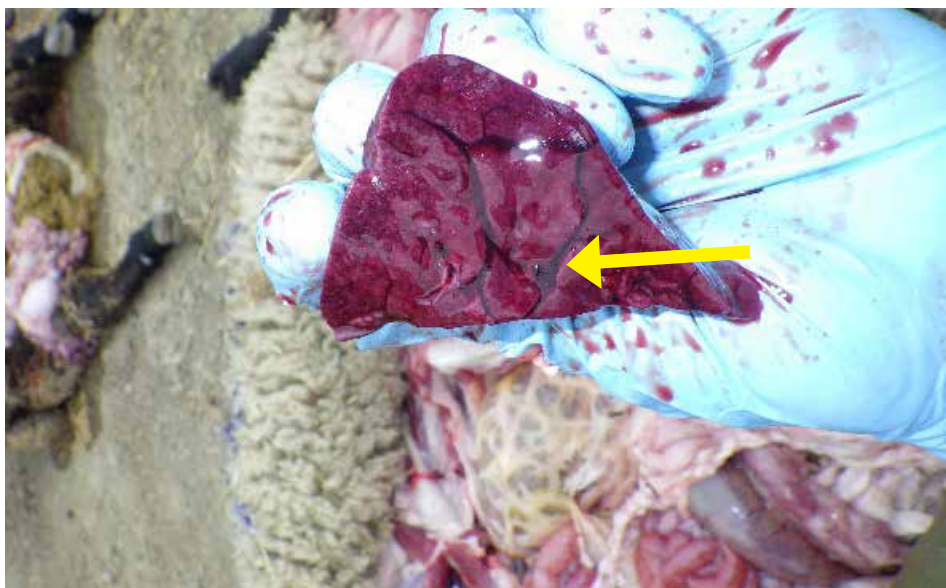
Lamb died due to bacterial septicemia showing foam from nose and mouth typical of pulmonary edema (fluid in the lungs).



**Figure 2.2.11.**

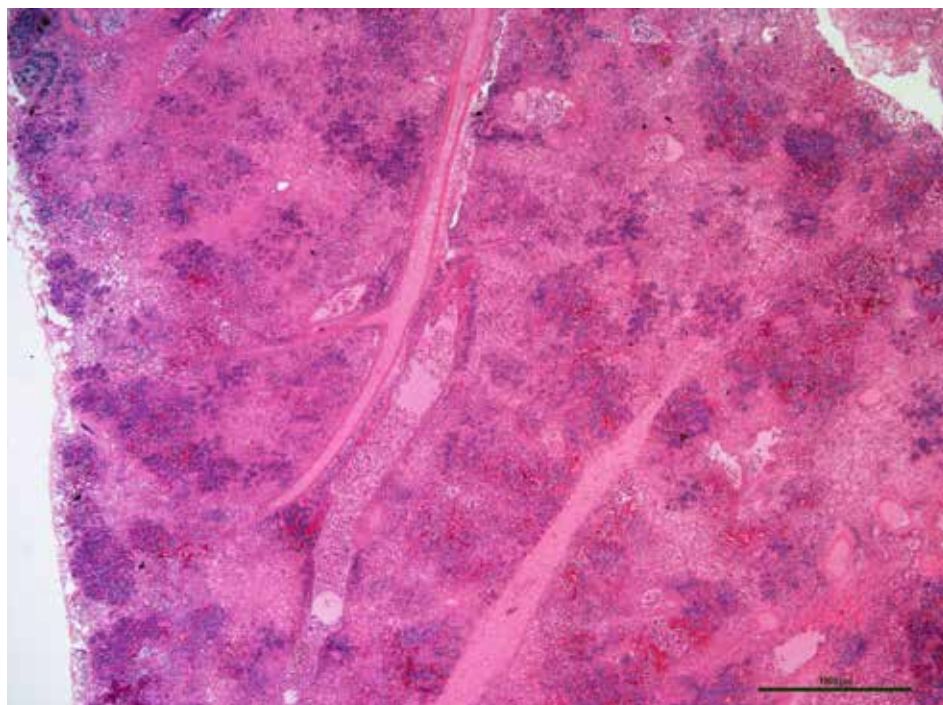
In cases of pulmonary edema, grossly, lung lobes will fail to collapse, congested (red), and wet and heavy (edematous).





**Figure 2.2.12.**

Lobules of lung are separate by clear edematous fluid in pulmonary edema.



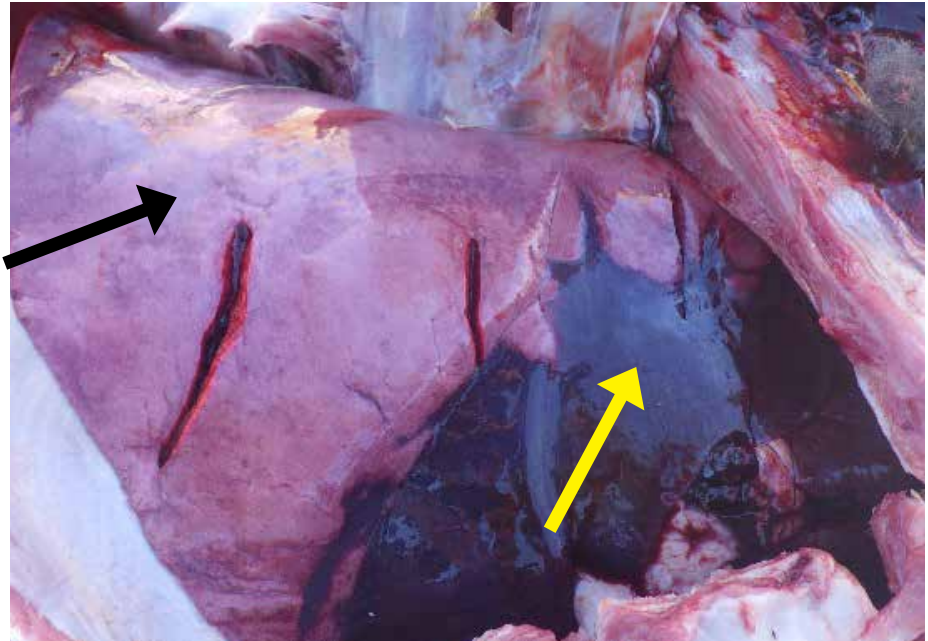
**Figure 2.2.13.**

Histologically, severe hemorrhagic and necrotizing bronchopneumonia with severe edema was noted in this lamb. Pure culture of *E. coli* was isolated from lung tissues. *Mycoplasma arginini* was also detected by PCR and sequencing from this lung.



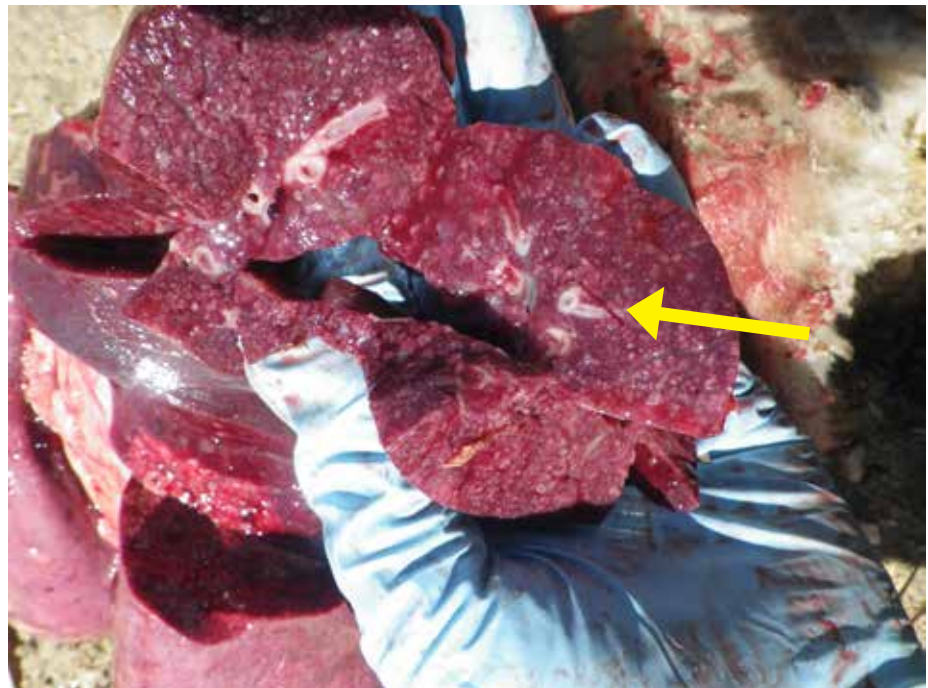**Figure 2.2.14.**

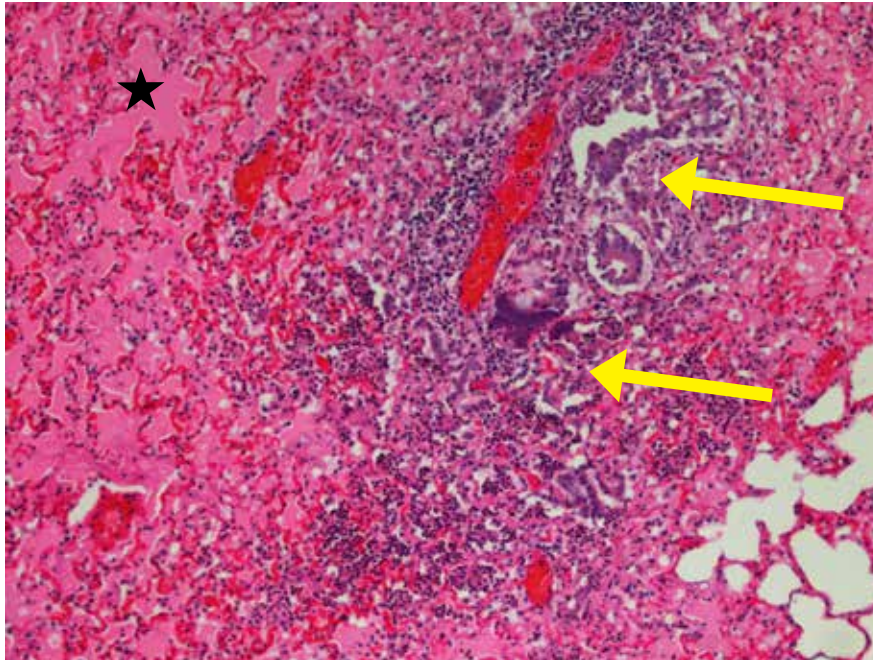
Suppurative bronchopneumonia in a lamb. Anterior-ventral lobes (yellow arrow) were dark red and consolidated while caudo-dorsal lobes (dark arrow) failed to collapse.



**Figure 2.2.15.**

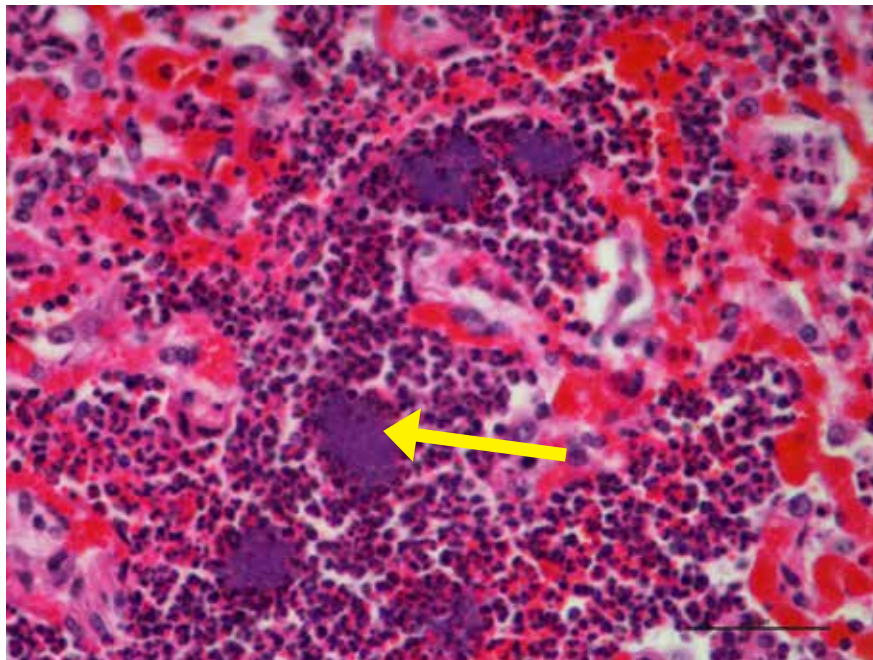
Cross-section of antero-ventral lobes of lung showing small circular white areas (pus filled) of bronchi/bronchiole, typically observed in suppurative bronchopneumonia.





**Figure 2.2.16.**

Lung from a lamb that died due to acute suppurative bronchopneumonia showing edema in the alveoli (solid star) and neutrophils in and around bronchioles (arrows) with spillover to adjacent alveoli.



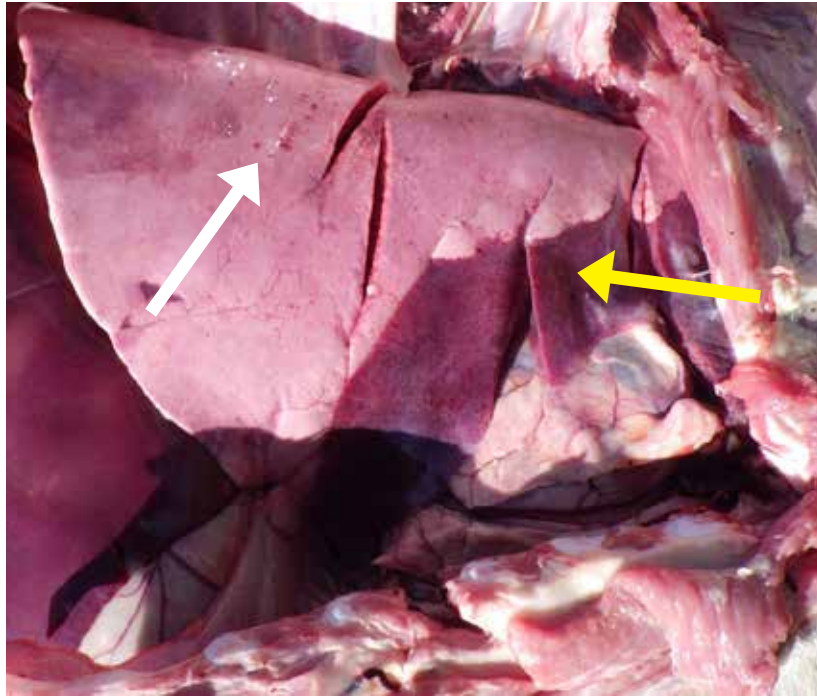
**Figure 2.2.17.**

High power view of same lung showing intra-lesional bacterial colonies (arrows) surrounded by neutrophils and congested alveoli. *Pasteurella multocida* was isolated from lungs.

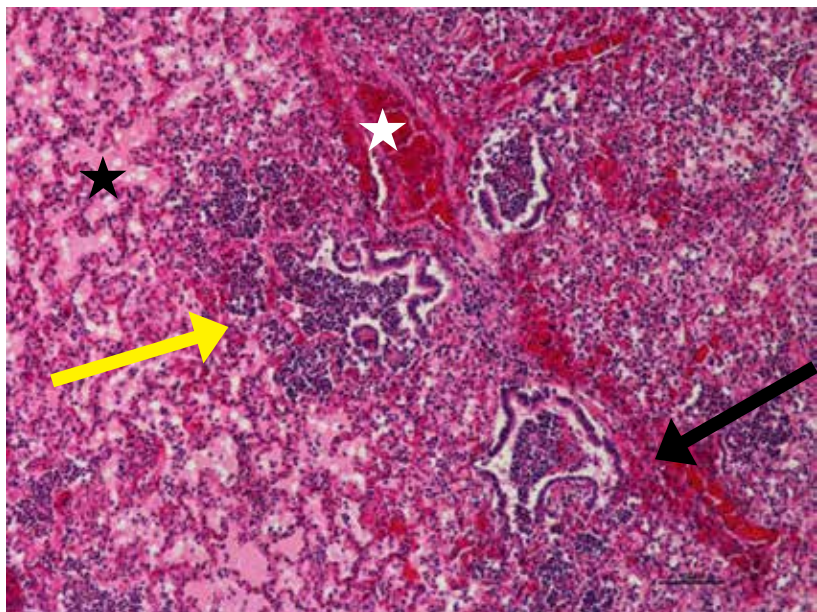


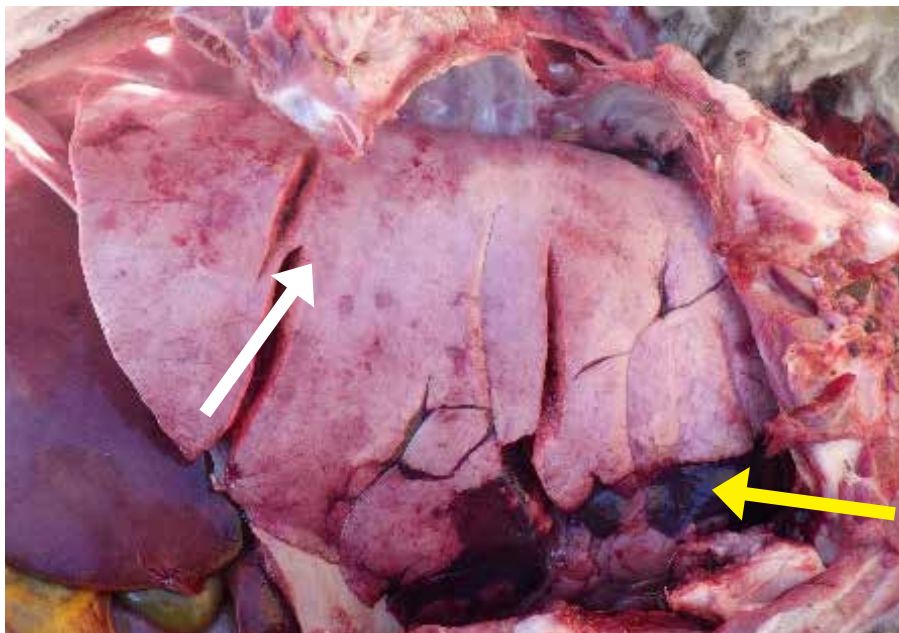
**Figure 2.2.18.**

Suppurative bronchopneumonia in lamb with un-collapsed lung (rounded edges of caudal lung lobes) with small petechial hemorrhages on surface and a few red collapsed areas (white arrow). Cranio-ventral lung lobes are dark red and consolidated (yellow arrow).

**Figure 2.2.19.**

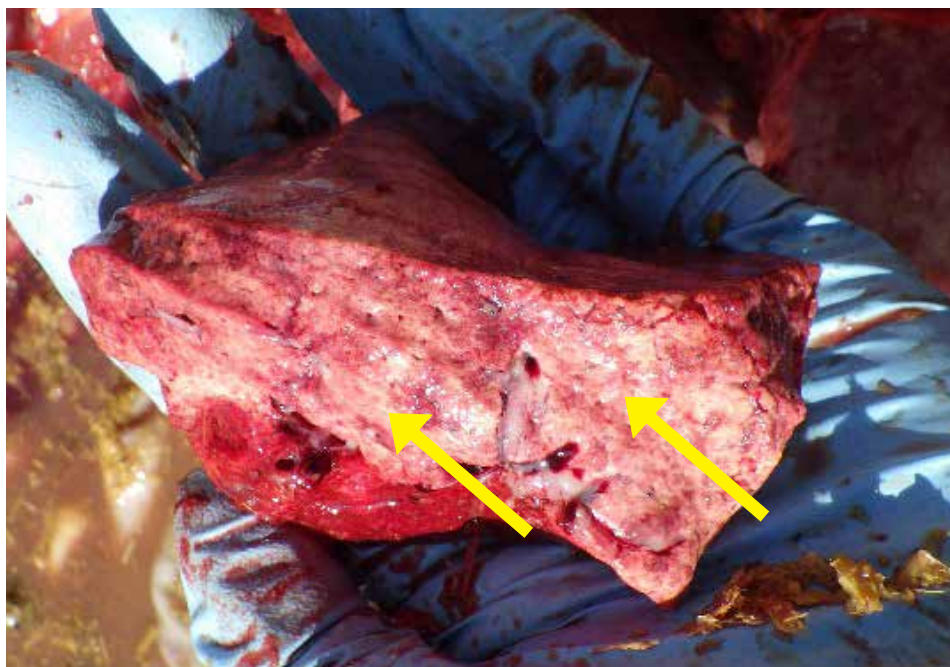Lung showing acute bronchopneumonia in a lamb. Neutrophils filling the dilated bronchioles (black arrow) and adjacent alveoli (yellow arrow), and perivascular hemorrhages (white star). *Histophilus somni* and *Pasteurella multocida* were isolated from this lung. Alveoli are filled with edema (black star) and neutrophils.





**Figure 2.2.20.**

Lung failed to collapse with small petechial dark red (hemorrhage) areas (white arrow) distributed throughout and cranio-ventral lobes are dark red and consolidated (yellow arrow).



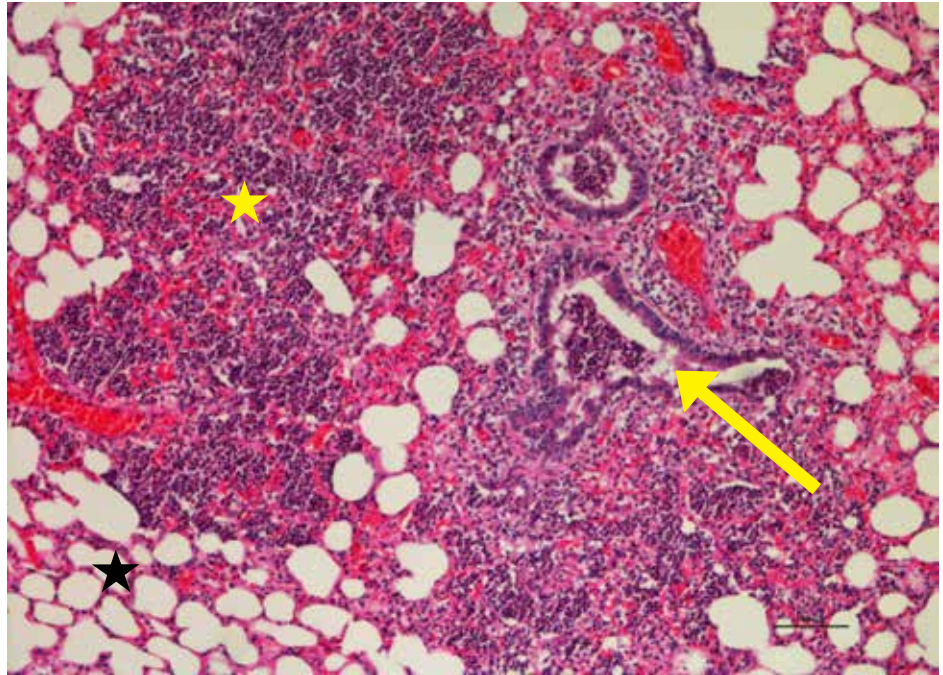
**Figure 2.2.21.**

Lung showing petechial hemorrhages (speckled dark red areas, star) and foam (proteinaceous edema, arrow) in airways.

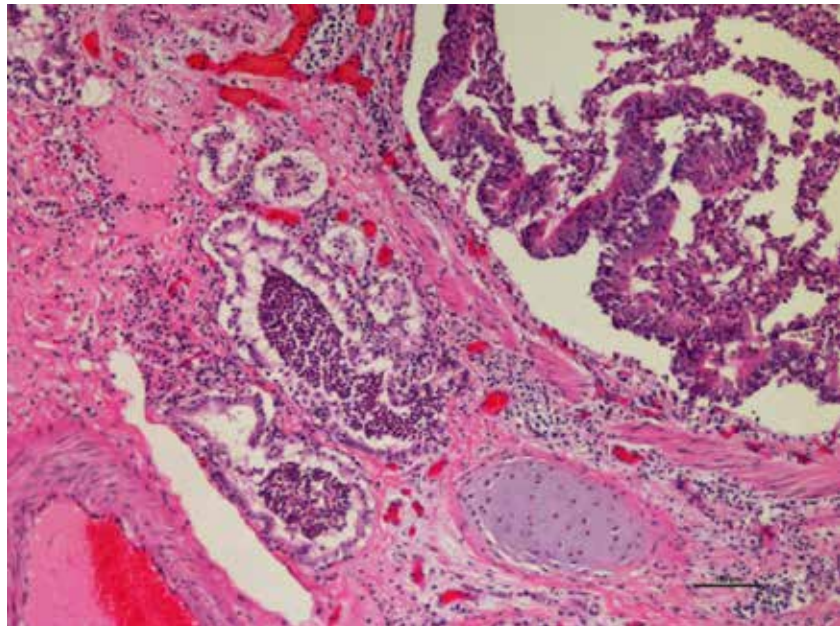


**Figure 2.2.22.**

Acute suppurative bronchopneumonia in lamb. Alveoli (yellow star) with bronchioles (white arrow) are filled with neutrophils. Dilated alveoli can be seen (black star) in adjacent areas.

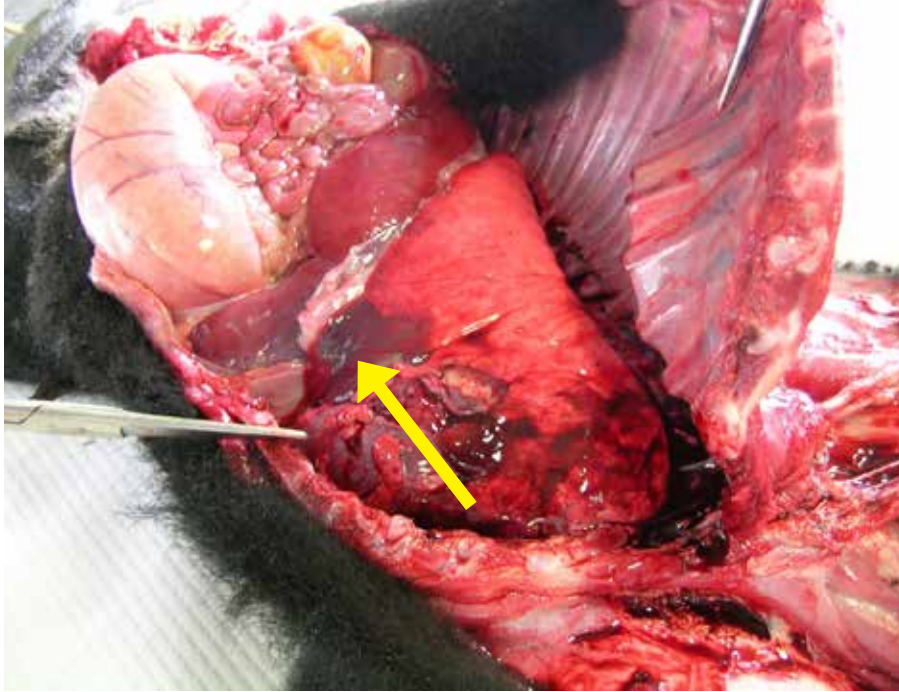
**Figure 2.2.23.**

High power view of lung from the same lamb showing bronchi. Activated submucosal glands are filled with large numbers of neutrophils which is a common lesion seen in *Mycoplasma arginini* associated bronchopneumonia. *Mannheimia haemolytica* was cultured from the lung tissue and tested positive for *Mycoplasma arginine* by PCR and sequencing. Other lesions observed in this lamb include hepatic centrilobular degeneration (lipid type) caused by hypoxemia resulting from severe pneumonia.



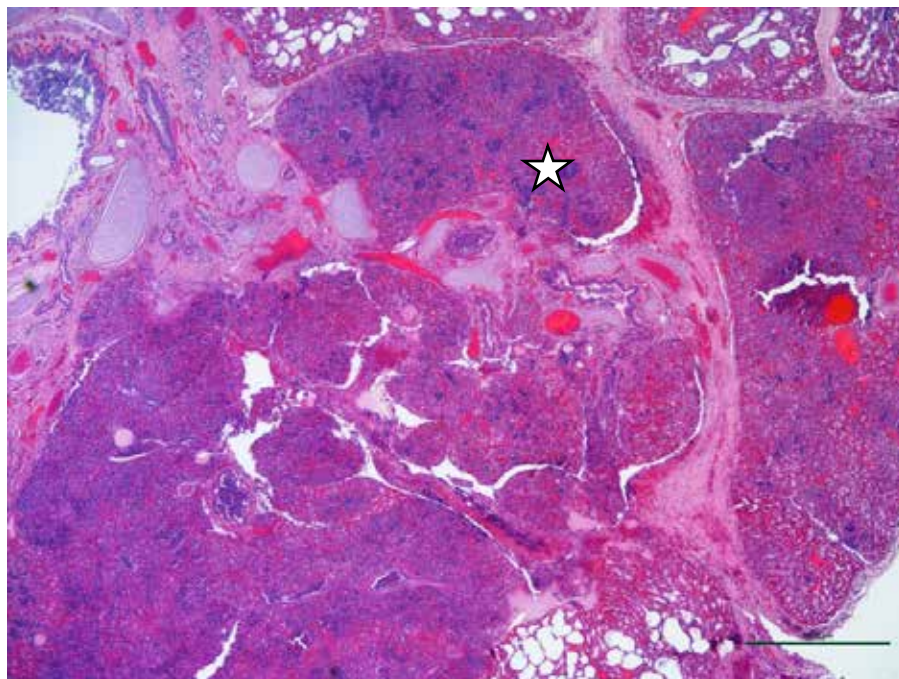


### 2.3. Chronic Bronchopneumonia



**Figure 2.3.1.**

Cranio-ventral consolidation in an older lamb died due to bronchopneumonia.



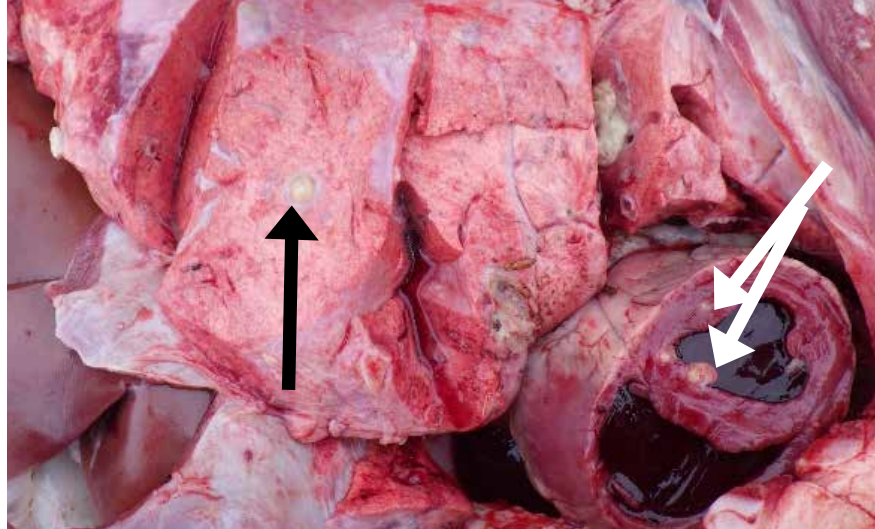
**Figure 2.3.2.**

Chronic suppurative bronchopneumonia with multiple lobules of lung are being affected with severe chronic inflammation and interlobular septae are expanded with fibrous connective tissue.

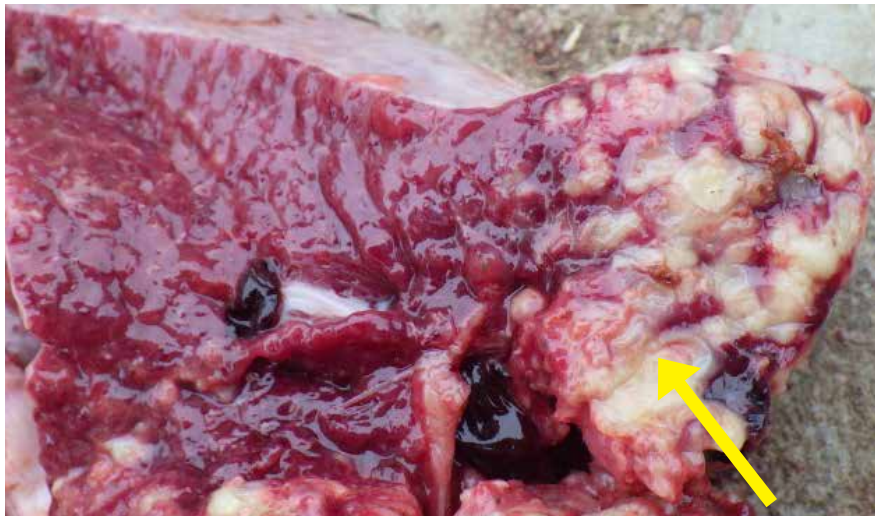

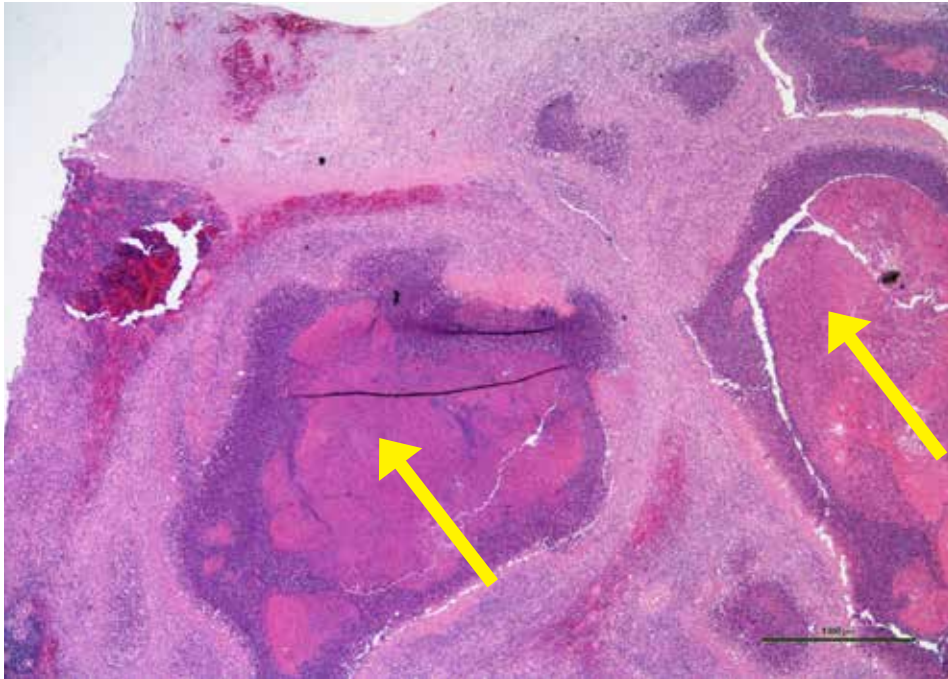**Figure 2.3.3.**

Lung with chronic pneumonia showing round well delineated white areas of abscessation (dark arrow). Small abscesses can be also seen in the heart walls (white arrows).

**Figure 2.3.4.**

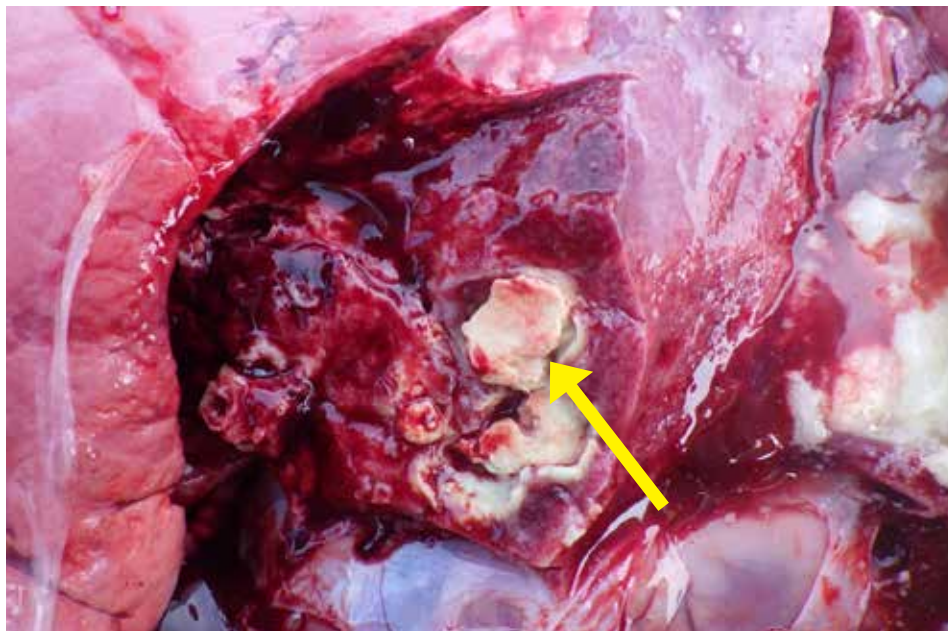
Cut section of lung showing white areas of scarring and abscessation common in chronic bronchopneumonia.





**Figure 2.3.5.**

Low power view of lung showing multiple areas of abscessation (arrows) in chronic suppurative bronchopneumonia.



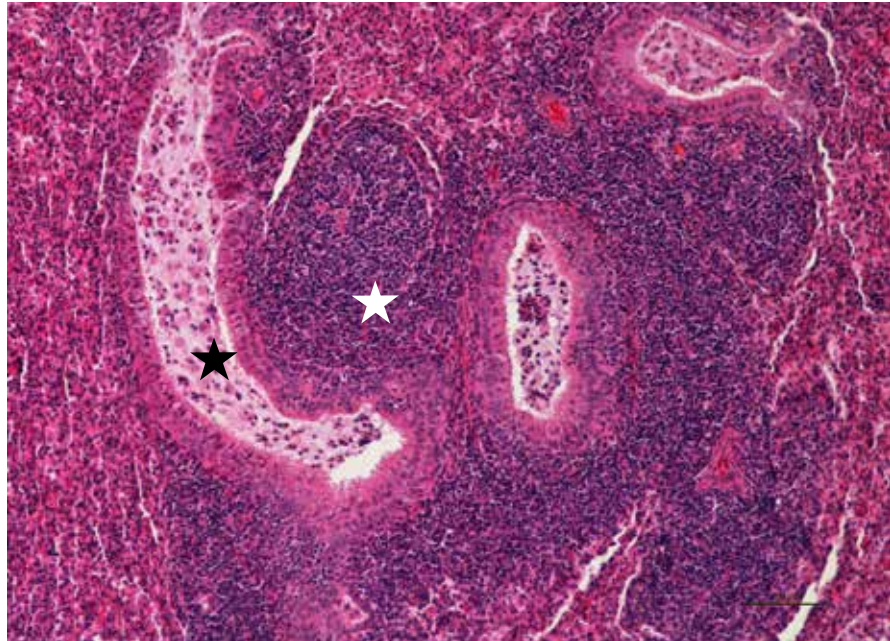
**Figure 2.3.6.**

Lung showing sequestered areas of necrotic tissue in chronic pneumonia.



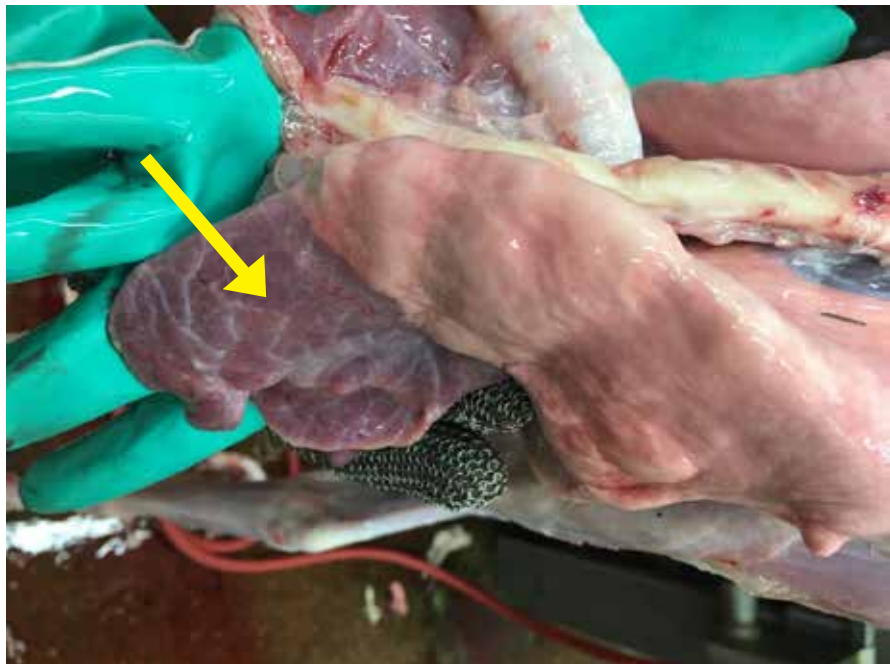
**Figure 2.3.7.**

Chronic, severe, non-progressive pneumonia caused by *Mycoplasma ovipneumoniae* in a lamb. Pneumonia with prominent lymphoid aggregates (white star) surrounding ectatic bronchioles (black star) lined by hyperplastic epithelium are characteristic histologic features.

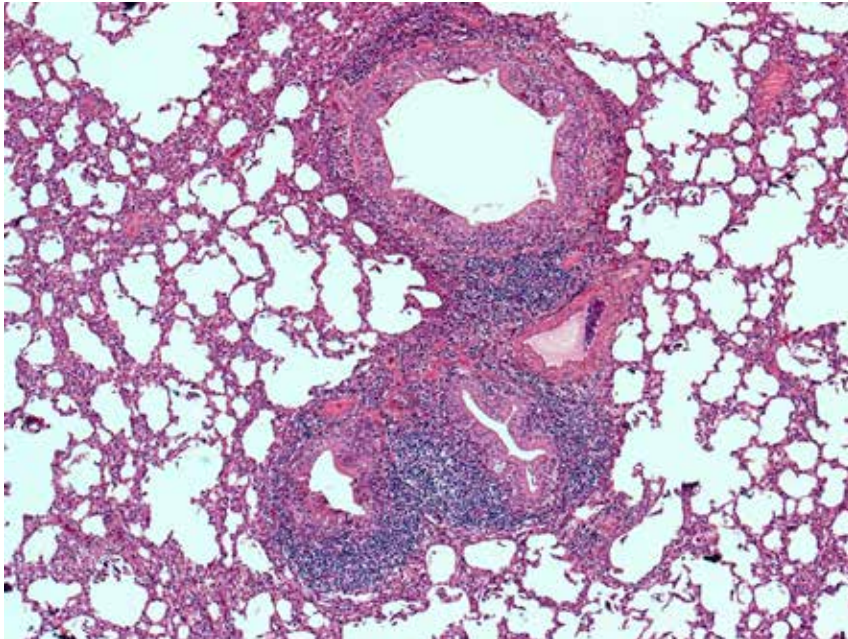


**Figure 2.3.8.**

Chronic pneumonia in a lamb showing consolidated cranio-ventral lobes (arrow).  
*Photo courtesy of M. Spinato.*



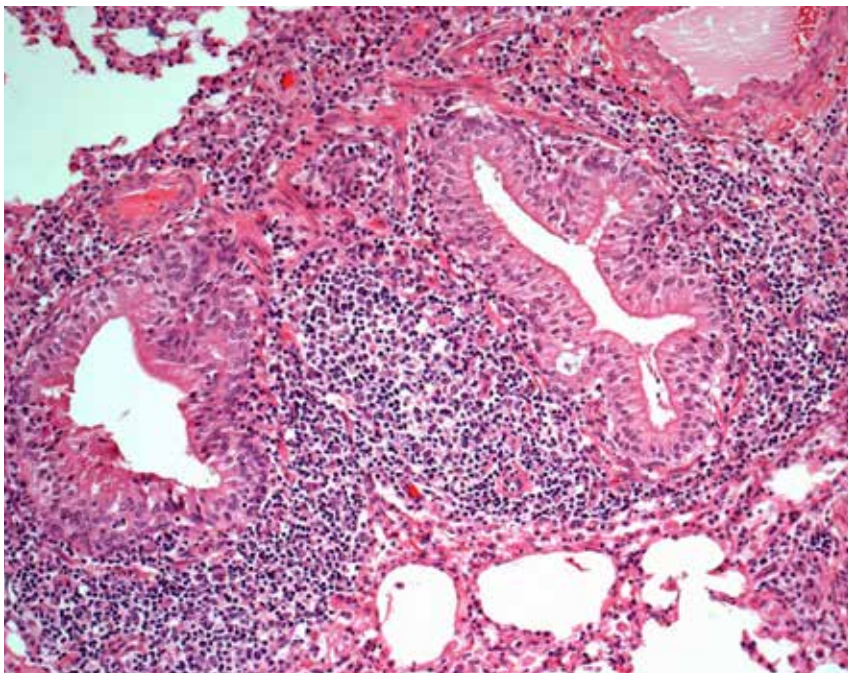




**Figure 2.3.9.**

*Mycoplasma ovipneumoniae* infection in a lamb. 4X. – Prominent peribronchiolar lymphoid aggregates surrounding bronchioles lined by hyperplastic epithelium are characteristic histologic features in early infection.

*Photo courtesy of M. Spinato.*



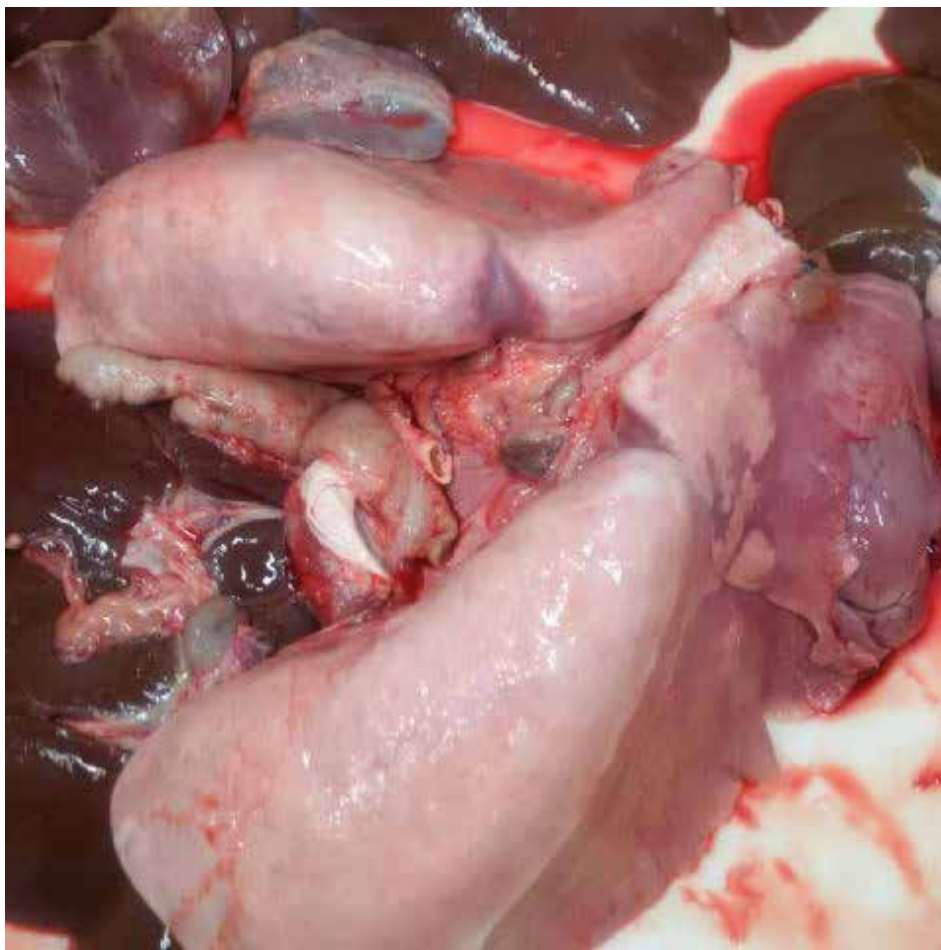**Figure 2.3.10.**

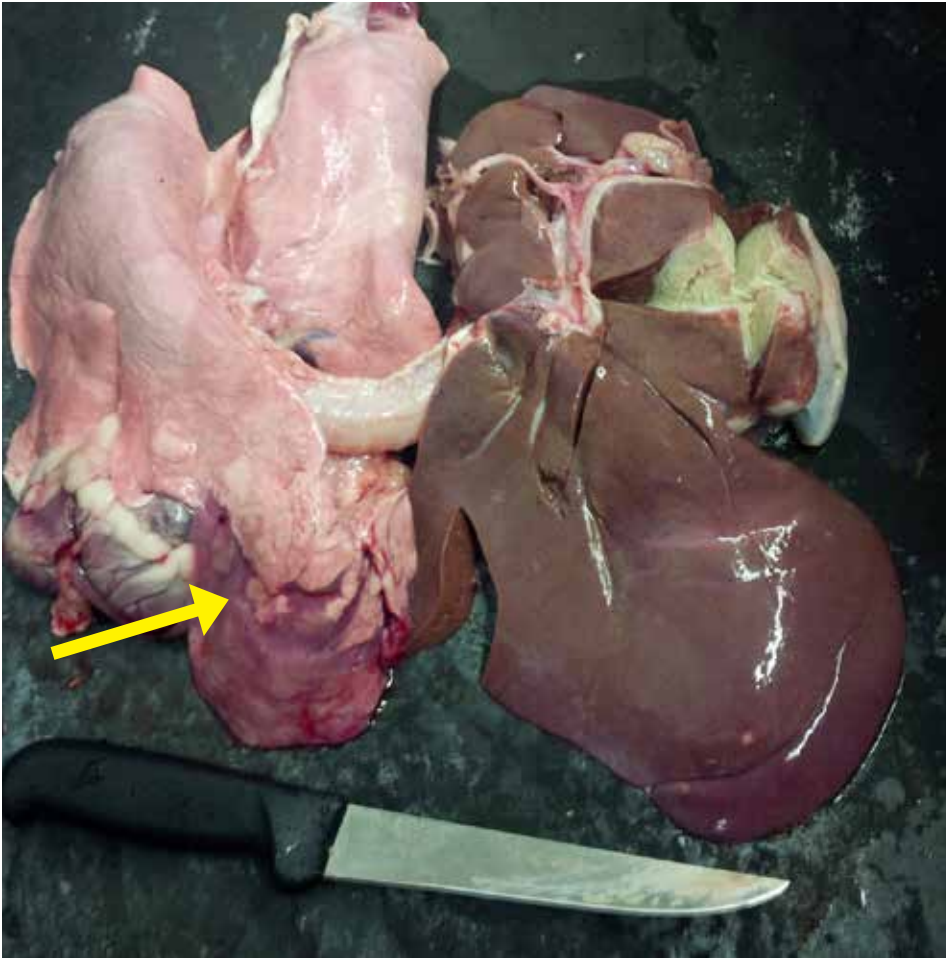
*Mycoplasma ovipneumoniae* pneumonia – 10X. Note the bronchiolar epithelial hyperplasia and the prominent bronchiolar-associated lymphoid nodules that are characteristic histologic lesions.

*Photo courtesy of M. Spinato.*

**Figure 2.3.11.**

Anterior-ventral consolidation  
in *M. ovipneumoniae*.  
*Photo courtesy of Alex Reid.*





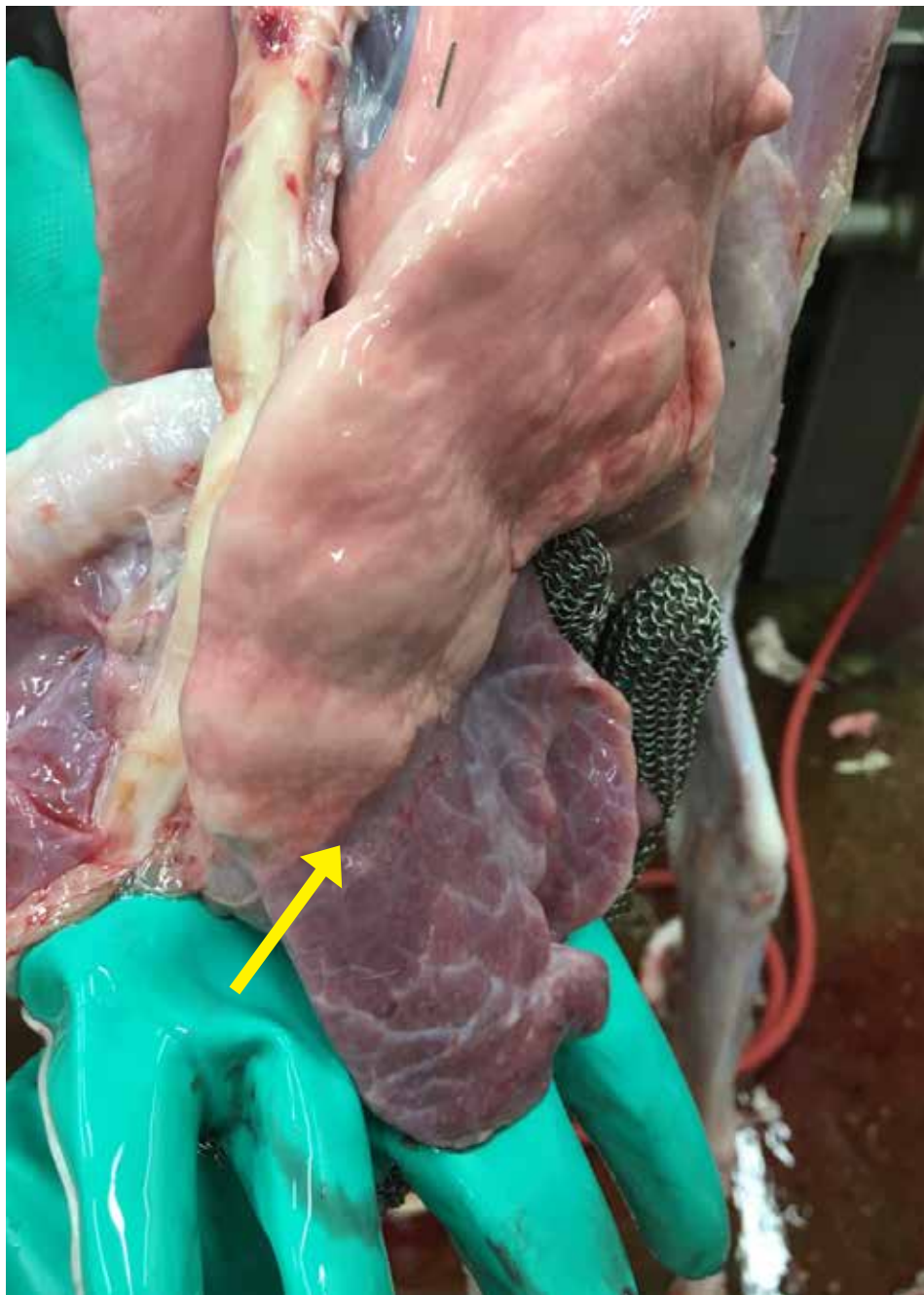**Figure 2.3.12.**

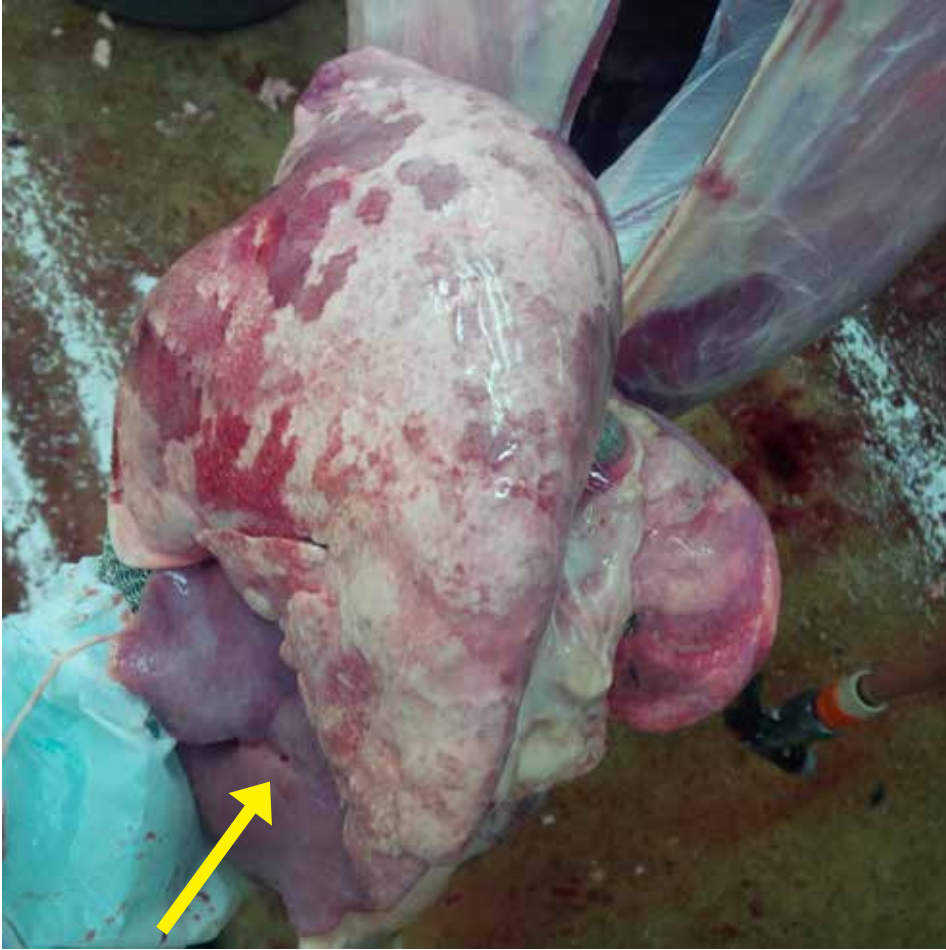Lung with chronic pneumonia caused by *M. ovipneumoniae*.  
*Photo courtesy of Alex Reid.*



**Figure 2.3.13**

Anterior-ventral pneumonia  
caused by *M. ovipneumoniae*.  
*Photo courtesy of Alex Reid.*



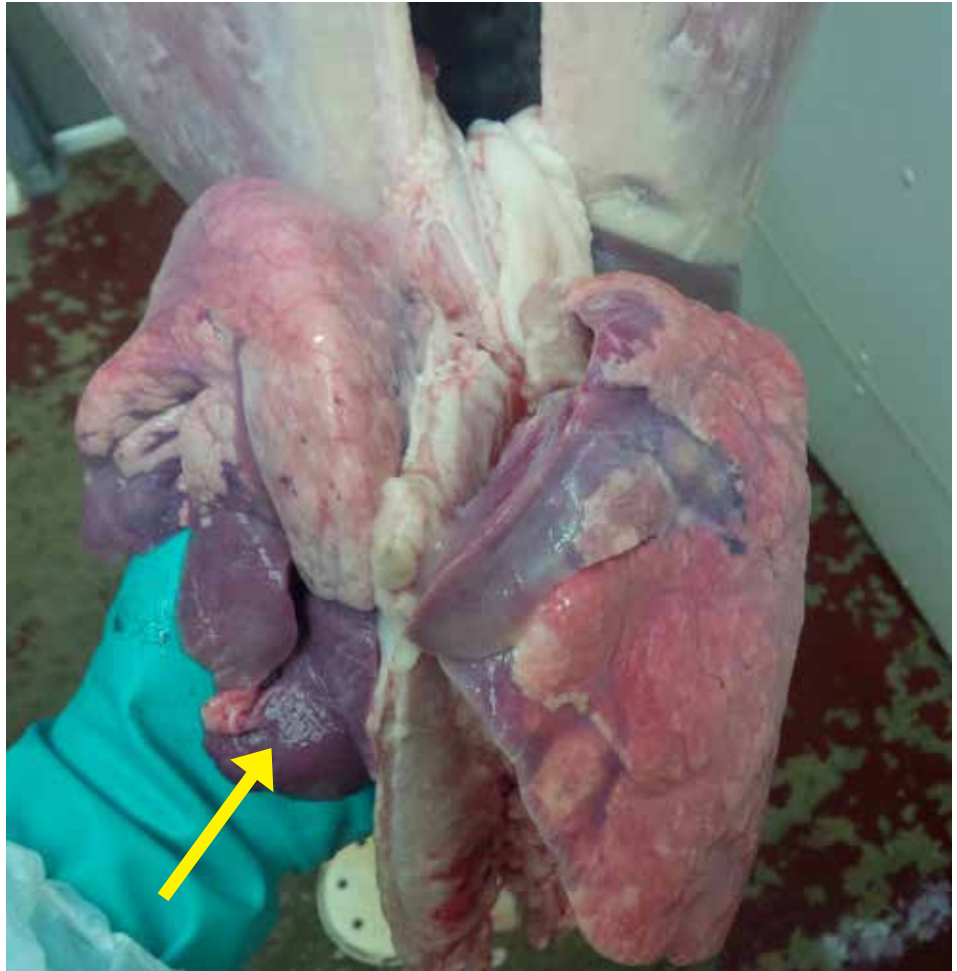


**Figure 2.3.14.**

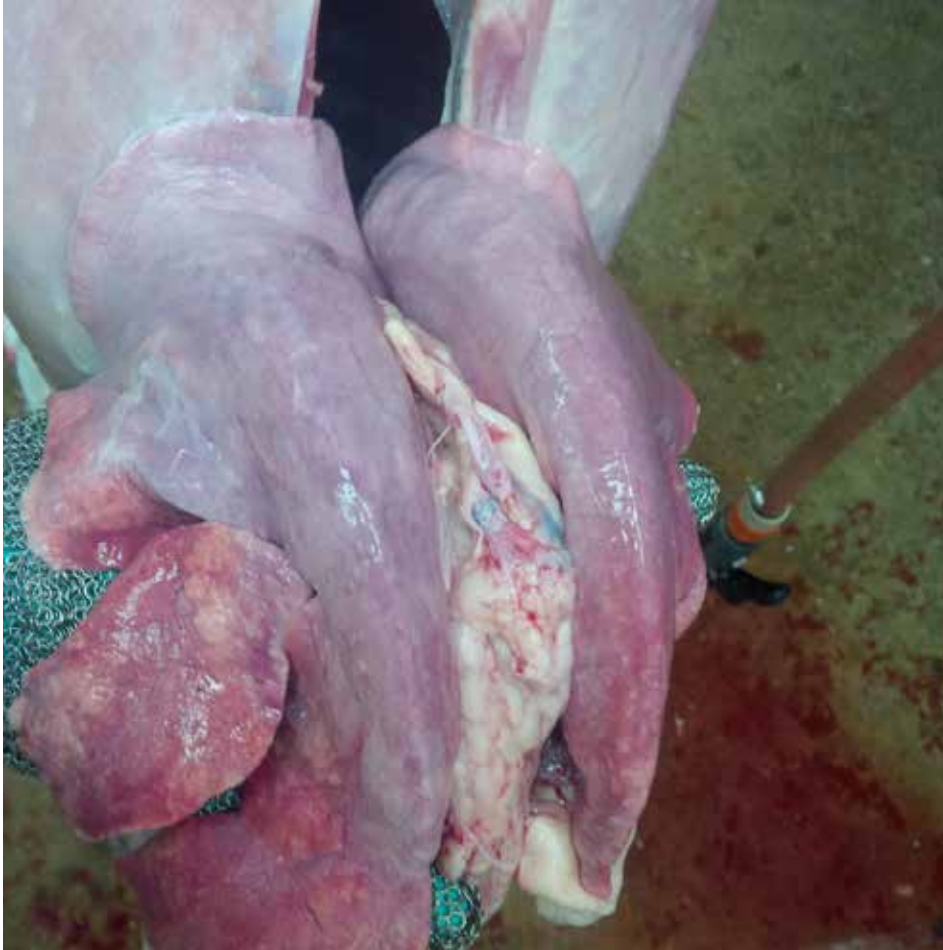*Mycoplasma ovipneumoniae*  
pneumoniae.  
Photo courtesy of Alex Reid.

**Figure 2.3.15.**

*Mycoplasma ovipneumoniae*  
pneumoniae.  
Photo courtesy of Alex Reid.







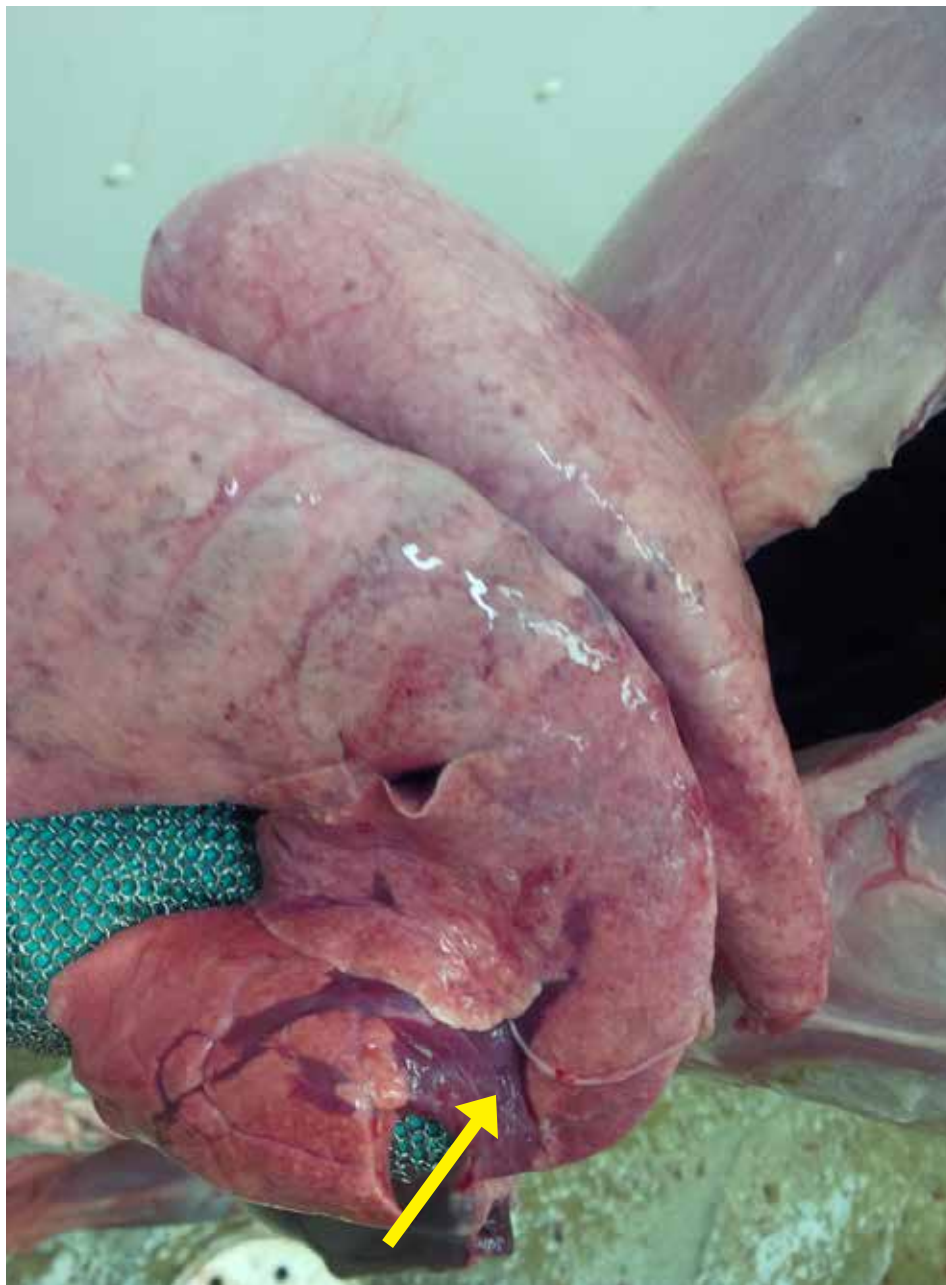**Figure 2.3.16.**

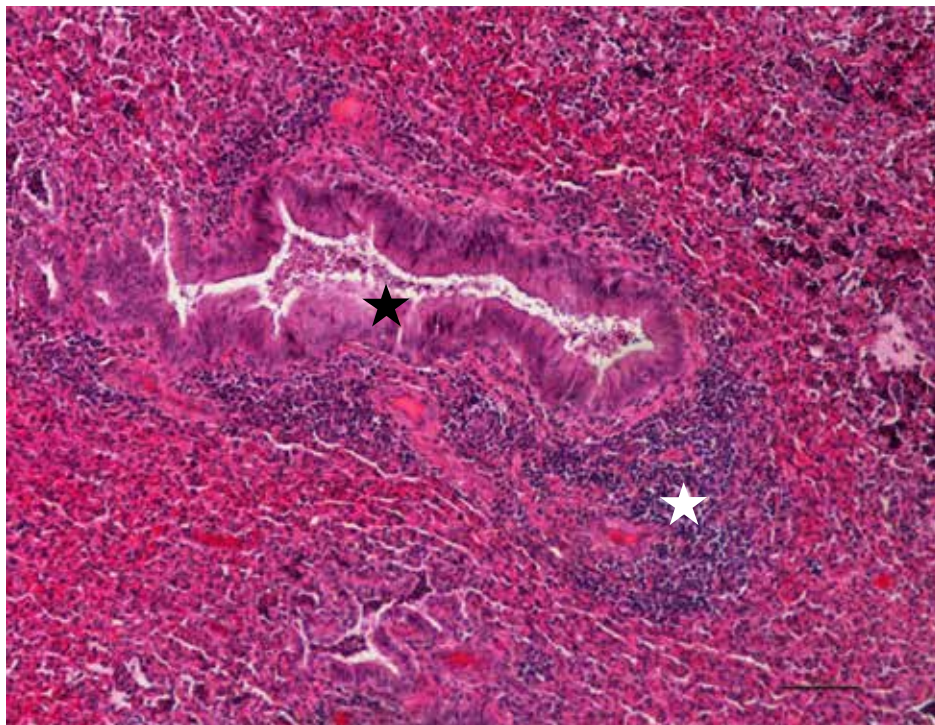
*Mycoplasma ovipneumoniae pneumoniae.*

*Photo courtesy of Alex Reid.*

**Figure 2.3.17.**

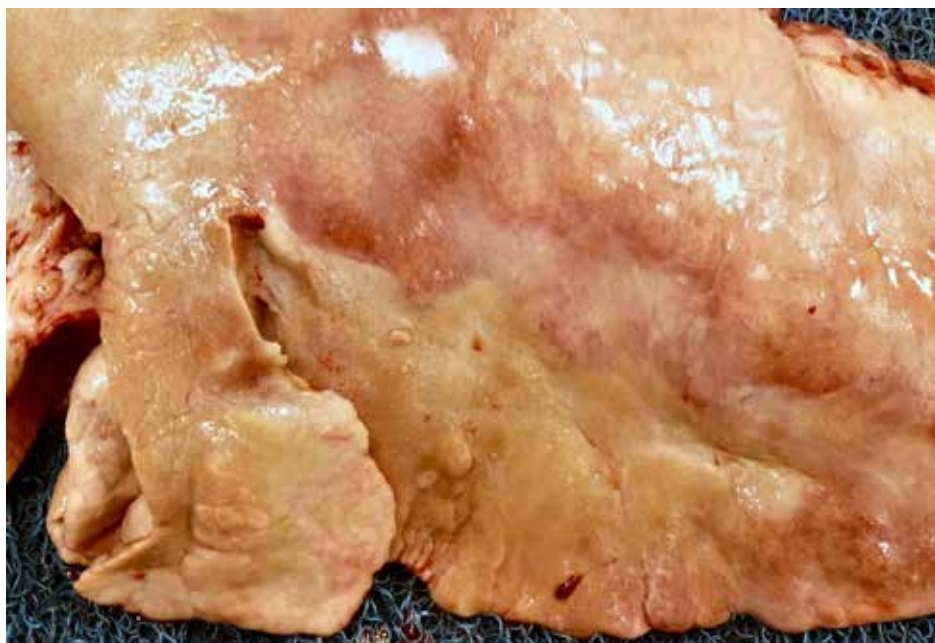*Mycoplasma ovipneumoniae*  
pneumoniae.  
Photo courtesy of Alex Reid.





**Figure 2.3.18.**

Chronic, severe, non-progressive pneumonia a lamb. *Mycoplasma arginini* and *Mannheimia haemolytica* were identified in this lamb. Note lymphoid aggregates (white star) surrounding ectatic bronchioles (black star) lined by hyperplastic epithelium are characteristic histologic features.



**Figure 2.3.19.**

*Mycoplasma ovipneumoniae* infection of the lung. Photo courtesy of P. Menzies.

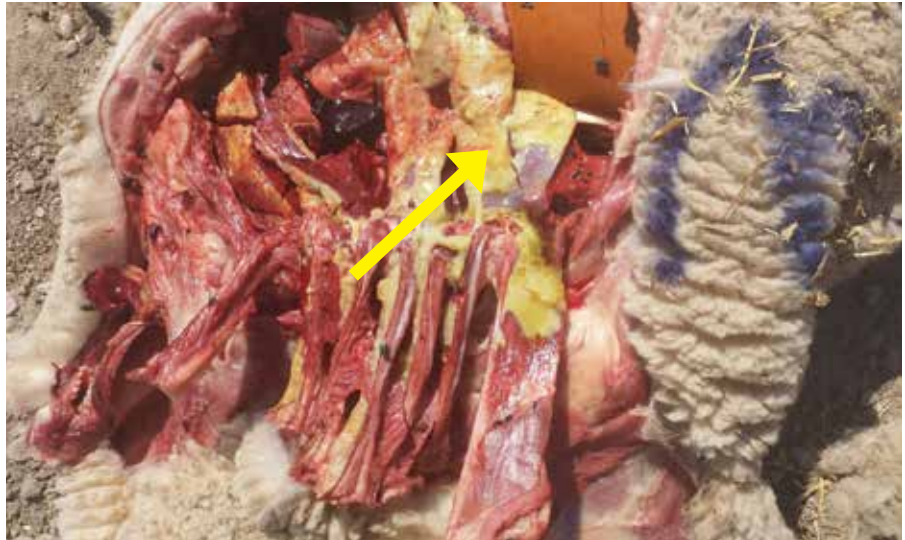

## 2.4. Pleuritis

Pleuritis is a condition where the lining membrane of chest cavity and surrounding the lung lobes becomes inflamed. Bacterial infections of lung often cause pleuritis.

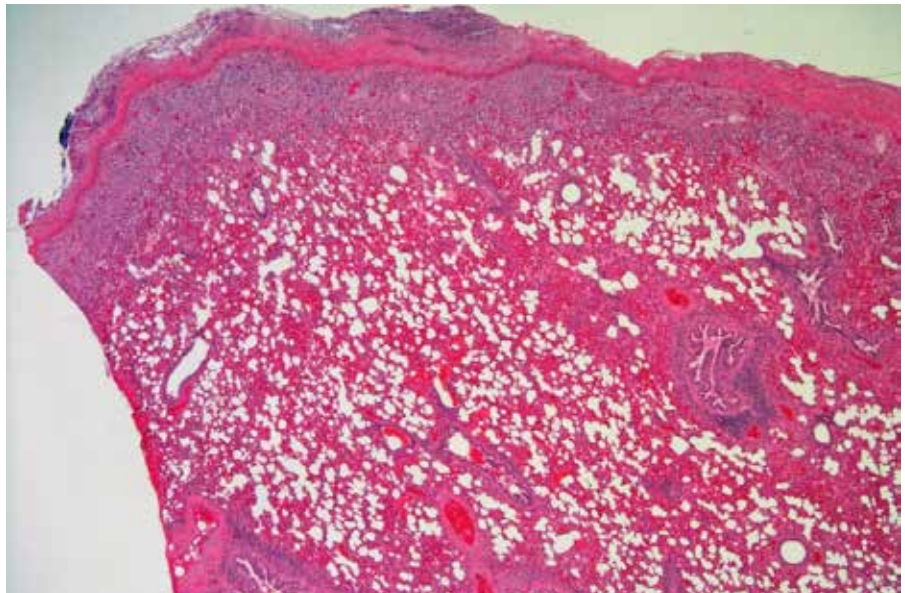
**Figure 2.4.1.**

Yellow fibrin on surface of lung  
in a lamb with acute pleuritis.  
Lung adhered to ribs.

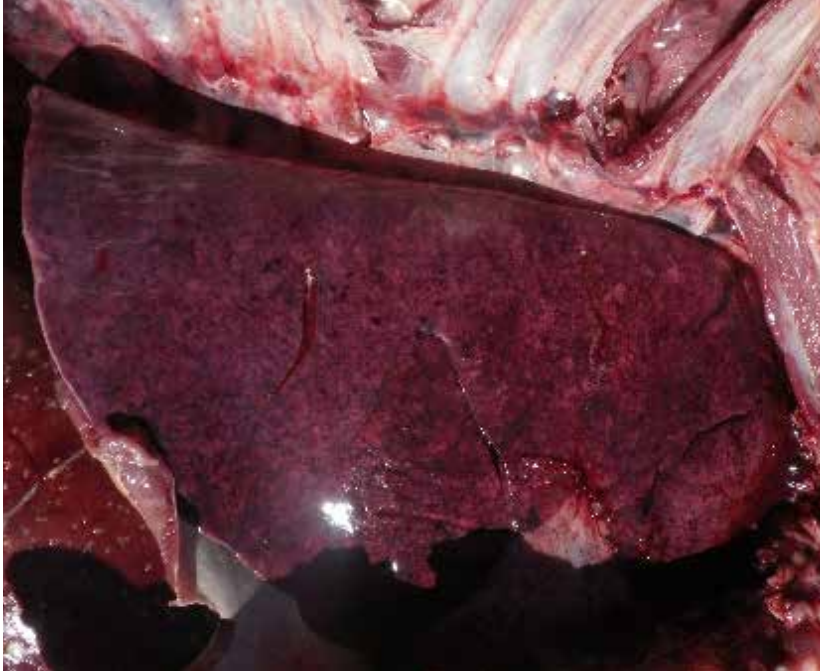


**Figure 2.4.2.**

This animal had fibrino-suppurative and hemorrhagic pleuropneumonia. Lung tissues tested positive for *Mycoplasma arginini*. *Enterococcus* and *Bacillus* species were isolated from bacterial culture of lung tissues. *Mycoplasma arginini* infections in lambs are often associated with secondary bacterial infections.

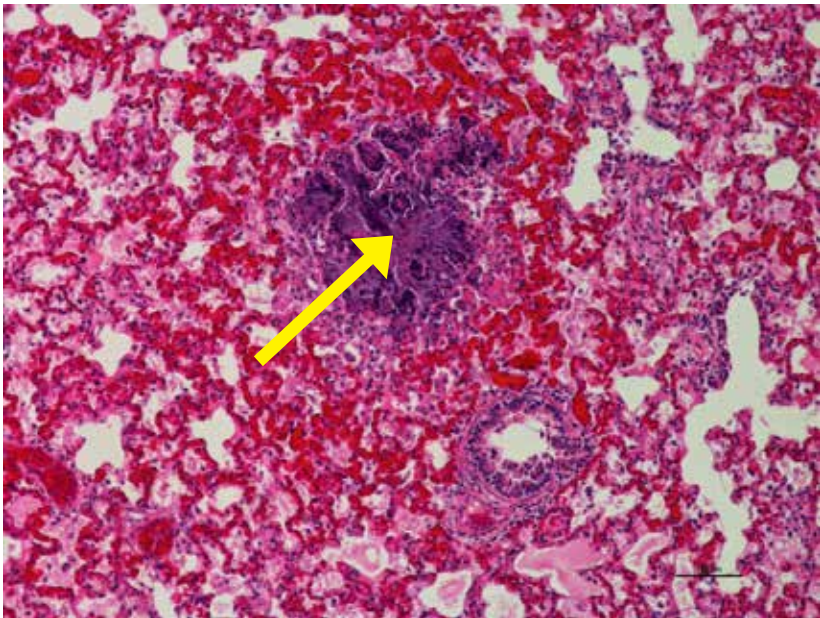


## 2.5. Embolic Pneumonia



**Figure 2.5.1.**

Lamb died of bacterial septicemia. On gross examination, lung lobes failed to collapse, were edematous and diffusely congested with multifocal petechial hemorrhages.



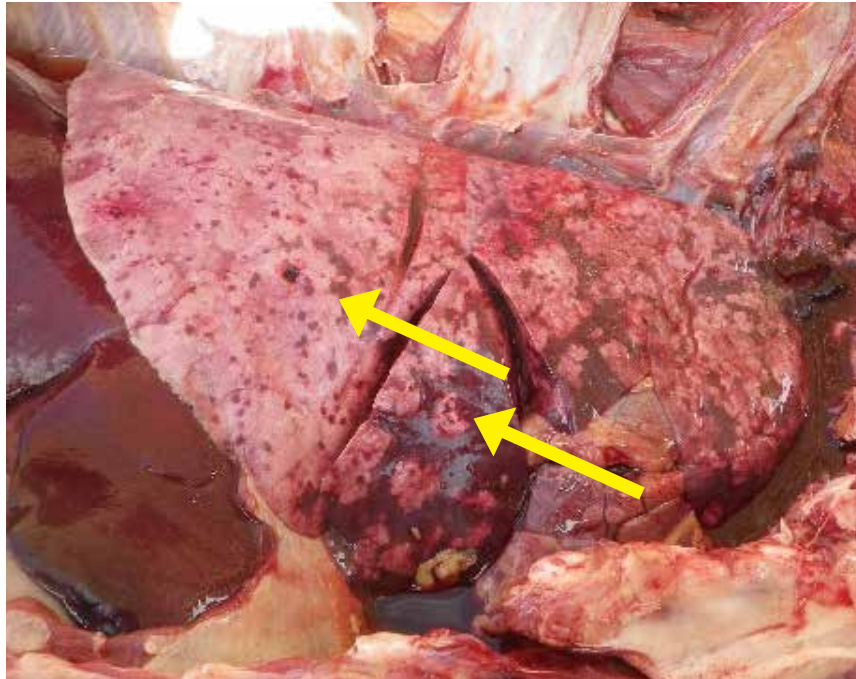
**Figure 2.5.2.**

Bacterial embolic pneumonia associated with *Bibersteinia trehalosi* infection in a lamb. Low power view of lung showing necrotic alveoli filled with aggregates of neutrophils centered on bacterial colonies (arrow). The other areas of lung are affected with congestion and edema.

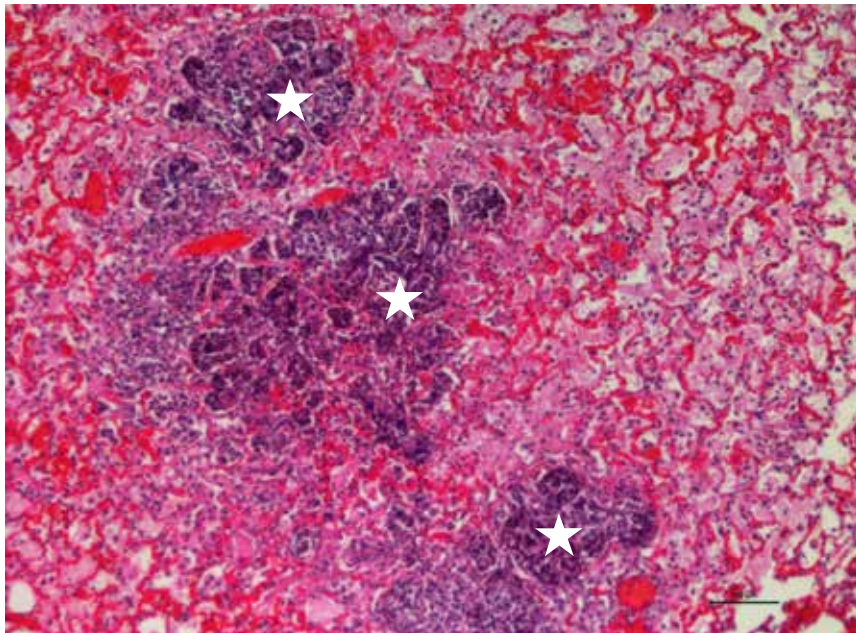


**Figure 2.5.3.**

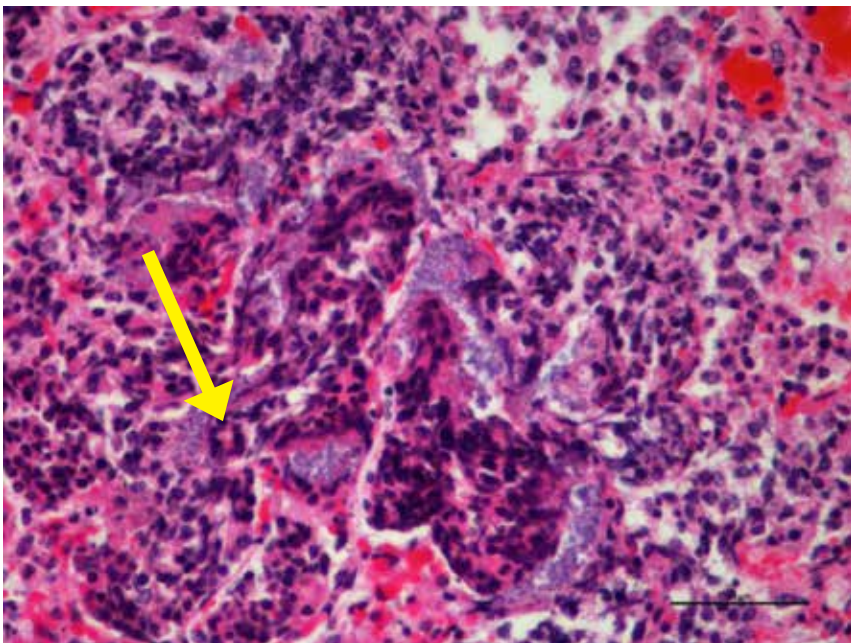
Lamb died due to bacterial septicemia. Grossly, lungs were edematous with multifocal hemorrhages (arrows).

**Figure 2.5.4.**

Bacterial embolic pneumonia associated with *Bibersteinia trehalosi* infection in a lamb. Low power view of lung showing multifocal areas of alveolar necrosis with aggregates of dying neutrophils centered on bacterial colonies (stars). Adjacent alveoli showing congestion and filled with proteinaceous edema and fibrin.

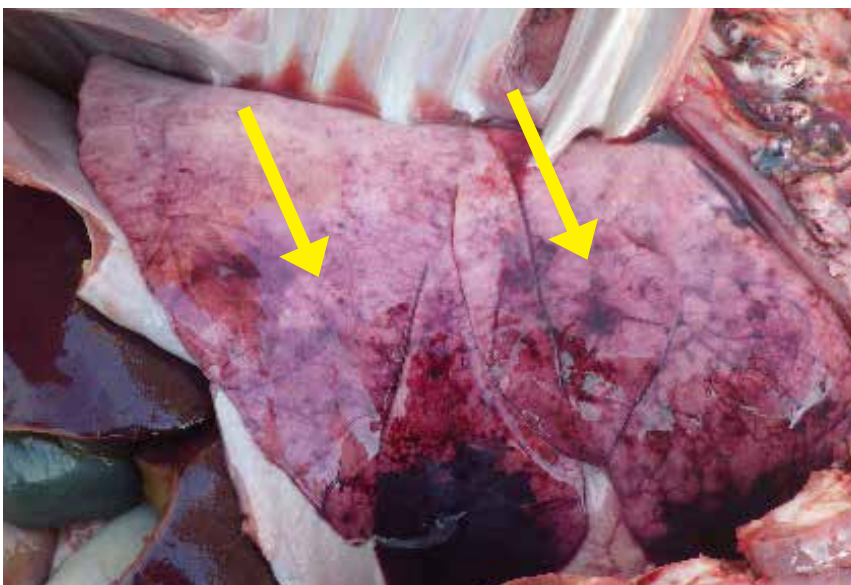






**Figure 2.5.5.**

Embolic bacterial pneumonia with necrotizing alveolitis with intra-lesional bacterial colonies (arrow). *Bibersteinia trehalosi* was isolated from the lung.

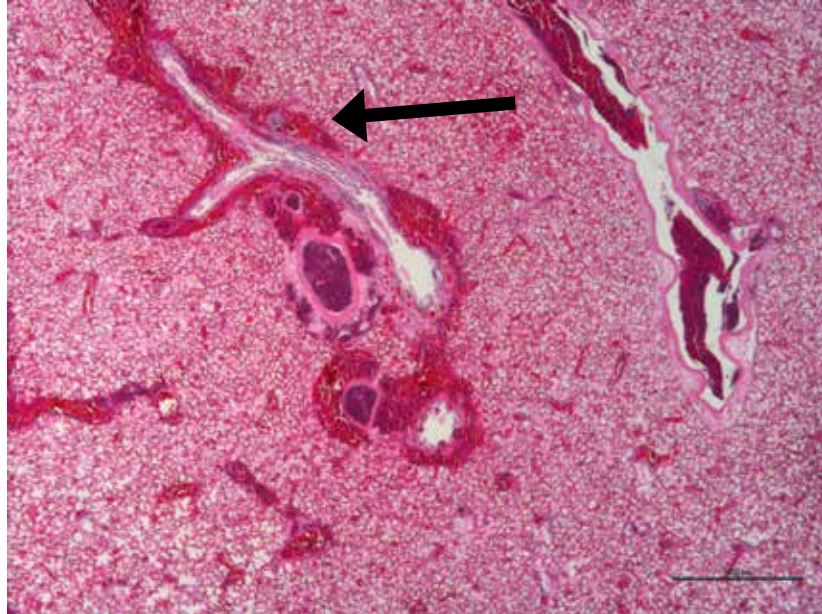

**Figure 2.5.6.**

Lamb died due to bacterial **septicemia** caused by *Bibersteinia trehalosi*. Speckled red hemorrhagic spots in the lung (arrows) are typically observed in this kind of bacterial septicemia.

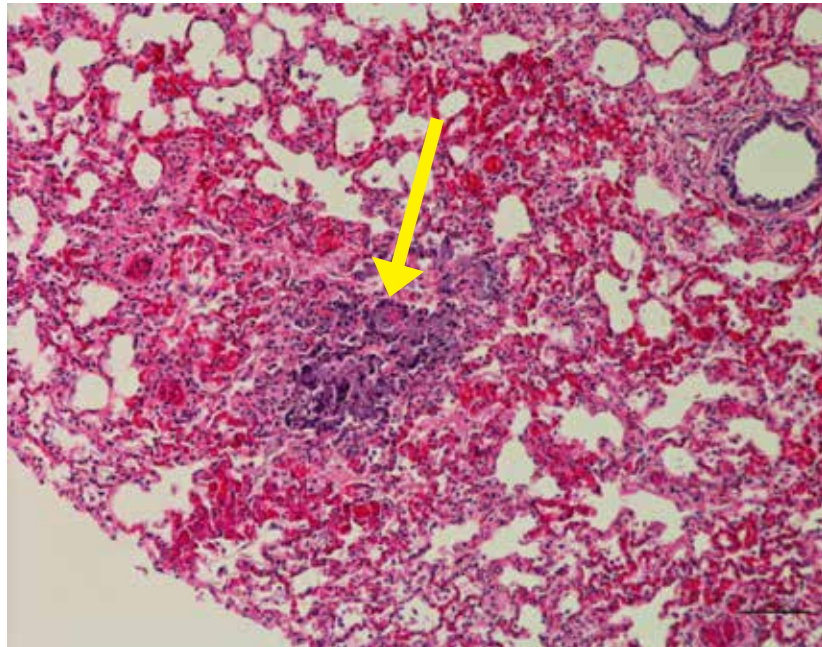
**Figure 2.5.7.**

Edematous lung from the same lamb (Fig. 2.5.6) showing perivascular hemorrhages (arrow) and congestion.

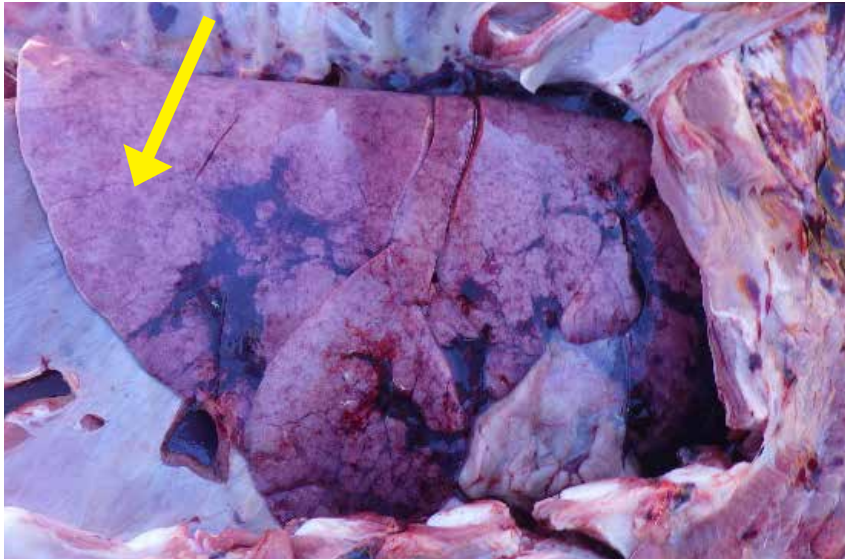


**Figure 2.5.8.**

Low power view of lung tissue from the same lamb (Fig. 2.5.6) showing congested alveolar walls and focal area of necrotizing alveolitis with intralesional bacterial colonies (arrow). *Bibersteinia trehalosi* was isolated from the lung tissues.

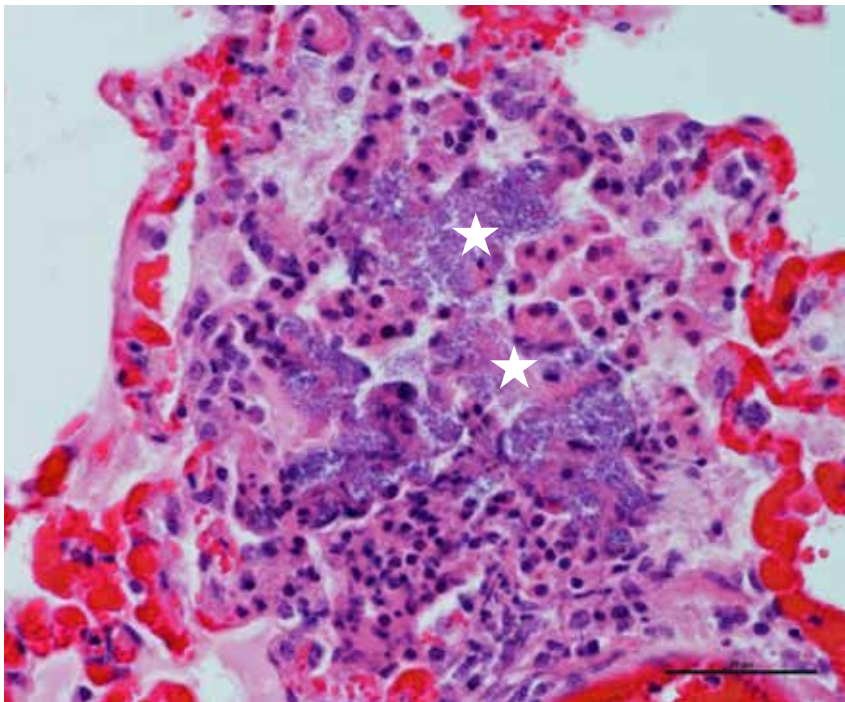






**Figure 2.5.9.**

Lamb showing embolic pneumonia (speckled red spots throughout lung lobes), congestion and consolidation throughout lung, particularly in ventral part of lung lobes.



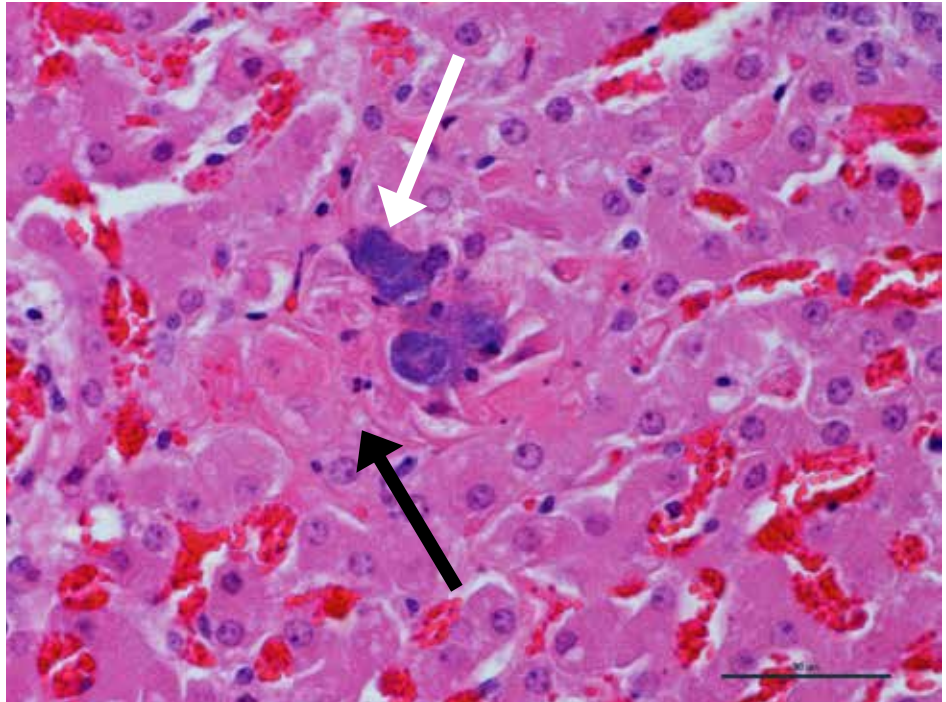
**Figure 2.5.10.**

High power view of lung from a lamb that died due to bacterial septicemia showing congested alveolar walls and bacterial colonies (stars) filling the alveoli, and capillaries and interstitium of alveolar walls. *Bibersteinia trehalosi* was isolated from lung tissues.



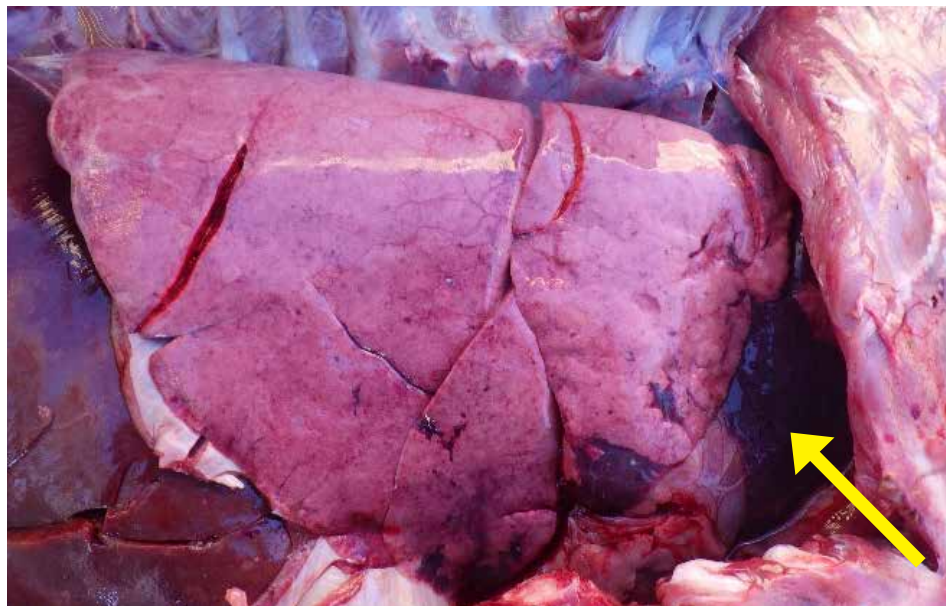
**Figure 2.5.11.**

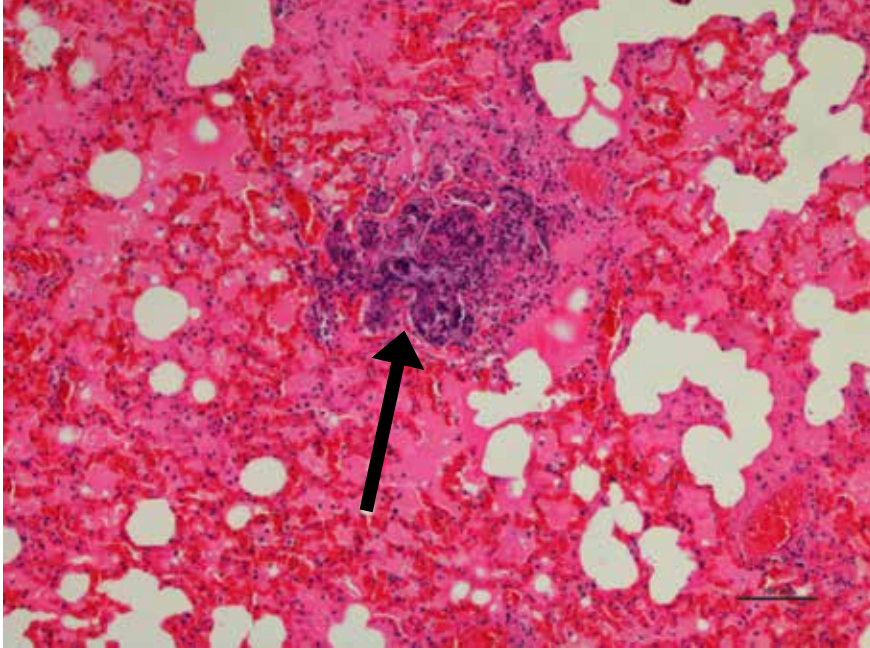
Early bacterial septicemia caused by *Bibersteinia trehalosi*. High power view of liver showing hepatocyte acute necrosis (dark arrow) with adjacent bacterial colonies in the hepatic sinusoids (white arrow).



**Figure 2.5.12.**

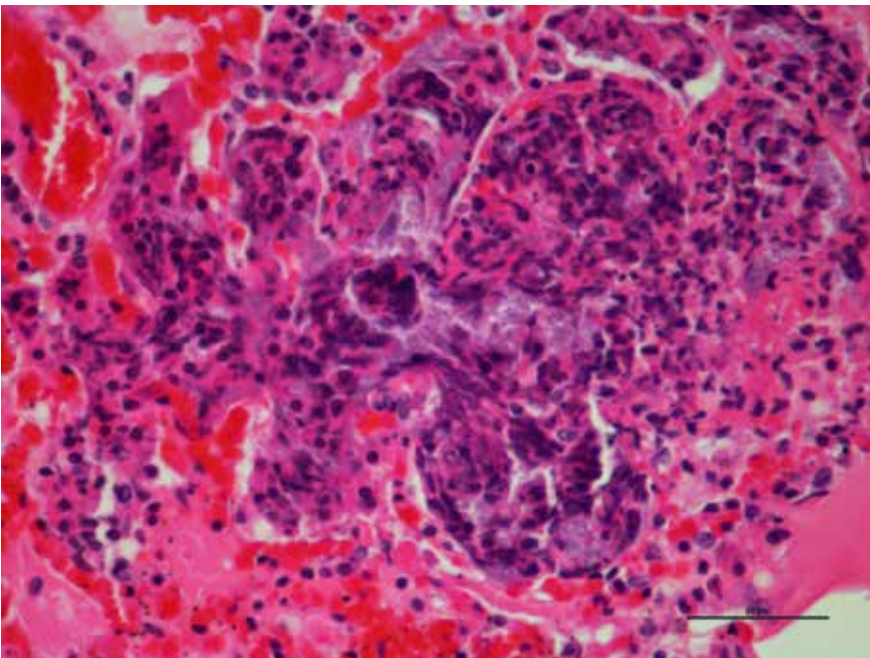
Atero-Ventral lung lobes are dark red and consolidated. Caudo-dorsal lobes failed to collapse due to edema from bacterial septicemia caused by *Bibersteinia trehalosi*.





**Figure 2.5.13.**

Low power view of lung from the same lamb (Fig. 2.5.12) showing congestion and edema with a focal area of necrotizing alveolitis and intralobular bacterial colonies (arrow). *Bibersteinia trehalosi* was isolated from the lung tissues.



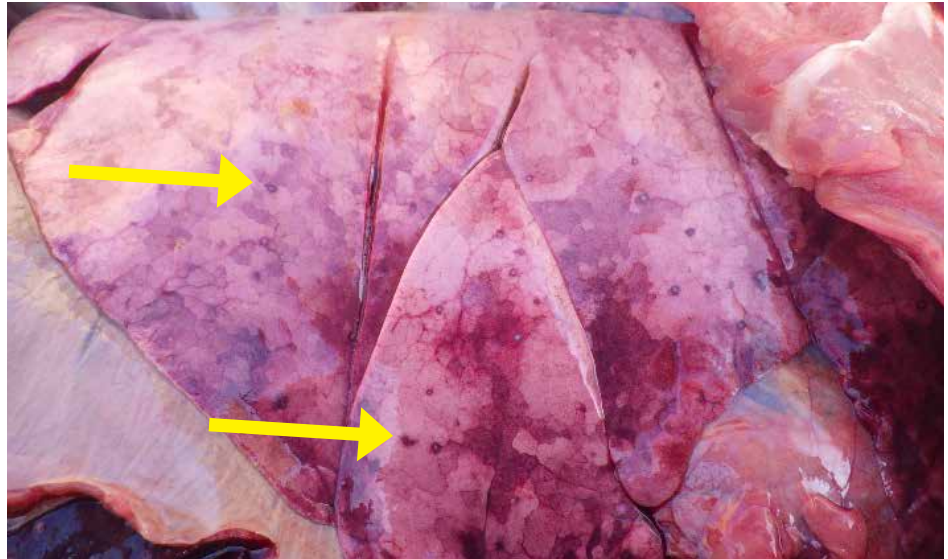
**Figure 2.5.14.**

High power view of pulmonary edema and hemorrhage with necrotizing alveolitis in a lamb died due to bacterial septicemia. *Bibersteinia trehalosi* was isolated from the lung tissues.



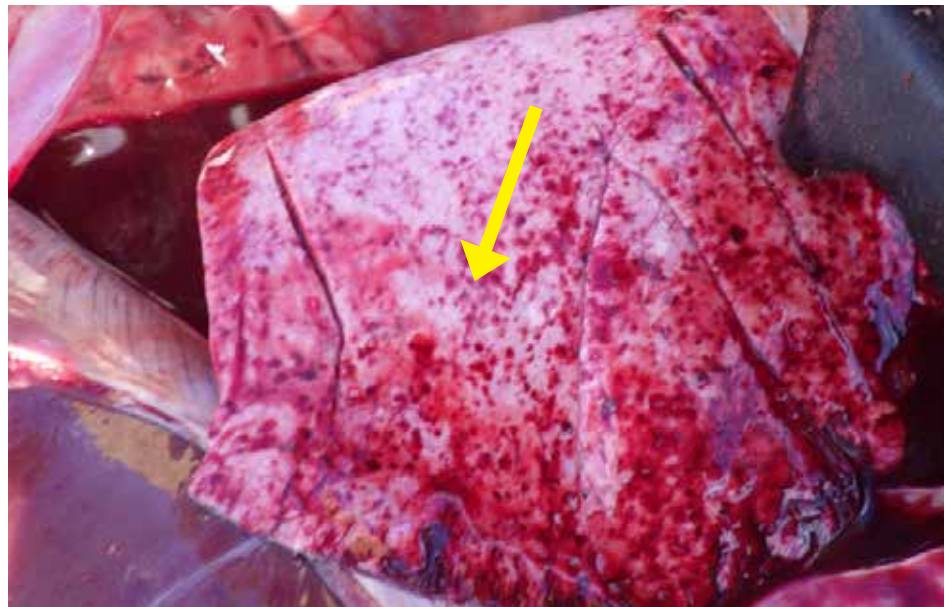**Figure 2.5.16.**

Embolic pneumonia with speckled red spots (arrows) throughout lung - *Bibersteinia trehalosi* is the most common causative agent isolated from lambs with this type of lesions.

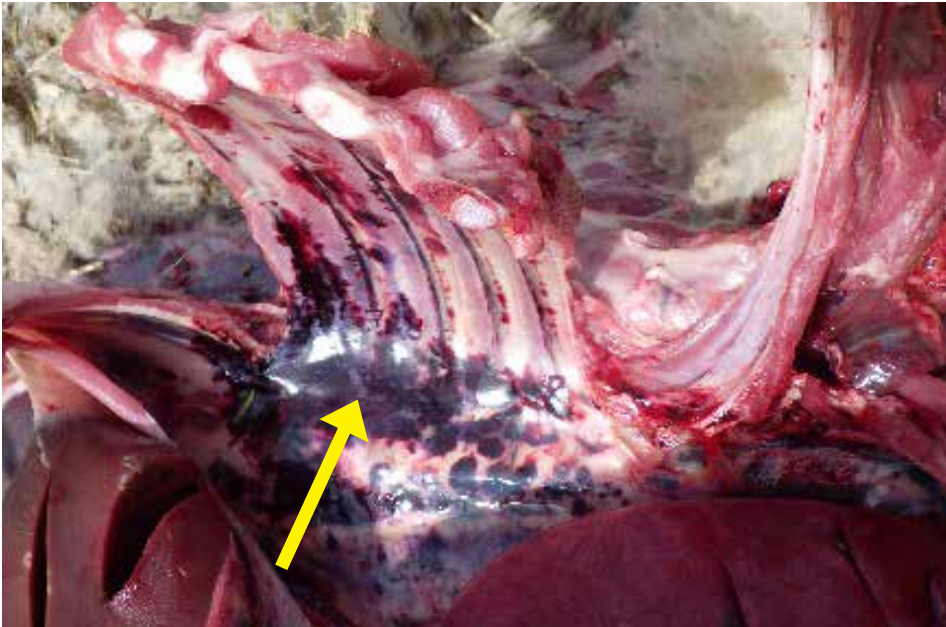


**Figure 2.5.17.**

Sudden death in a lamb. On gross examination, petechial hemorrhages and edema typical of bacterial septicemia in lungs were observed.

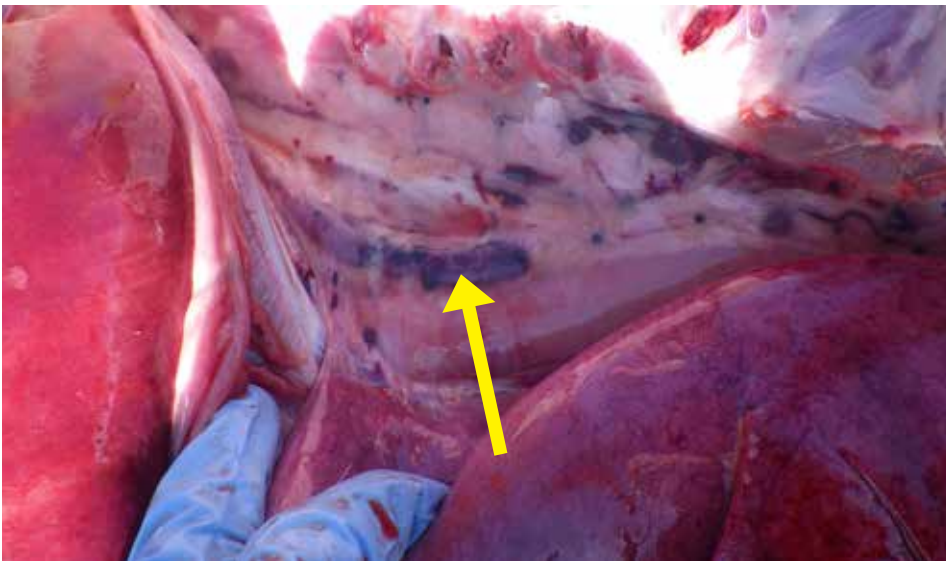






**Figure 2.5.18.**

Petechial hemorrhages on pleural surface – typically seen in septicemia.

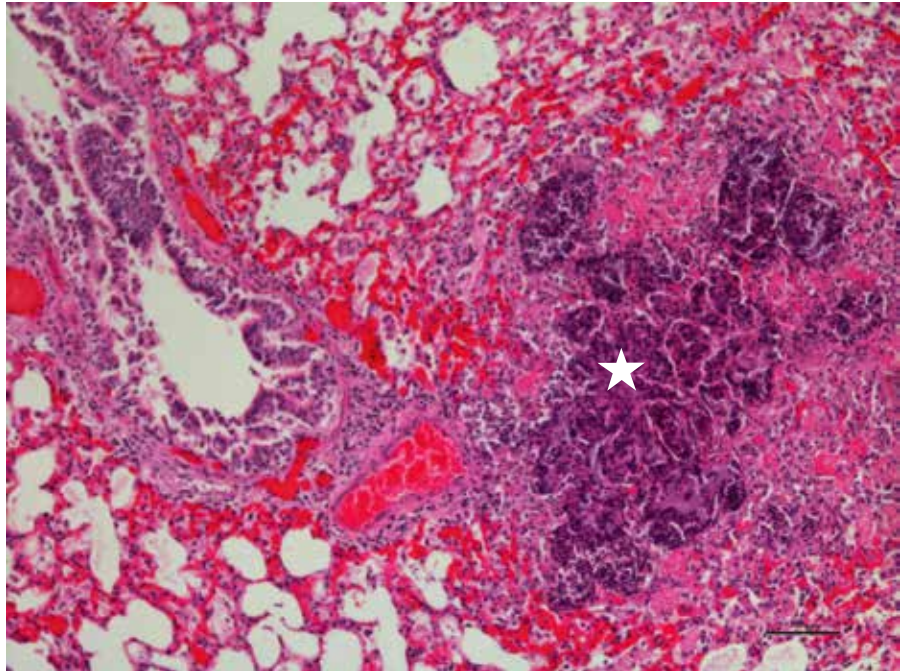


**Figure 2.5.19.**

Hemorrhage present on the pleural surface of thoracic cavity.

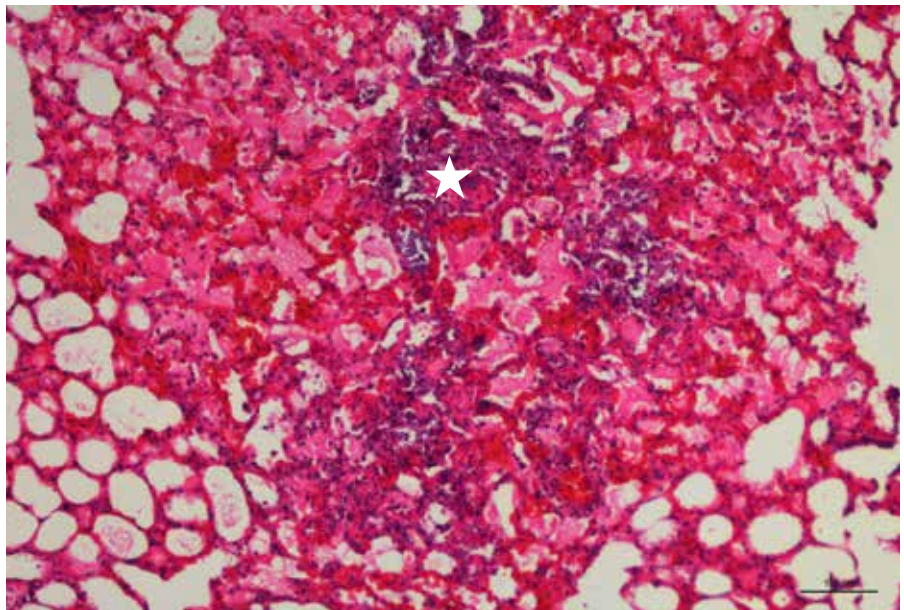
**Figure 2.5.20.**

Histology of lung from the same lamb (Figure 2.5.17) showing area of necrotizing alveolitis (star) typical of embolic bacterial pneumonia. *Bibersteinia trehalosi* was isolated from the lung tissues.

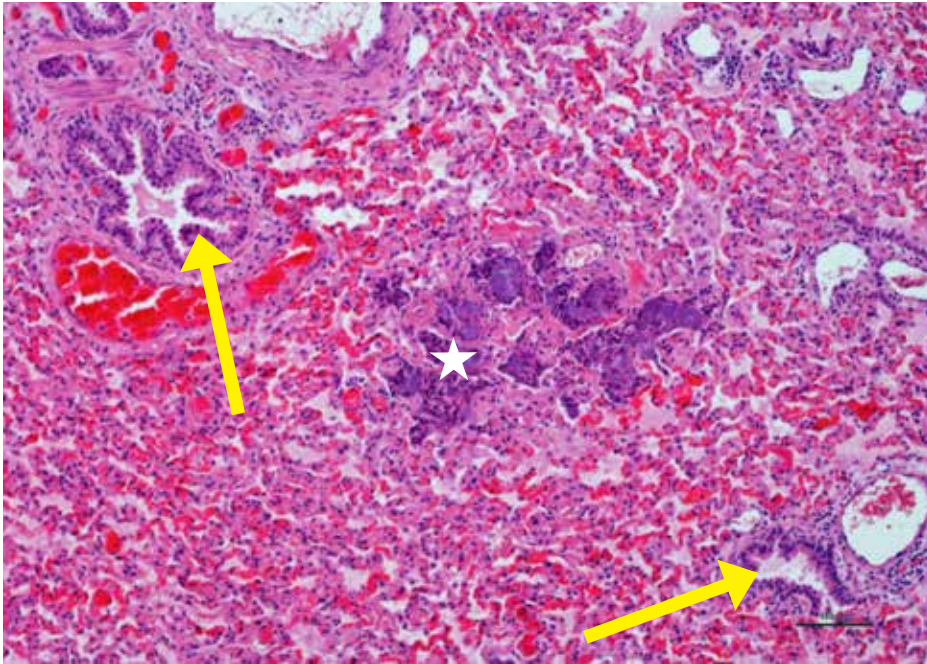


**Figure 2.5.21.**

Lower view of same lung showing embolic bacterial pneumonia with edema, congestion and hemorrhages centered on bacterial colonies (star).

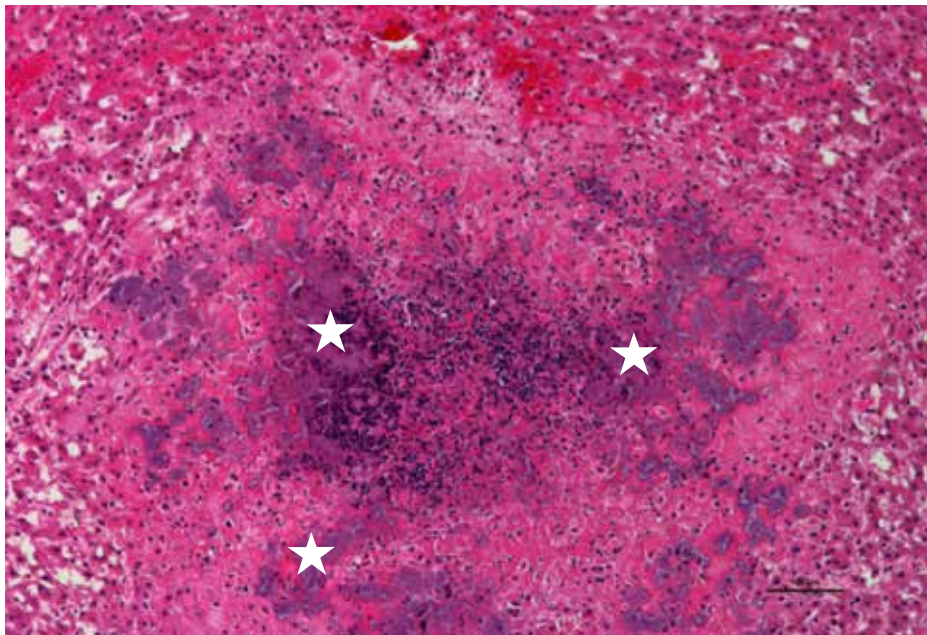






**Figure 2.5.22.**

Lung showing embolic pneumonia with necrotizing alveolitis and intra-lesional bacterial colonies (star). Airways (arrows) are spared.



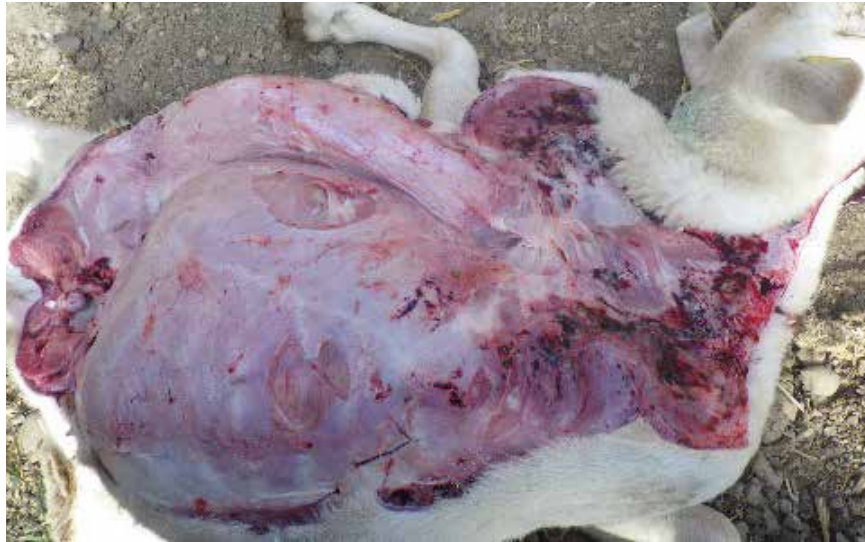**Figure 2.5.23.**

High power view of liver from same lamb showing area of necrotizing hepatitis with aggregates of dying neutrophils centered on bacterial colonies (stars).



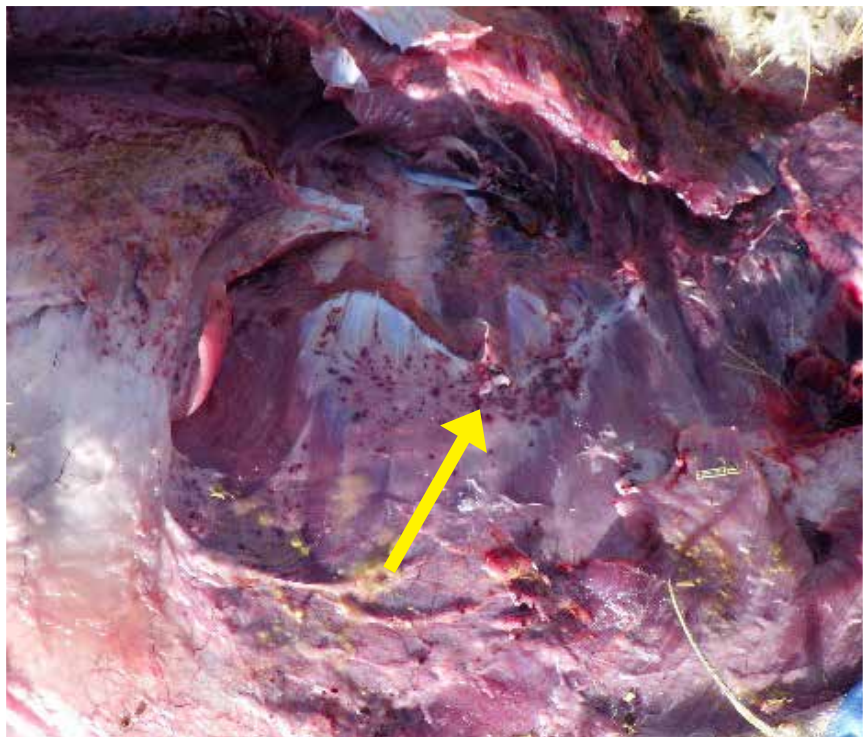
**Figure 2.5.24.**

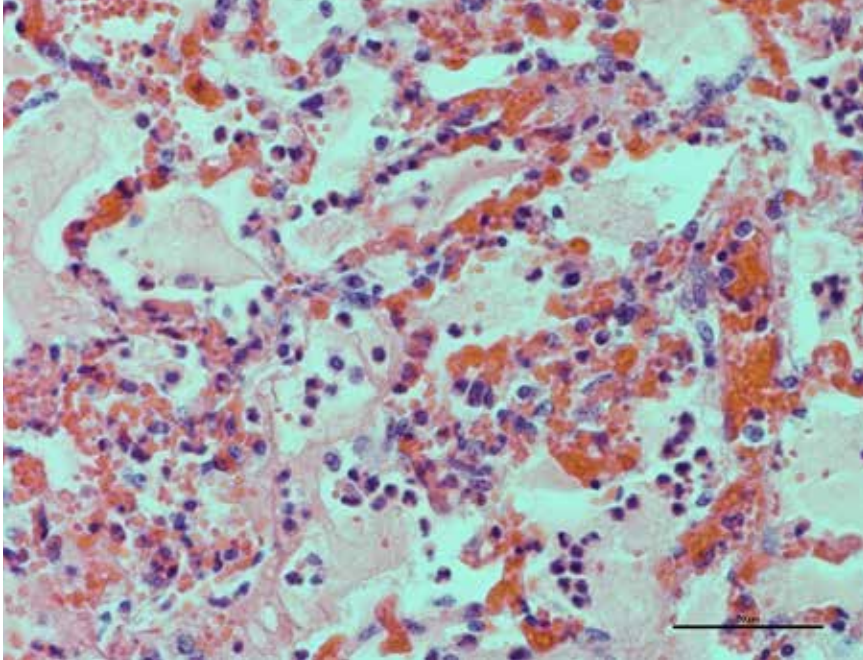
Petechial hemorrhages are commonly seen in lambs dying due to bacterial septicemia which is often caused by *Bibersteinia trehalosi* or *E. coli*.



**Figure 2.5.25.**

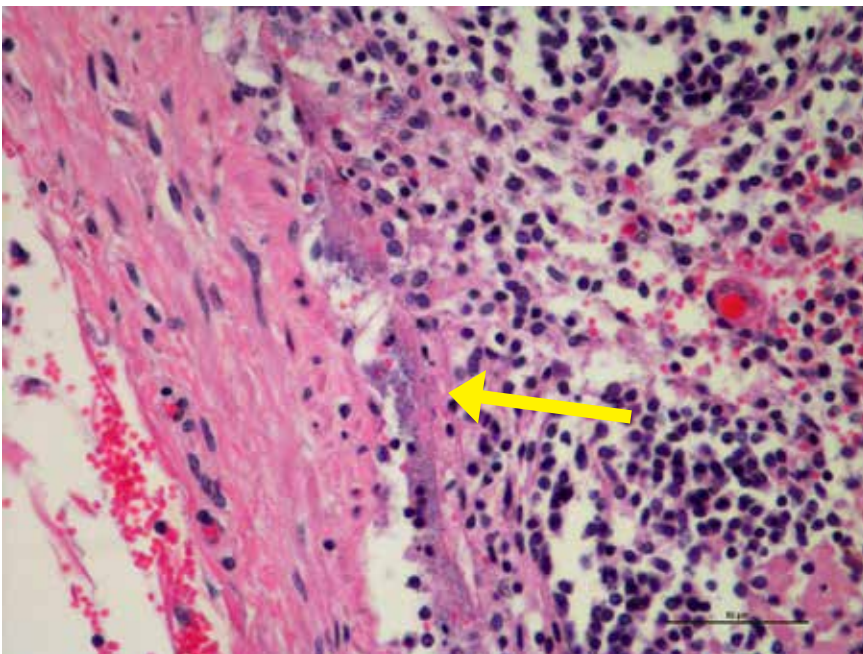
Petechial hemorrhages in a lamb that died due to bacterial septicemia caused by *E. coli*.





**Figure 2.5.26.**

Lung tissues from the same lamb (Fig. 2.5.25) have histological evidence of bacterial septicemia with edema/fibrin filled alveoli and inflammatory cells in the alveolar walls. *E. coli* was isolated from the lung.



**Figure 2.5.27.**

Bacterial showering in sub-capsular sinus of a mediastinal lymph node from the same lamb (Fig. 2.5.24) that died due to bacterial septicemia caused by *E. coli*.

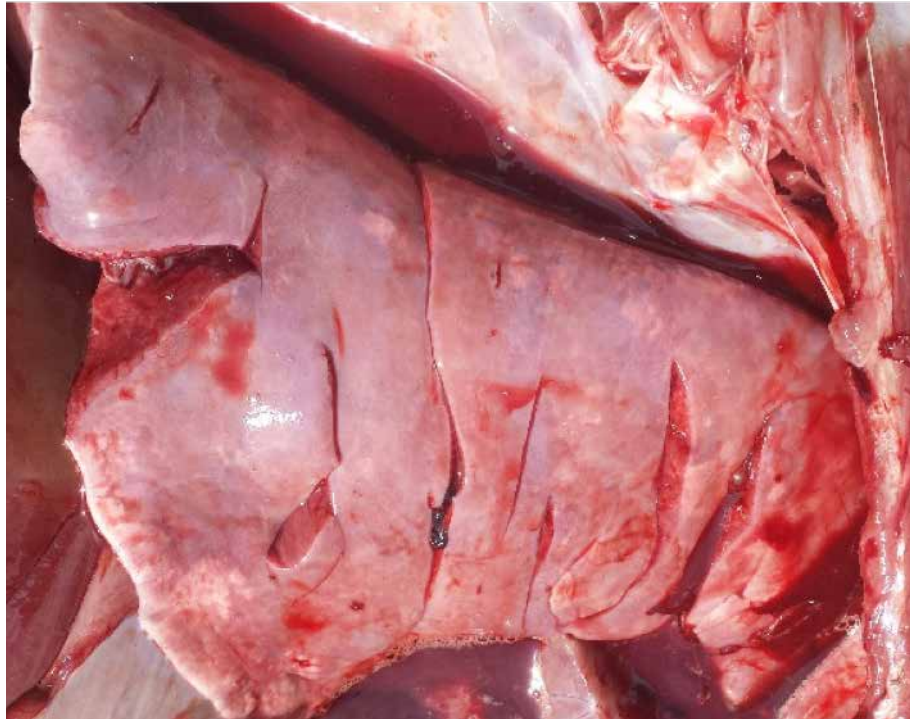


## 2.6. Interstitial Pneumonia

Interstitial Pneumonia in lambs most often associated with bacterial septicemia.

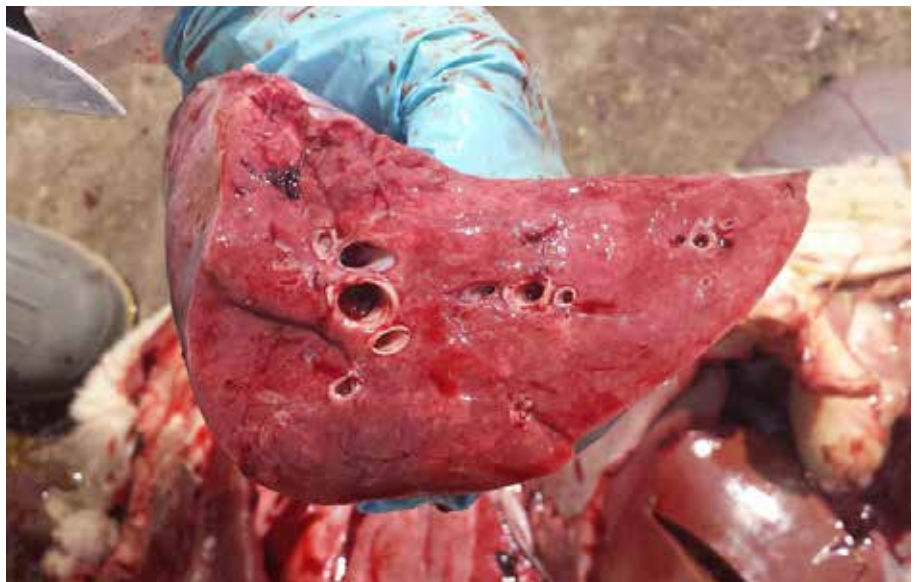**Figure 2.6.1.**

Non-collapsed meaty lung.

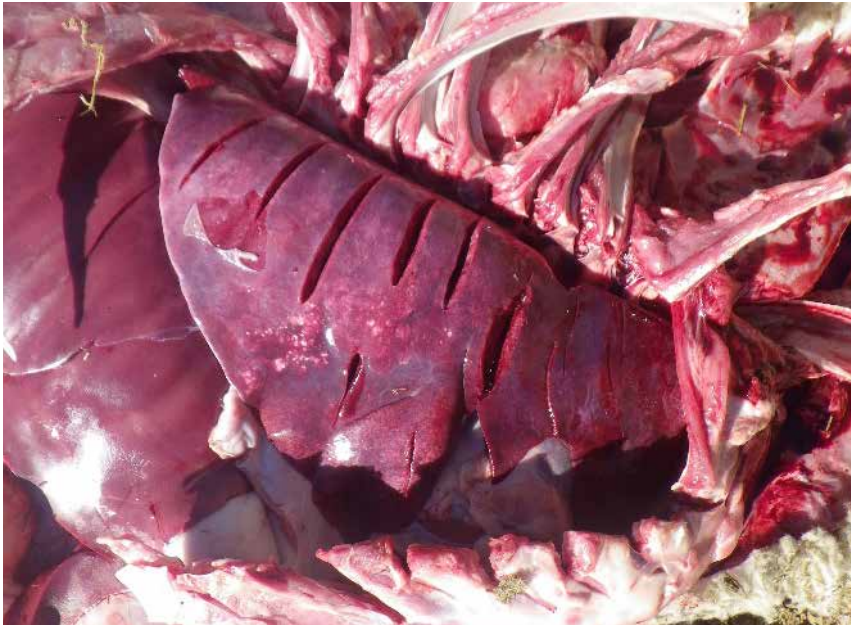

**Figure 2.6.2.**

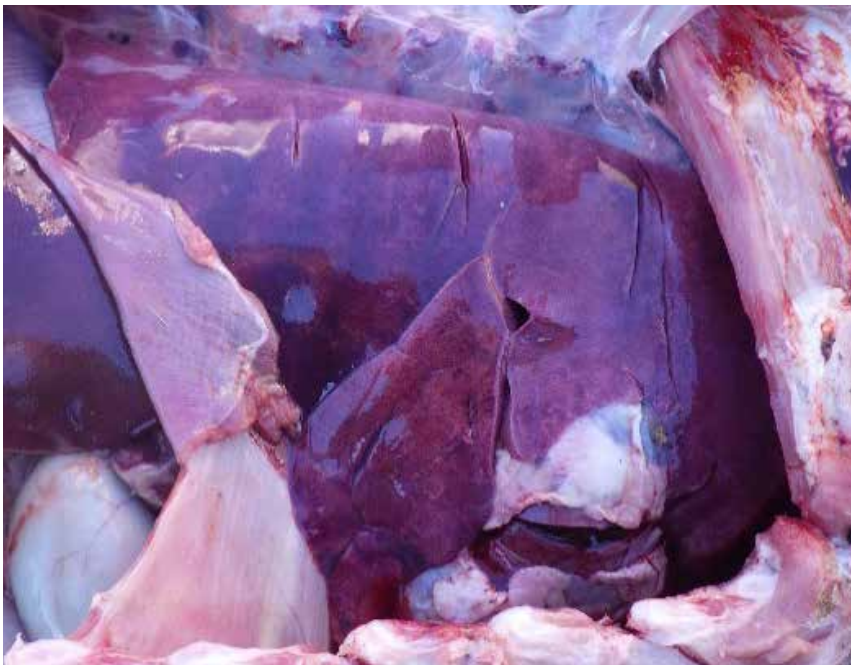Non-collapsed meaty lung  
firm to touch.







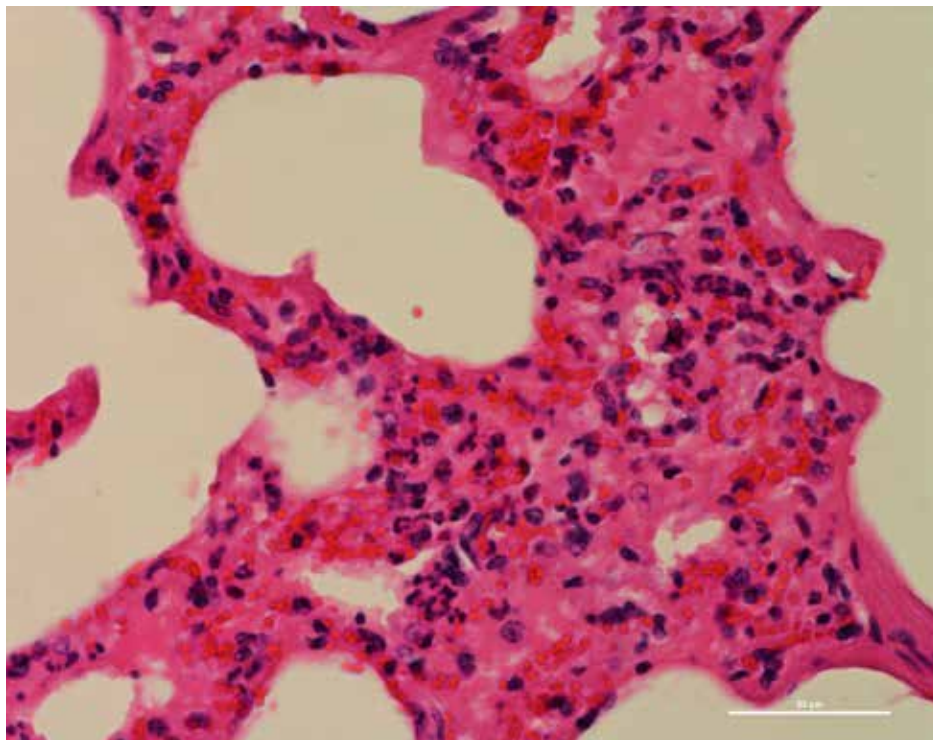
**Figure 2.6.3.**  
Meaty and non-collapsed  
lungs.



**Figure 2.6.4.**  
Non-collapsed meaty dark red  
and wet lung.

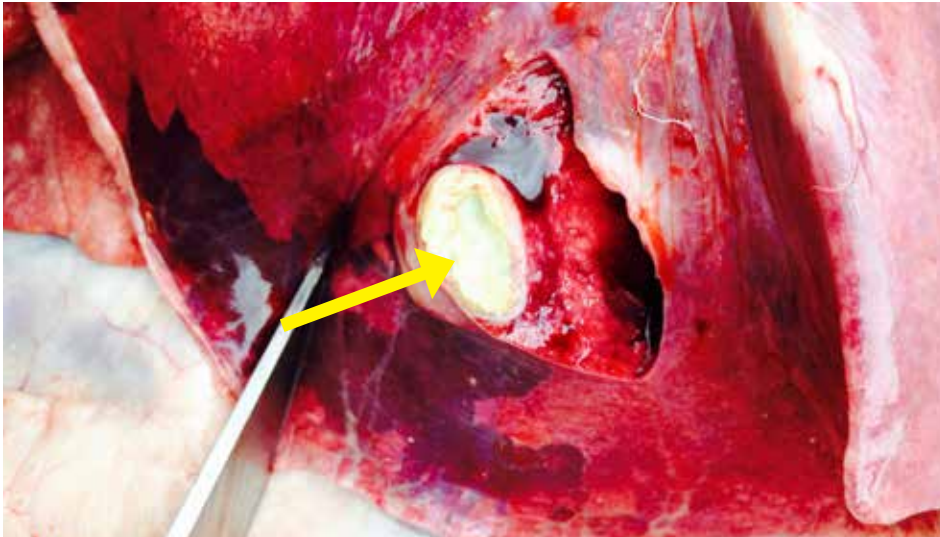
**Figure 2.6.5.**

High power view of lung from lamb (Fig. 2.6.1 & 2.6.2) showing interstitial pneumonia with alveolar wall thickening due to interstitial infiltration of mixed inflammatory cells, congested capillaries and edema consistent with bacterial septicemia. *E. coli* was isolated from the lung.



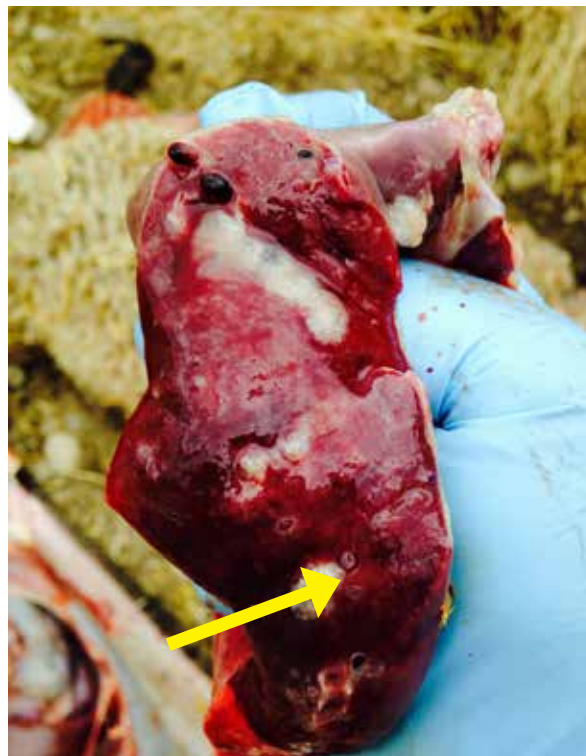## 2.7. Verminous Pneumonia

Verminous pneumonia is an infection of the lungs caused by parasites and their larval stages. *Muellariouss capillaris* and *Dictuyocaulus filaria* are the most common nematode worms that cause verminous pneumonia in sheep.



**Figure 2.7.1.**

Encapsulated cyst thought to be from migrating nematode parasite.



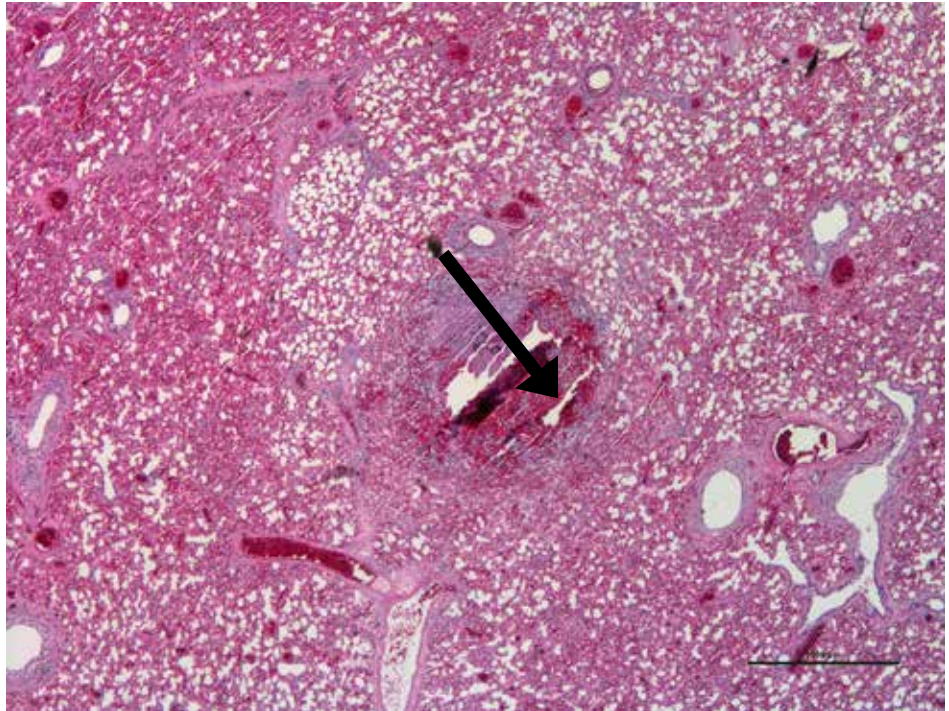
**Figure 2.7.2.**

Encapsulated cysts from migrating nematode parasite.



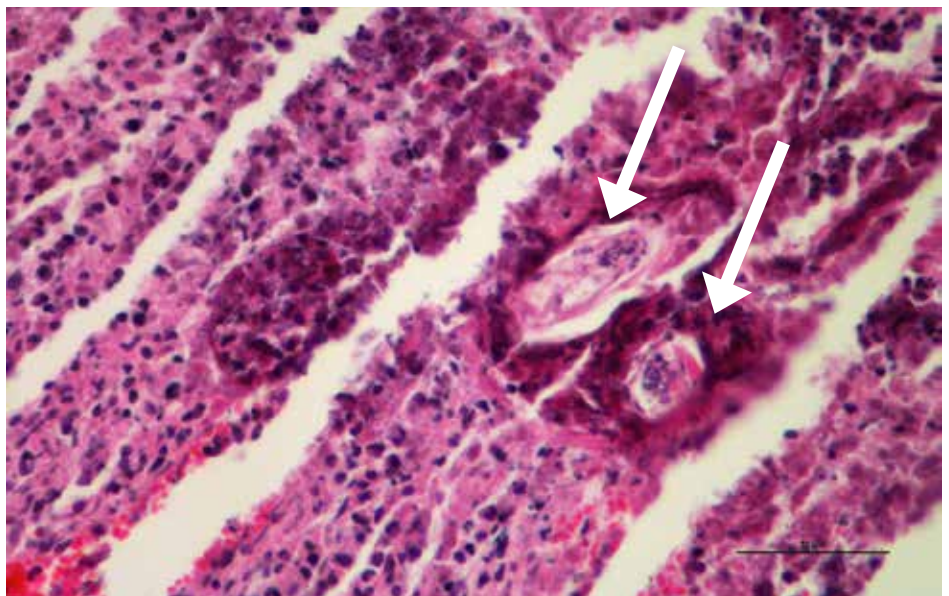
**Figure 2.7.3.**

Low power view of lung showing a focus of granulomatous pneumonia due to nematode larvae migration.



**Figure 2.7.4.**

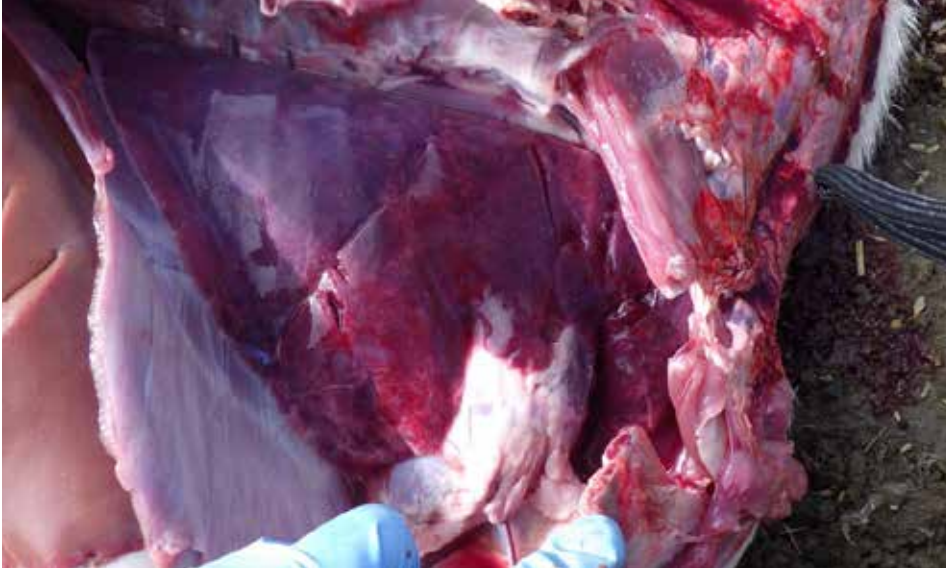
High power view of same lung showing cross sections (arrows) of nematode larvae.



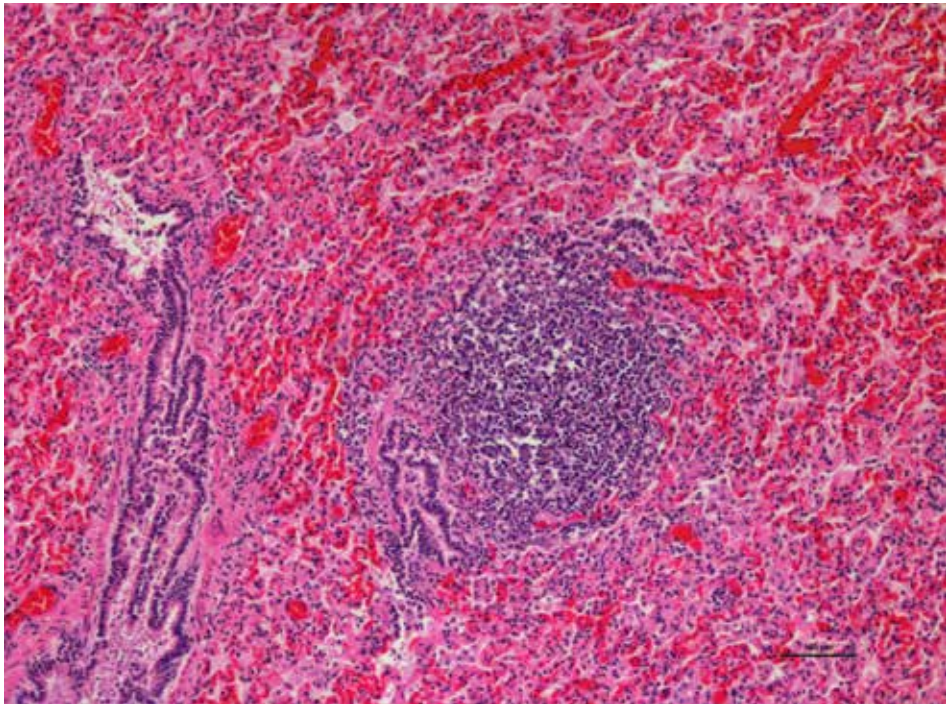


## 2.8. Chronic Bronchitis/Bronchiolitis

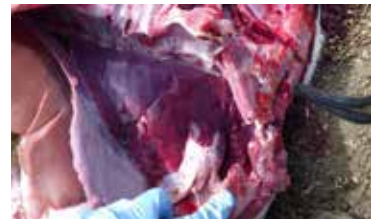Verminous pneumonia is an infection of the lungs caused by parasites and their larval stages. *Muellarioides capillaris* and *Dictyocaulus filaria* are the most common nematode worms that cause verminous pneumonia in sheep.



**Figure 2.8.1.**  
Chronic pneumonia in a lamb.

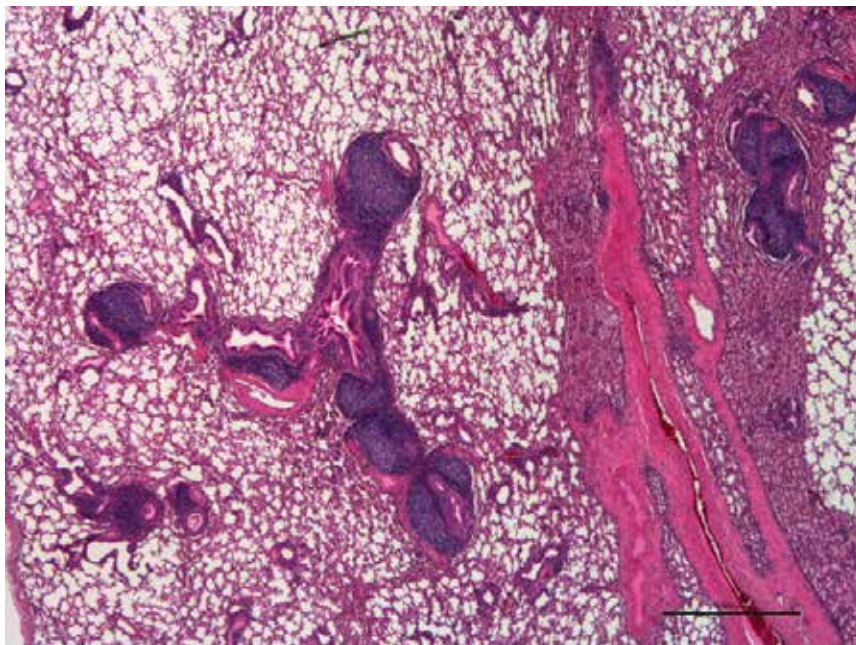


**Figure 2.8.2.**  
Lymphocytic bronchiolitis in the lung of a lamb that died due to chronic pneumonia. *Mannheimia haemolytica* and *Mycoplasma arginini* were detected in lung tissues.



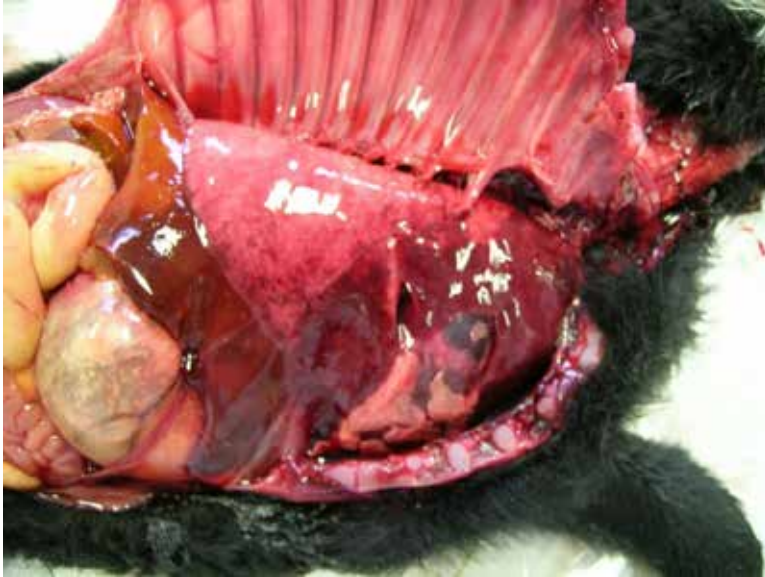**Figure 2.8.3.**

Lymphoplasmacytic bronchitis and bronchiolitis in a lamb. *P. multocida* and *Mycoplasma arginini* were detected in the lung tissues.



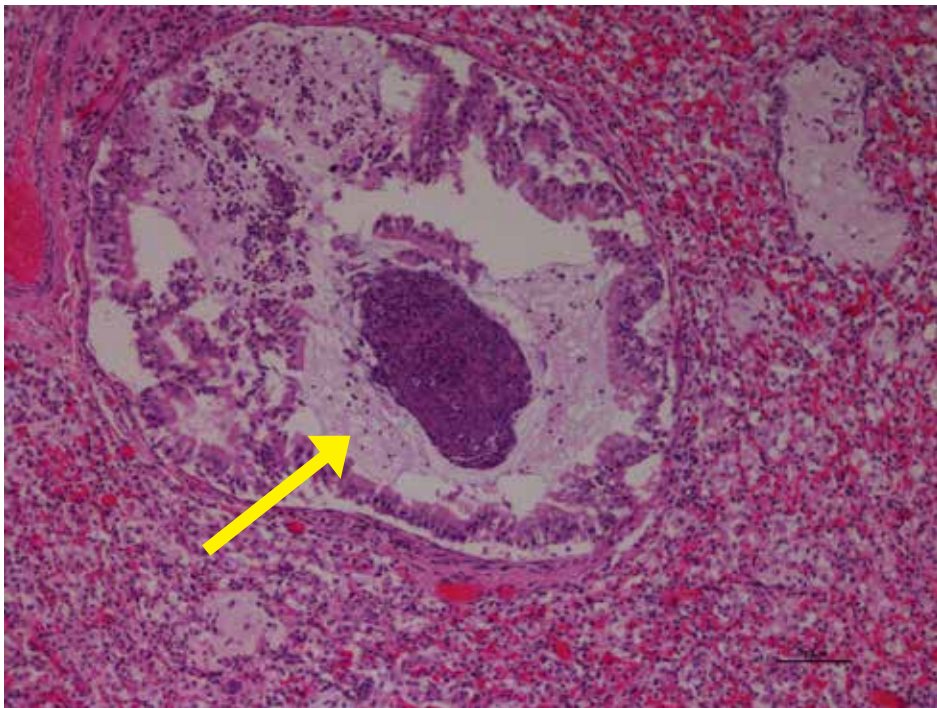


## 2.9. Aspiration Pneumonia



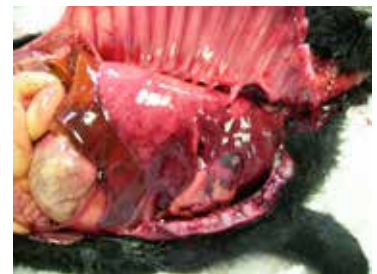**Figure 2.9.1.**

Aspiration Pneumonia is not uncommon when new born lamb is tube fed and the feeding tube is accidentally placed into the trachea. Gross exam reveals cranio-ventral consolidation of lung lobes with edema and lungs fail to collapse.



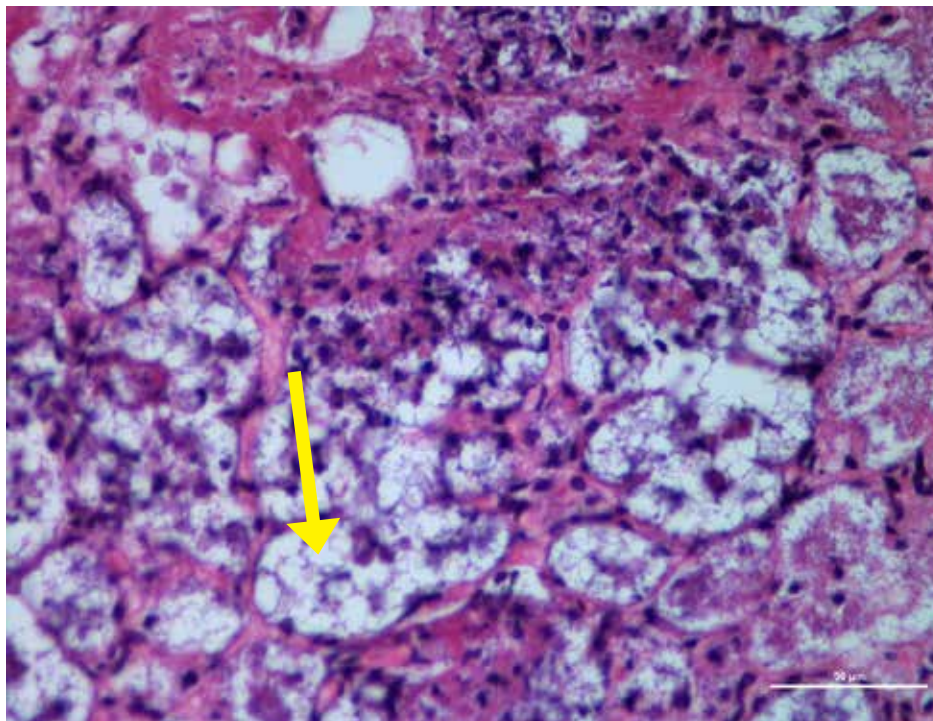
**Figure 2.9.2.**

Aspiration pneumonia in a lamb: Low power view of lung shows evidence of aspirated milk in the airways.



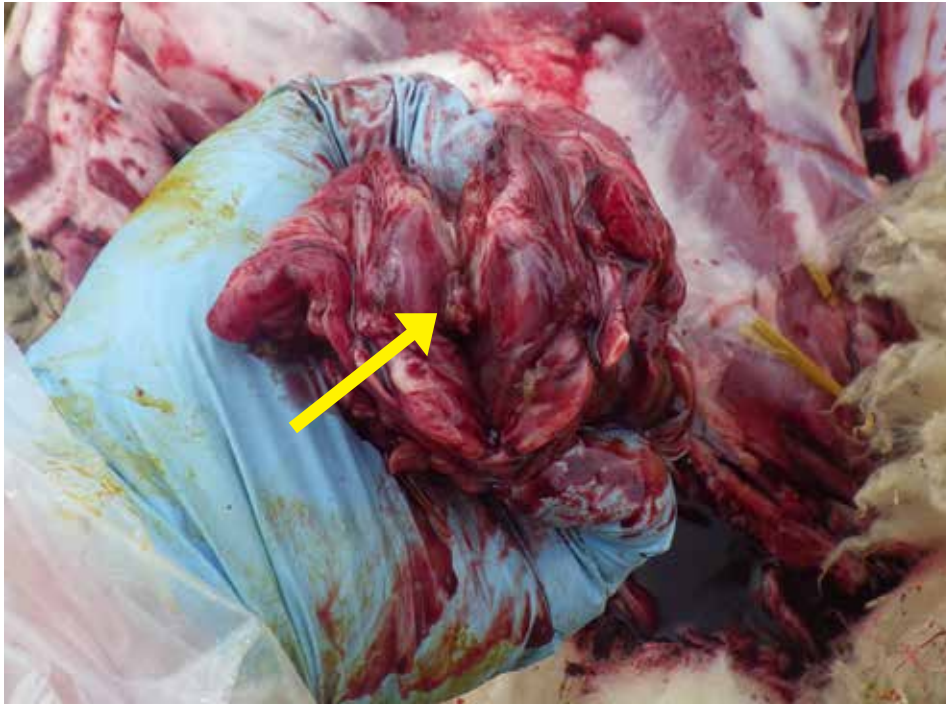
**Figure 2.9.3.**

Aspiration Pneumonia in a lamb: Histologically, high power view of alveoli showing evidence of milk fat globules (arrow) admixed with bacteria and inflammatory cells.

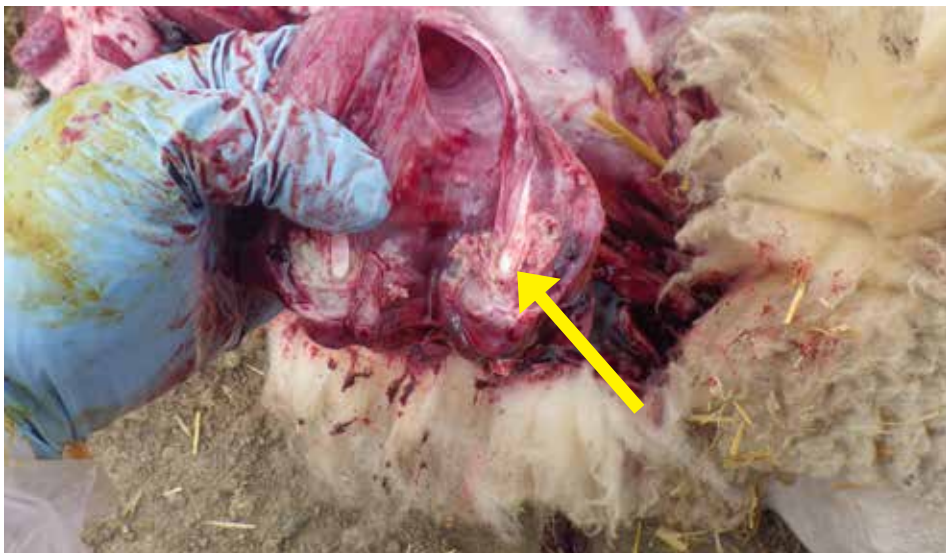




## 2.10. Necrotic Laryngitis



**Figure 2.10.1.**  
Laryngeal area. Necrotic material present.

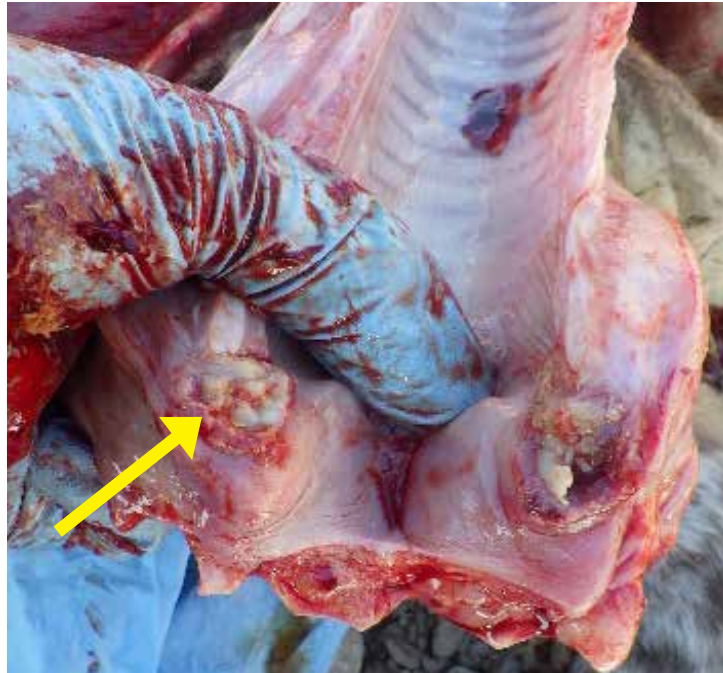


**Figure 2.10.2.**  
Necrotic tissue in laryngeal area.

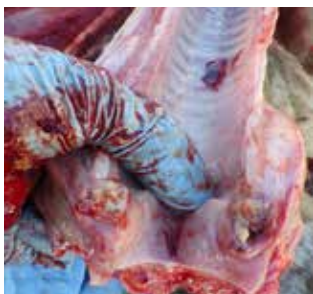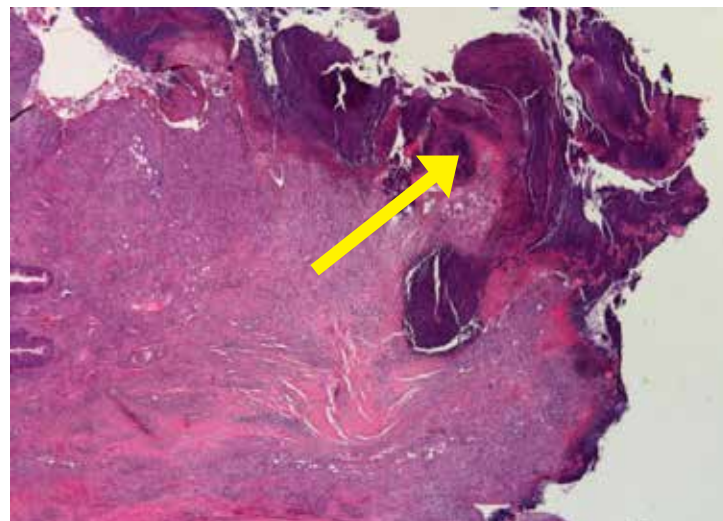


**Figure 2.10.3.**

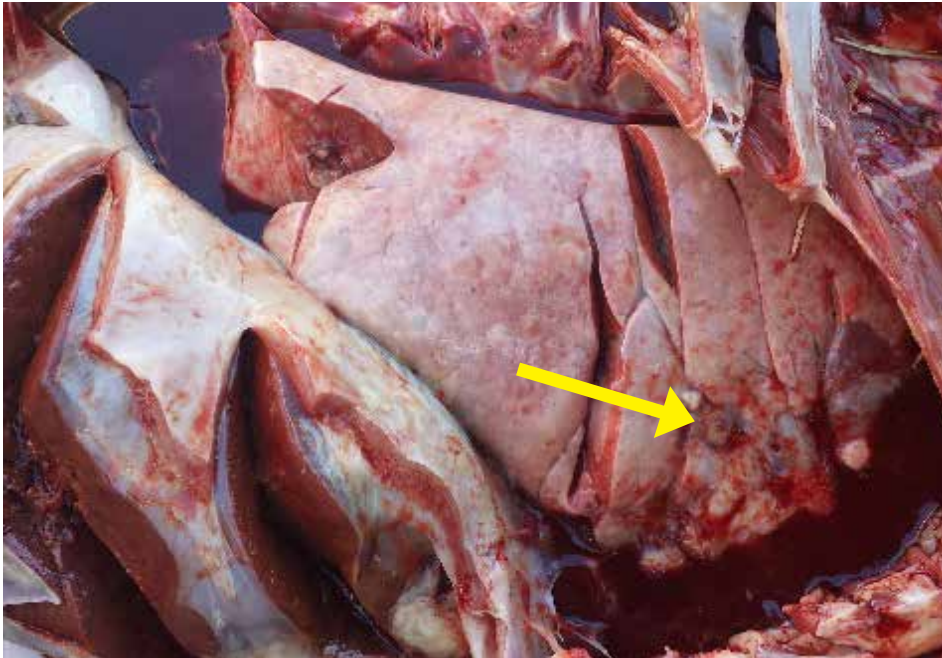
Necrotic material in larynx.

**Figure 2.10.4.**

Microscopic picture of Larynx from the same lamb showing histological evidence of severe inflammation and necrosis with intralésional bacterial colonies (arrow). Mixed bacteria including *Pasteurella multocida*, *Bibersteinia trehalosi*, few anaerobes and *Streptococcus* spp. were isolated from the larynx of this lamb.

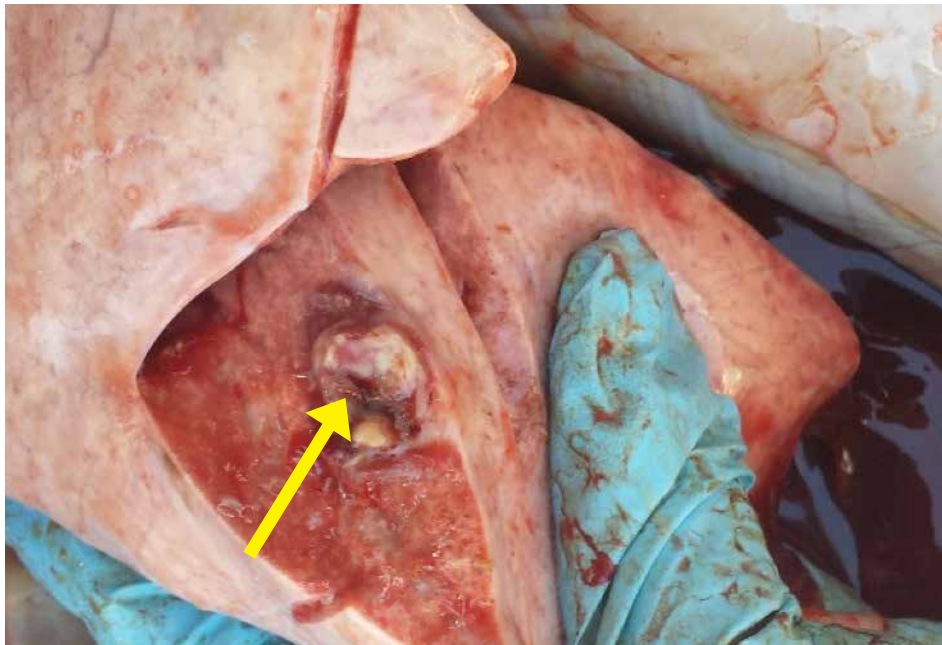


## 2.11. Pulmonary Abscessation



**Figure 2.11.1.**

Lung showing abscess (embolic from liver abscess through caudal vena cava).



**Figure 2.11.2.**

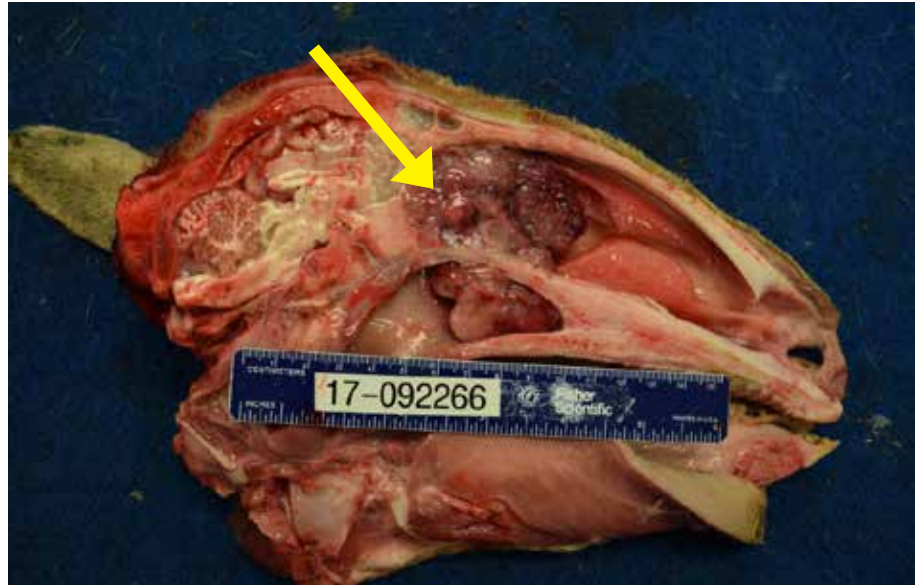
Embolic abscess in the parenchyma of lung. Originated from liver abscess.



## 2.12. Nasal adenocarcinoma

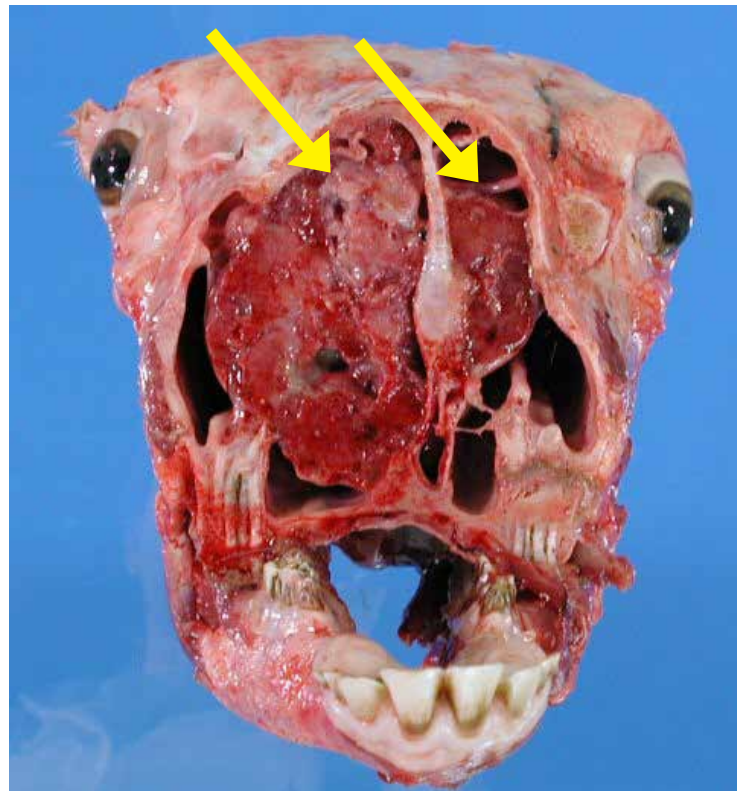
**Figure 2.12.1.**

Nasal adenocarcinoma in a sheep with nodular growths (arrow) in the nasal cavity caused by enzootic nasal tumor virus (retrovirus).  
*Photo courtesy of M. Spinato.*

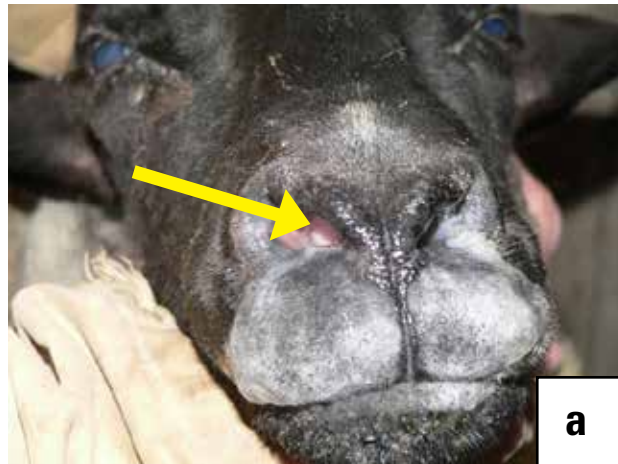

**Figure 2.12.2.**

Nasal adenocarcinoma in a sheep with bilateral nodular growths (arrows) in the nasal cavities caused by enzootic nasal tumor virus (retrovirus).  
*Photo courtesy of M. Spinato.*

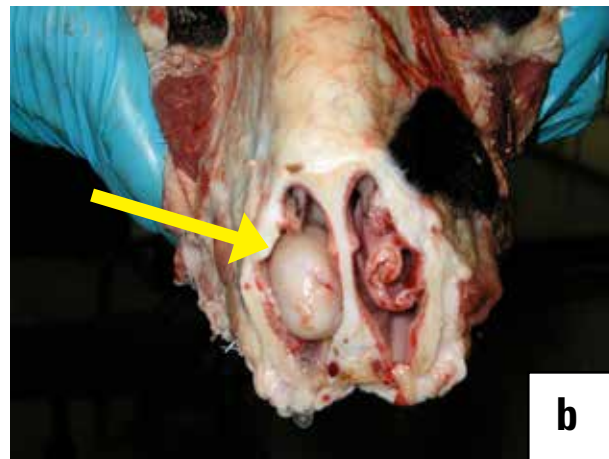






**Figure 2.13.1.a & b**

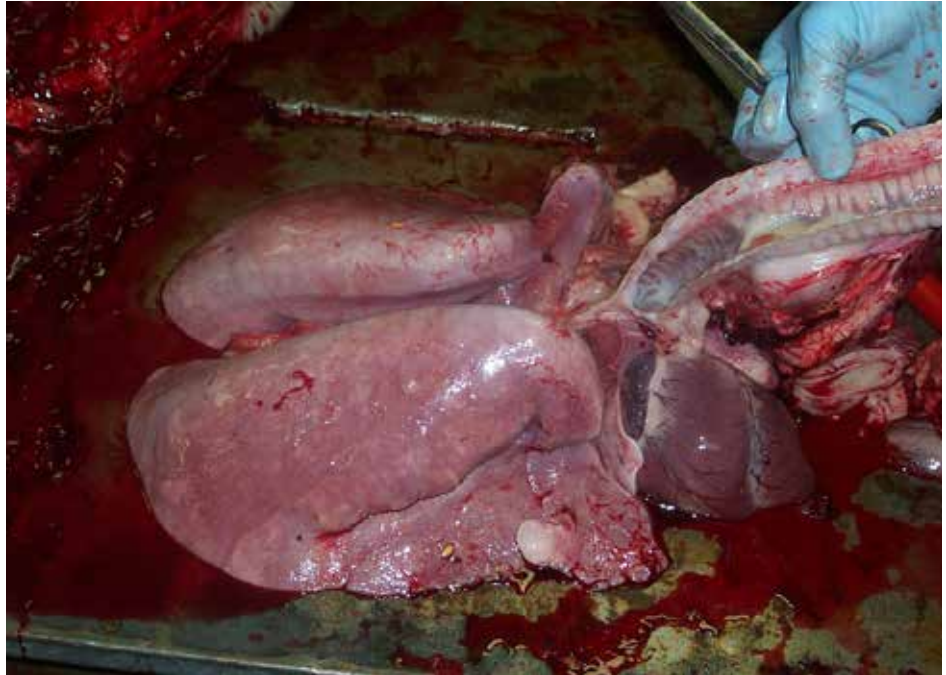
Nasal adenocarcinoma in a sheep with nodular growth grossly in the nasal cavity (arrow) caused by enzootic nasal tumor virus (retrovirus).  
*Photo courtesy of P. Menzies.*



### 2.13. Ovine Progressive Pneumonia

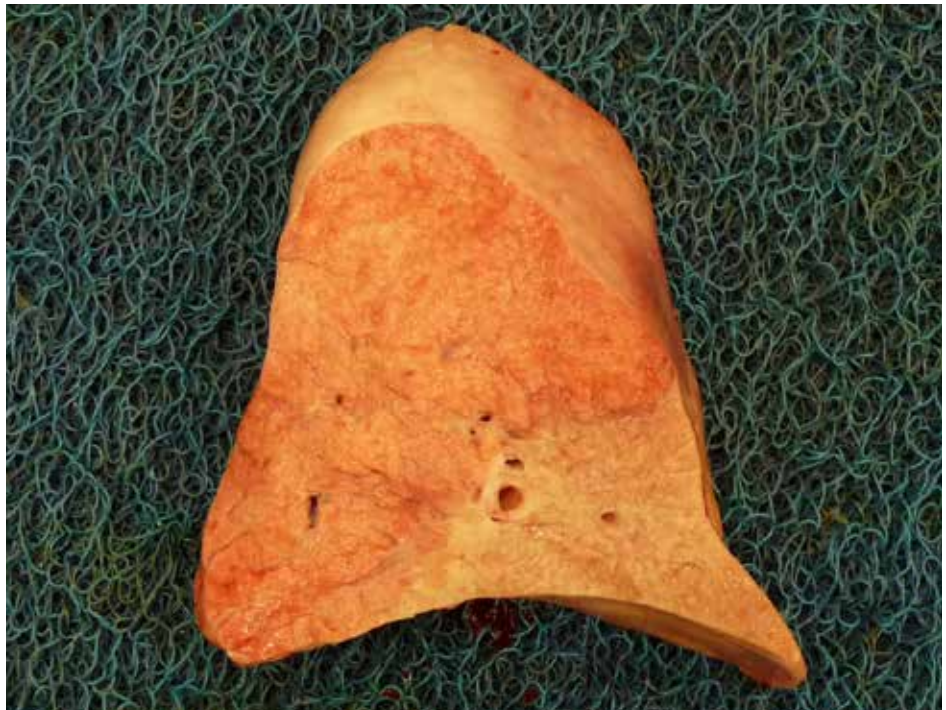**Figure 2.13.1.**

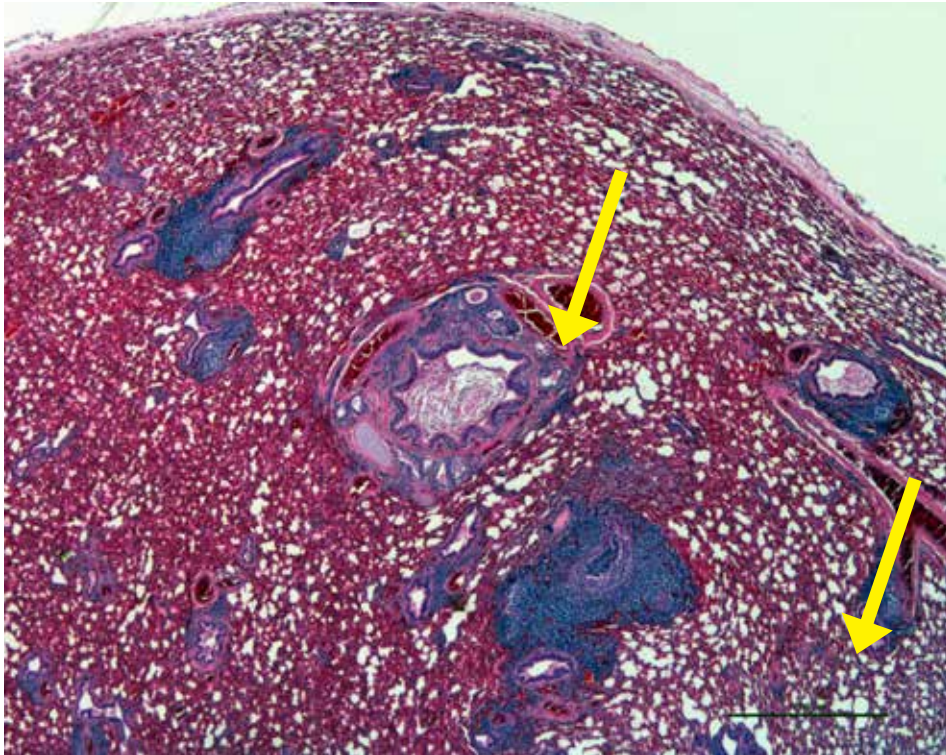
Ovine progressive pneumonia in a sheep showing firm, uncollapsed, heavy lungs due to severe pulmonary edema and interstitial pneumonia caused by lentiviruses (Retrovirus). Apart from lungs, lesions are confined to lymph nodes with enlargement.  
*Photo courtesy of P. Menzies.*



**Figure 2.13.2.**

Lungs are firm in OPP.  
*Photo courtesy of P. Menzies.*





**Figure 2.13.3.**

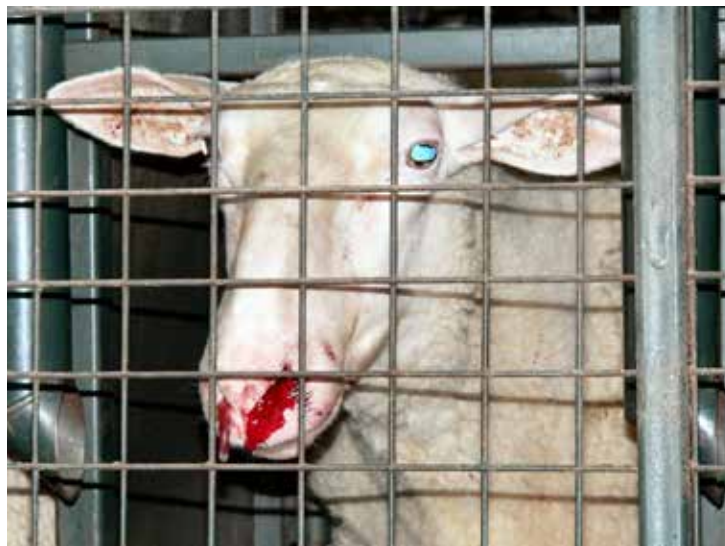Early ovine progressive pneumonia (OPP) in a yearling lamb showing microscopic evidence of chronic bronchitis and bronchiolitis with peripheral lymphoid aggregates forming lymphoid follicles and BALT hyperplasia. Lung tested positive for OPP virus and negative for Mycoplasma sp. by PCR.



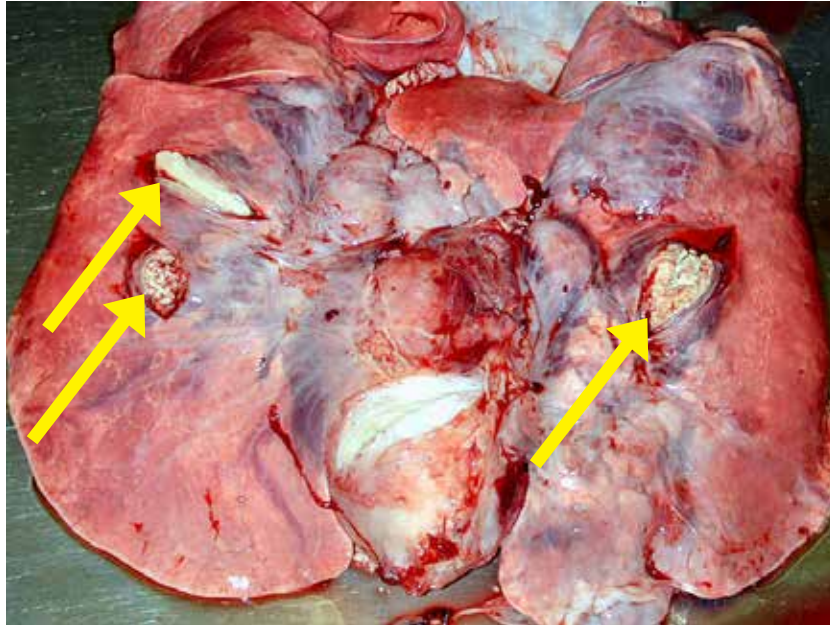
## 2.14. Nose Bleed

**Figure 2.14.1.**

Nose bleeding caused  
by *Oestrus ovis*.  
*Photo courtesy of P. Menzies.*

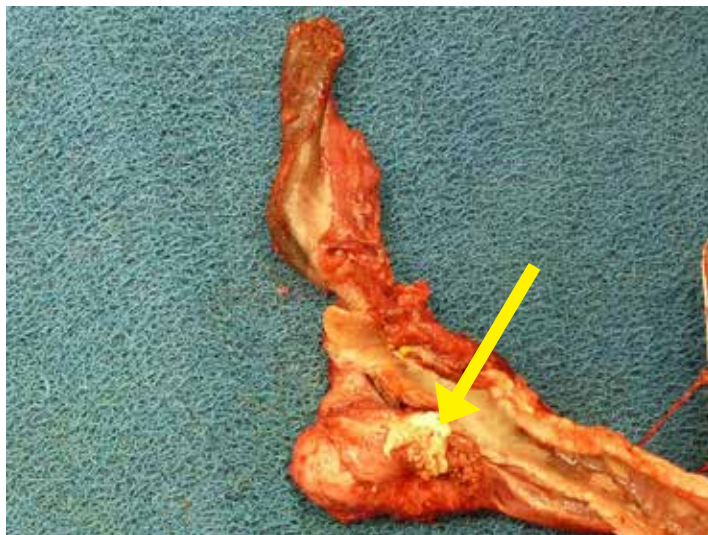

## 2.15. Caseous Lymphadenitis



**Figure 2.15.1.**

Caseous lymphadenitis (CL) in a ewe showing lung with multiple (arrows) abscesses.  
*Photo courtesy of P. Menzies.*



**Figure 2.15.2.**

Retropharyngeal abscess.  
*Photo courtesy of P. Menzies.*

### III. DISEASES OF THE GASTROINTESTINAL SYSTEM

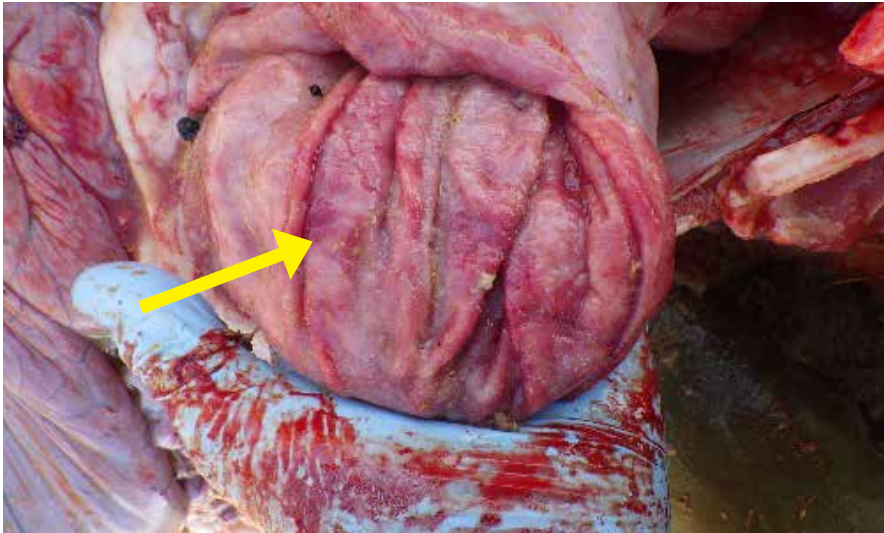
1. Abomasitis .....	92
a. Parasitic Abomasitis–Hemonchosis .....	92
b. Parasitic Abomasitis–Ostertagiasis .....	98
c. Fungal Abomasitis.....	95
d. Clostridial Abomasitis.....	96
2. Rumenitis .....	97
3. Bloat .....	102
4. Coccidiosis .....	104
5. Bacterial Septicemia.....	109
6. Enteritis and Enterotoxaemias.....	112
7. Johne’s Disease .....	116
8. Inguinal Hernia.....	120
9. Intussusception.....	121
10. Intestinal torsion.....	123
11. Peritonitis.....	124
12. Hardware Disease (Reticuloperitonitis) .....	126
13. Tapeworm Infestation.....	127
14. Rectal Prolapse.....	129



### III. DISEASES OF THE RESPIRATORY SYSTEM

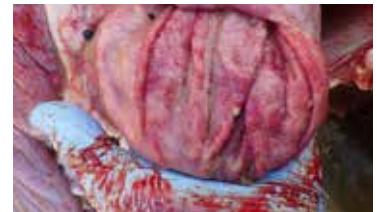#### 3.1. Abomasitis

##### 1a. Parasitic Abomasitis—Hemonchosis



**Figure 3.1.1.**

Abomasitis in a lamb. Note the red rough pitted surface and swollen folds of the abomasum most likely caused by chronic abomasal parasitism.

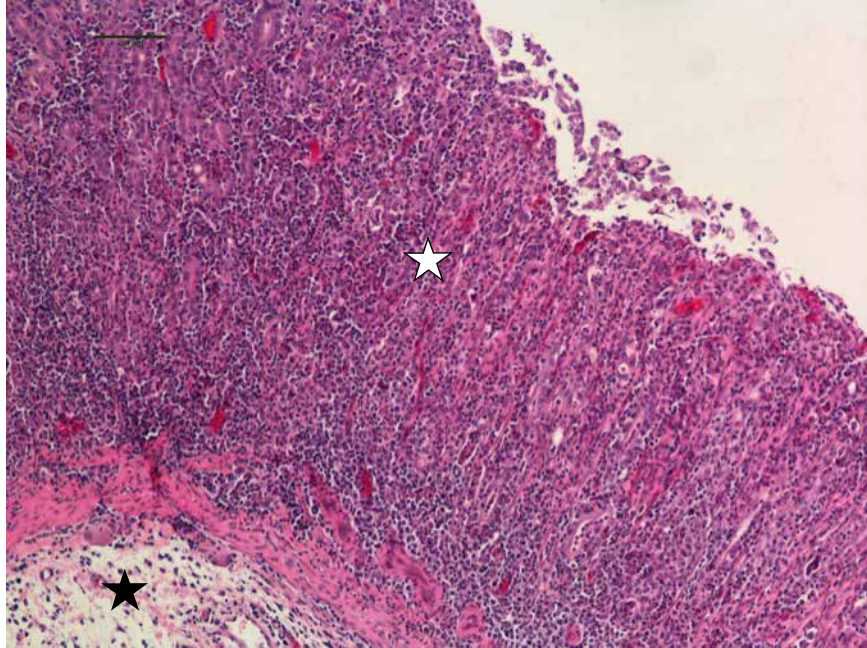


**Figure 3.1.2.**

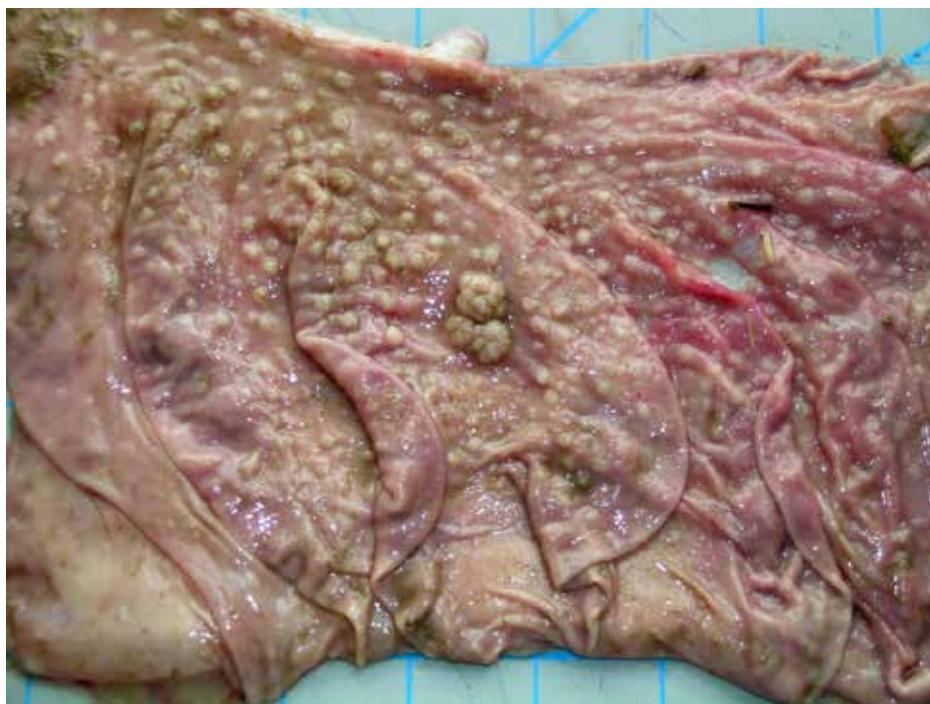Abomasum showing many *Haemonchus contortus* parasites.

**Figure 3.1.3.**

Abomasum from a lamb infested with *Haemonchus* showing mucosa is infiltrated with large numbers of mixed inflammatory cells (white star) and edema (dark star).



### 1b. Parasitic Abomasitis –Teladorsagiasis



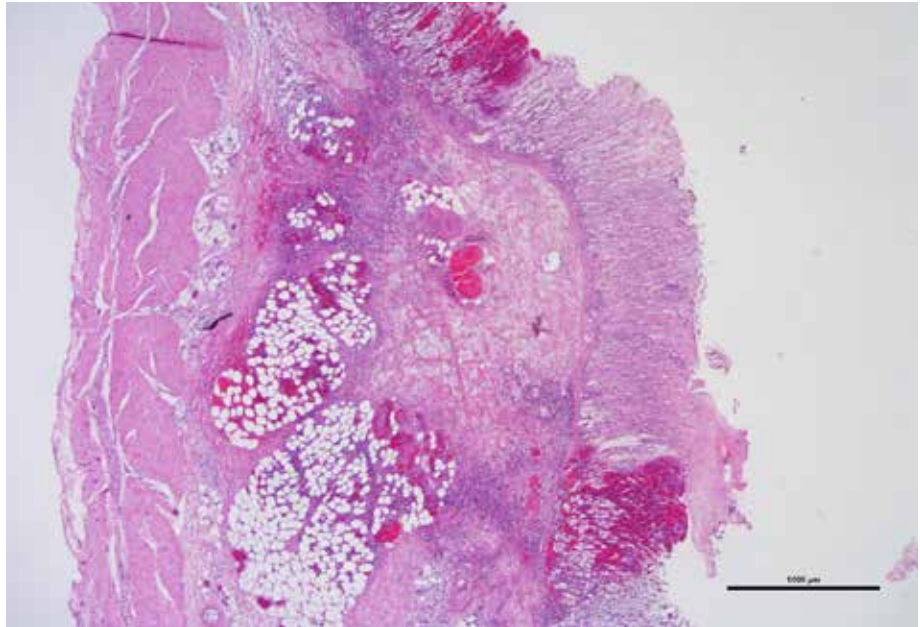
**Figure 3.1.4.**

Abomasum from a sheep showing raised nodules on the mucosal surface with Moroccan leather appearance due to development of *Teladorsagia sp.* larvae in the gastric glands causing hypertrophic and hyperplastic abomasitis. Affected animals typically have impaired digestion resulting in poor weight gain or weight loss, diarrhea and dehydration.

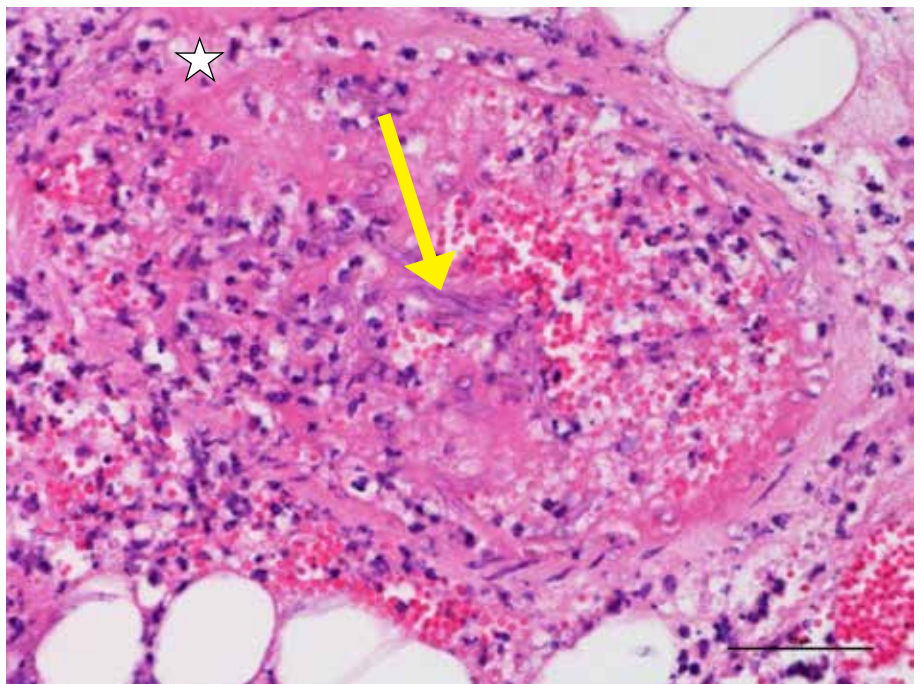


**1c. Fungal Abomasitis****Figure 3.1.5.**

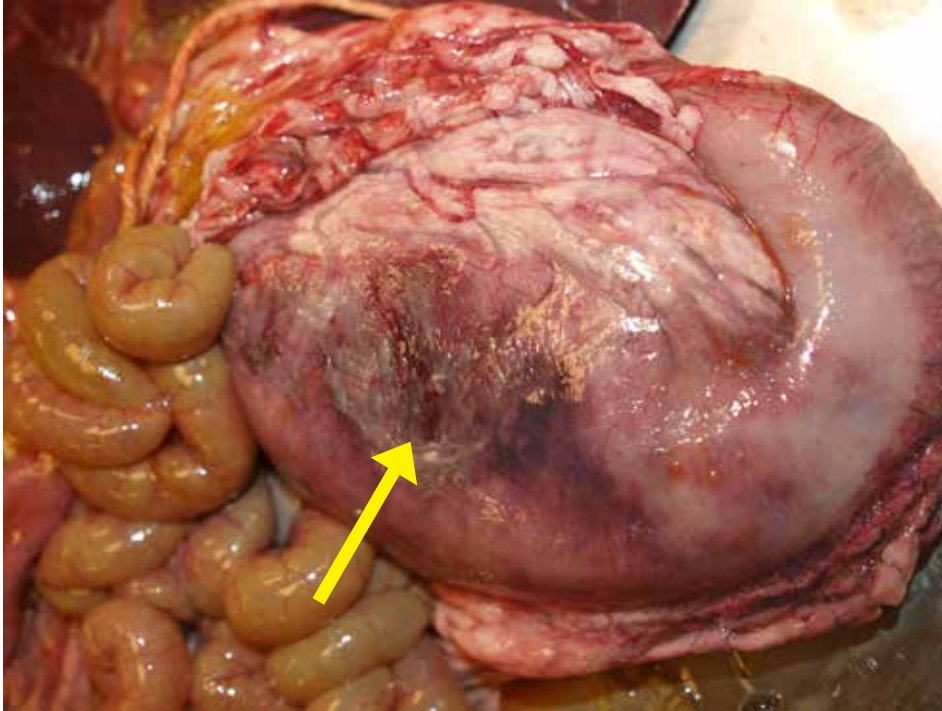
Fungal abomasitis in a lamb:  
Fungal invasion of forestomachs is not uncommon presentation in animals with rumen acidosis resulting in fungal rumenitis, abomasitis and enteritis.

**Figure 3.1.6.**

Fungal abomasitis: Fungal (arrow) invasion of blood vessel (star) in the mucosa causing vasculitis, thrombosis and infarction of the affected portion of the abomasum. Similar lesions were seen in rumen and intestines multifocally.

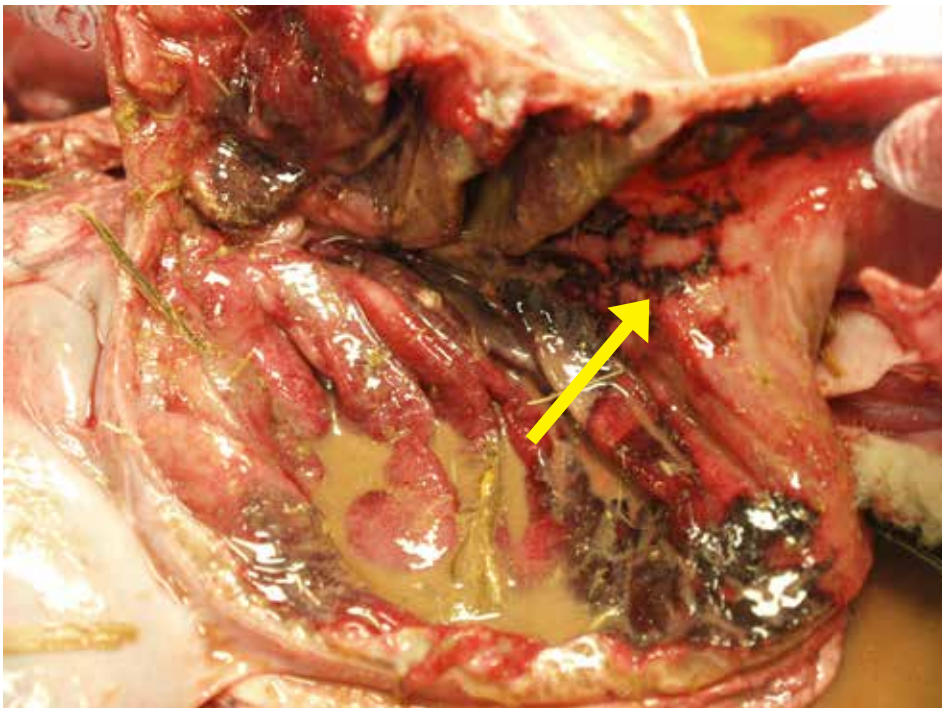


### 1d. Clostridial Abomasitis



**Figure 3.1.7.**

Abomasitis due to clostridial infection. Most common bacterial agents are *C. septicum*, *C. perfringens* type A, *C. sordellii*, and *Sarcina spp*, or a combination of these agents. Notice fibrin and reddened damaged surface of abomasum (arrow).  
*Photo courtesy of P. Menzies.*



**Figure 3.1.8.**

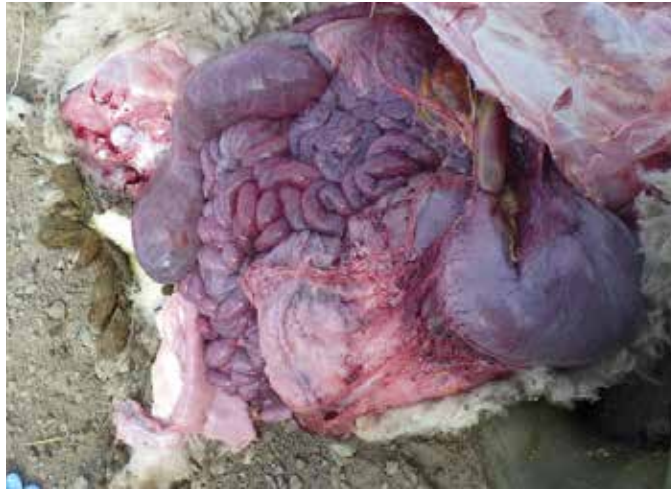
Inside of abomasum showing rough surface with reddened depressed necrotic areas (arrow) from clostridial infection.  
*Photo courtesy of P. Menzies.*



### 3.2. Rumenitis

**Figure 3.2.1.**

Congested hemorrhagic abomasum, rumen and intestines in severe grain overload.



**Figure 3.2.2.**

Severely reddened hemorrhagic rumen in severe grain overload.

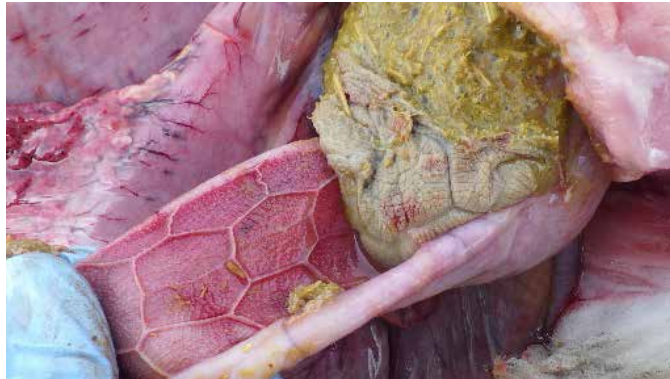

**Figure 3.2.3.**

This lamb grossly had rumenitis with sour-smelling content. Note the engorged blood vessels and red lining of the rumen.

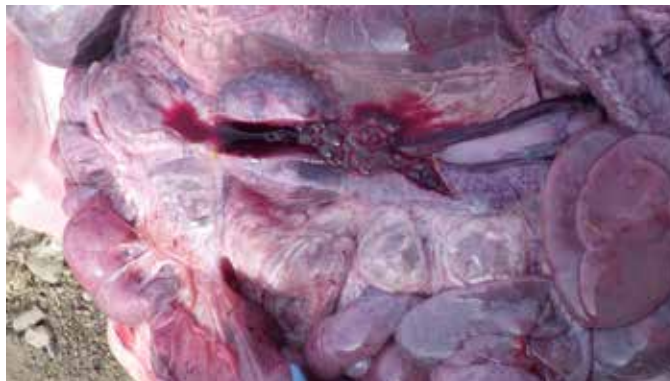






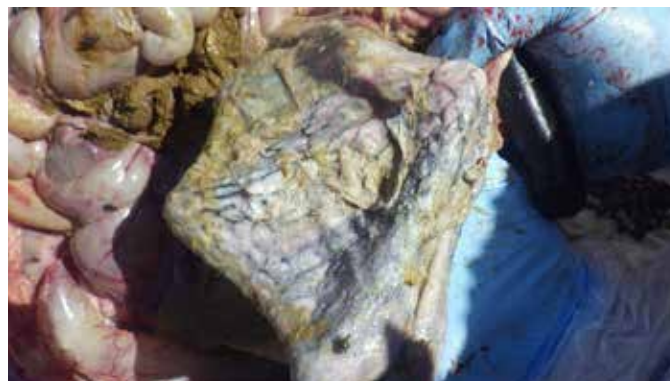**Figure 3.2.4.**

Reticulum also very reddened in severe grain overload.



**Figure 3.2.5.**

Intestine full of hemorrhagic intestinal content with severe grain overload.




**Figure 3.2.6.**

The lining of the rumen has necrotic material on its surface observed in chronic rumenitis with secondary fungal infection.

**Figure 3.2.7.**

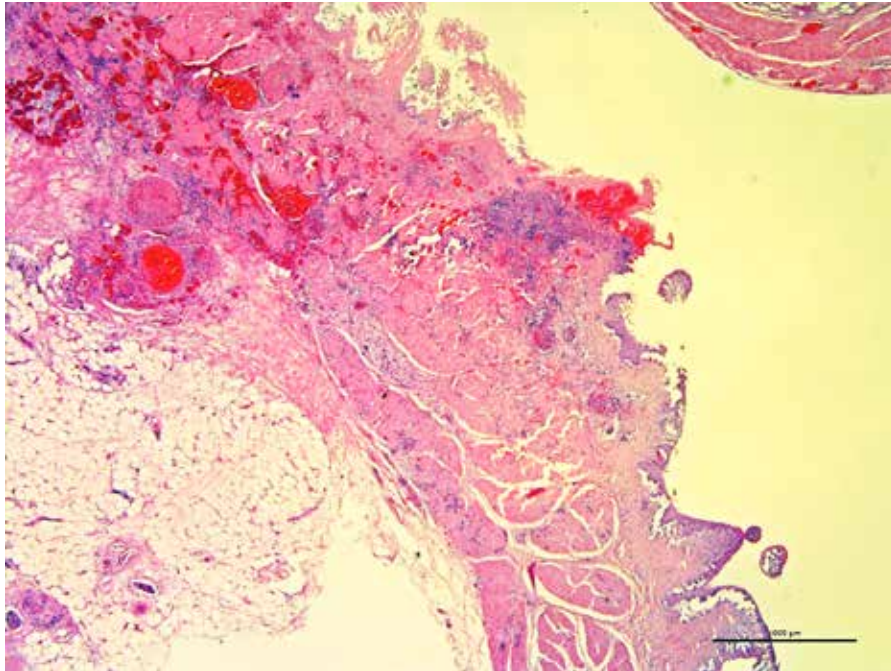
Stellate scarring from a previous episode of rumenitis caused by grain overload.



**Figure 3.2.8.**

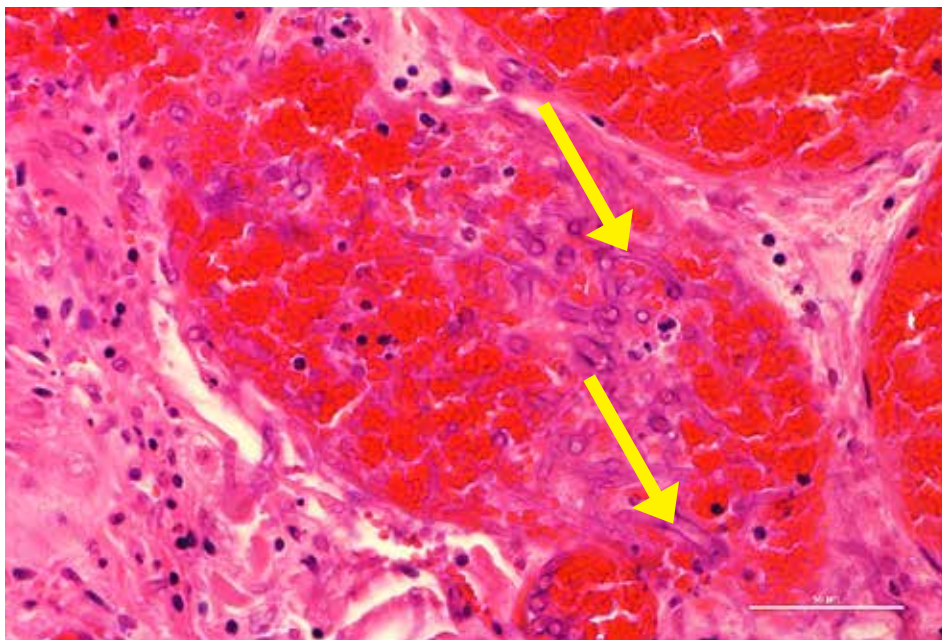
Severe, chronic rumenitis with ulceration.





**Figure 3.2.9.**

Hemorrhagic and necrotizing fungal rumenitis in a lamb. Fungal invasion of the rumen is not an uncommon presentation in animals with ulcers in rumen following acute acidosis.



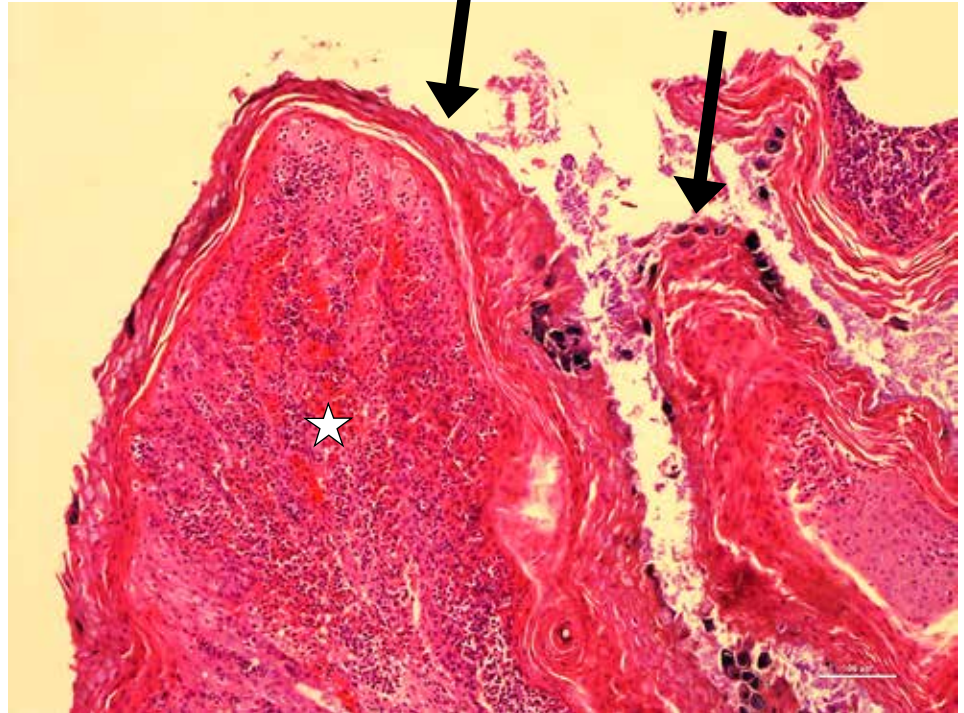
**Figure 3.2.10.**

High power view of fungal rumenitis showing fungal invasion (arrows) of blood vessel. Mucor/Aspergillus species of fungus are commonly involved.



**Figure 3.2.11.**

Chronic rumenitis caused by acidosis in a lamb showing thickened rumen papilla due to hyperplastic and keratinized epithelium (arrows) and the stroma (star) is infiltrated with mixed inflammatory cells.



### 3.3. Bloat



**Figure 3.3.1.**

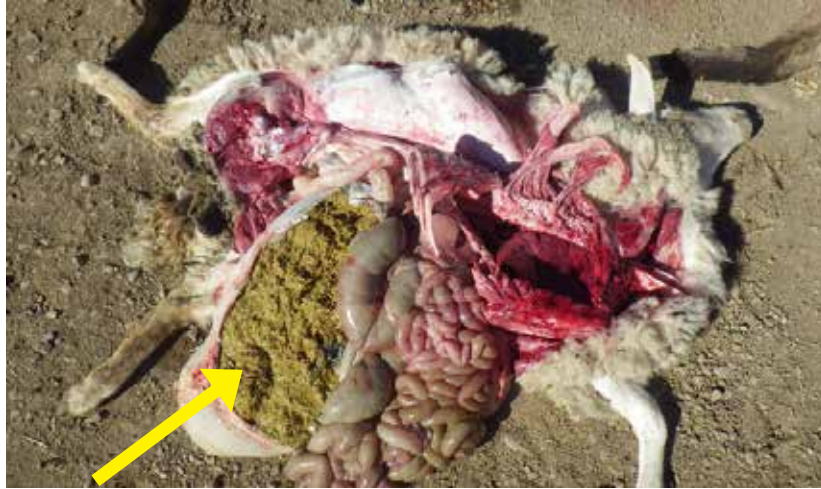Young lamb with ruminal and abomasal bloat (distended left side of belly).

*Photo courtesy of  
Dr. Paula Menzies.*



**Figure 3.3.2.**

Frothy bloat in a sheep showing distended rumen with frothy contents particularly when their feed is switched abruptly to alfalfa hay.



**Figure 3.3.3.**

Frothy feed within rumen of a sheep that died due to frothy bloat.





### 3.4. Coccidiosis



**Figure 3.4.1.**

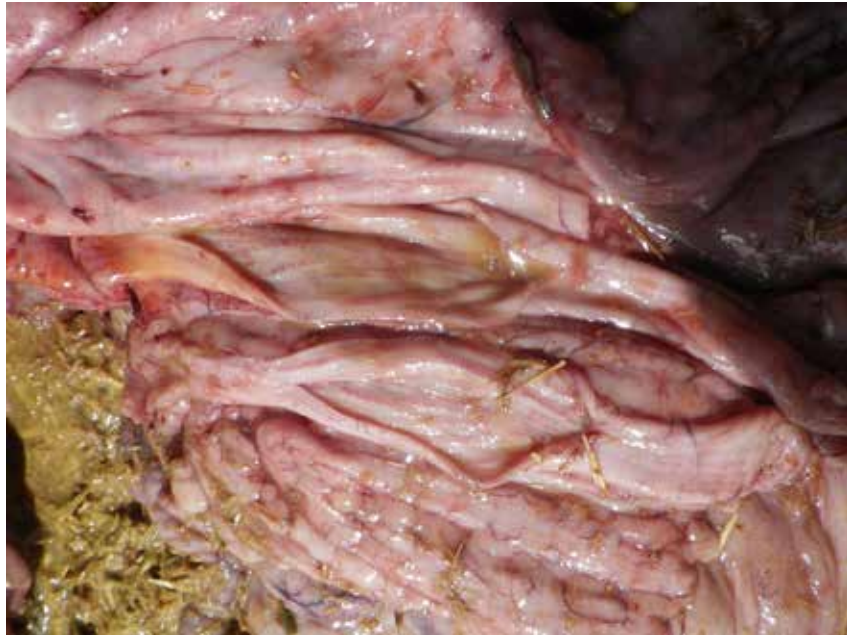Lambs with fecal staining from coccidiosis due to *Eimeria ovinoidalis*.

*Photos courtesy of Dr. Paula Menzies.*



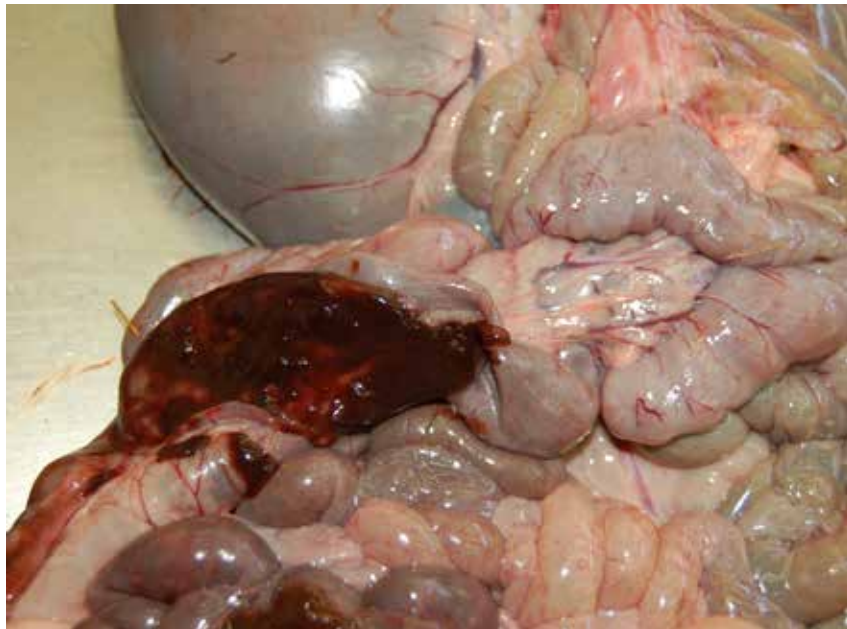
**Figure 3.4.2.**

Rectum thickened with some bloody content.

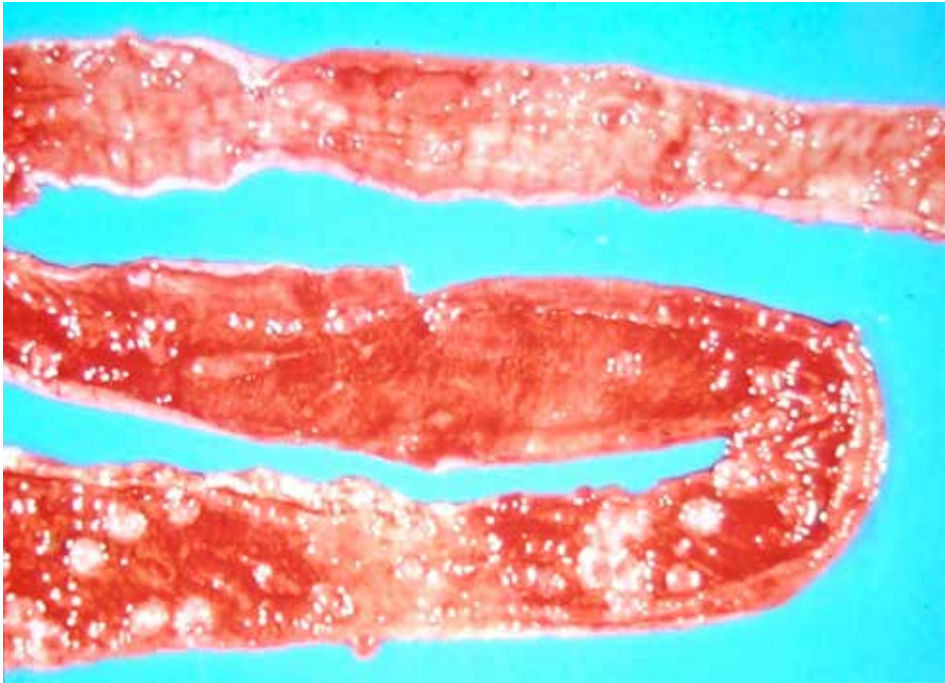


**Figure 3.4.3.**

Coccidiosis in a lamb showing the intestine with bloody content.  
*Photo courtesy of P. Menzies.*

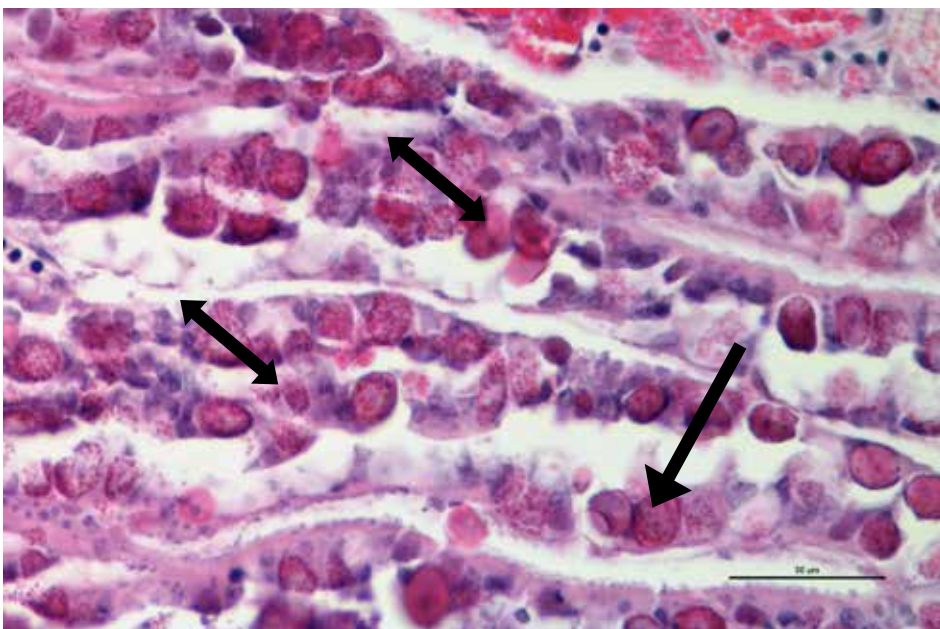






**Figure 3.4.4.**

Coccidiosis in a lamb showing hemorrhagic mucosal surface of small intestine. Microscopic examination of mucosal smears and sections of small intestine can help to confirm diagnosis.



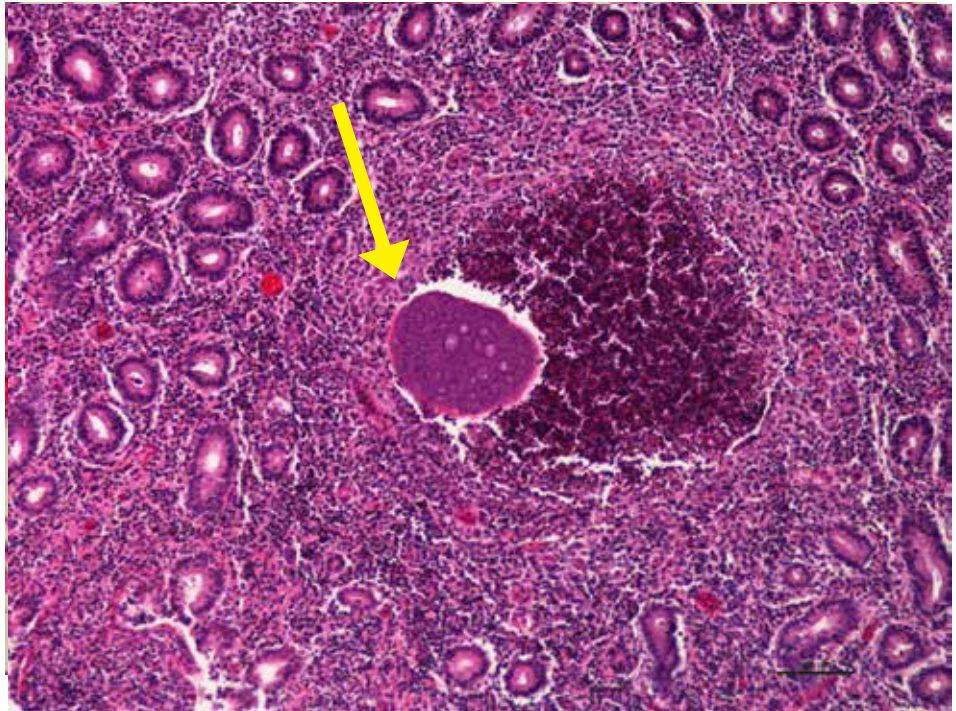
**Figure 3.4.5.**

Coccidiosis in a lamb showing small intestine infested with coccidial stages (dark double headed arrows). Also notice *Cryptosporidium parvum* infection in this lamb (single headed arrows).

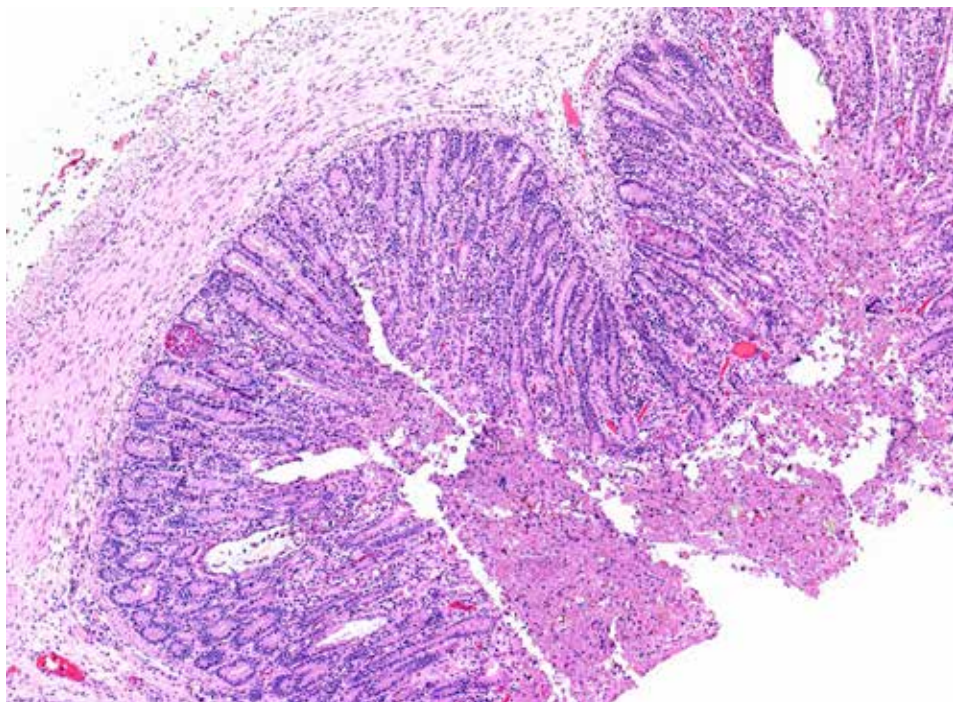


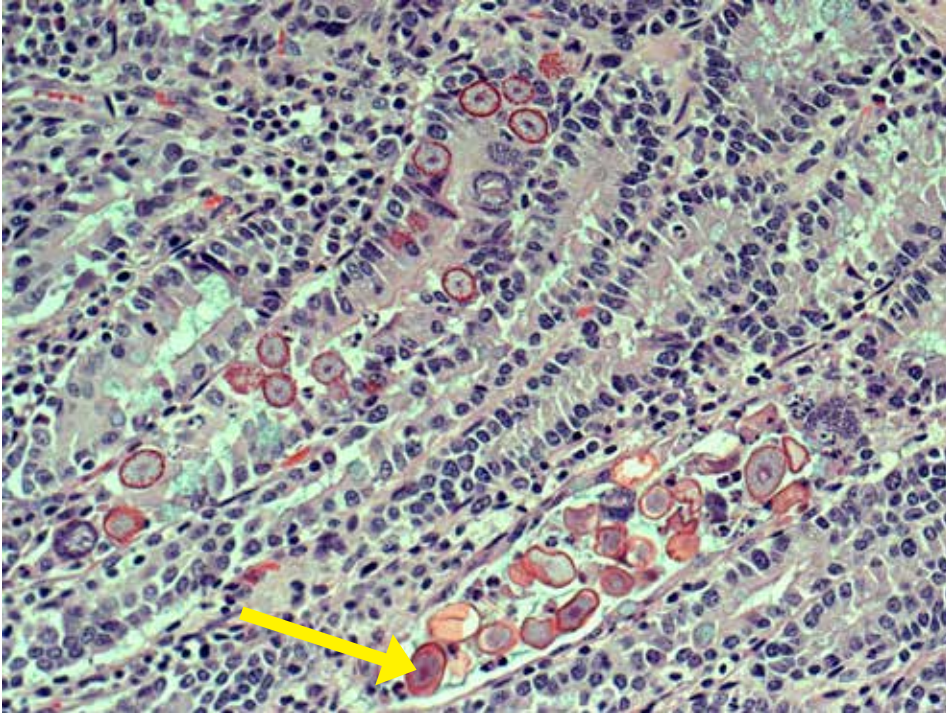
**Figure 3.4.6.**

Chronic enteritis in a lamb showing coccidial stage (meront) deep in the mucosa of small intestine with severe inflammation.

**Figure 3.4.7.**

Coccidiosis – 4X. Note the dilated glands lined by eroded epithelium and intraepithelial macrogamonts. Mucosa is covered with sloughed cellular debris and oocysts. *Photo courtesy of M. Spinato.*





**Figure 3.4.8.**

Coccidiosis – 20X.  
Numerous macrogamonts,  
microgametocytes and  
coccidial oocysts are present  
within epithelial cells lining  
colonic glands. Arrow pointing  
to parasite stages in the lumen  
of a colonic gland.

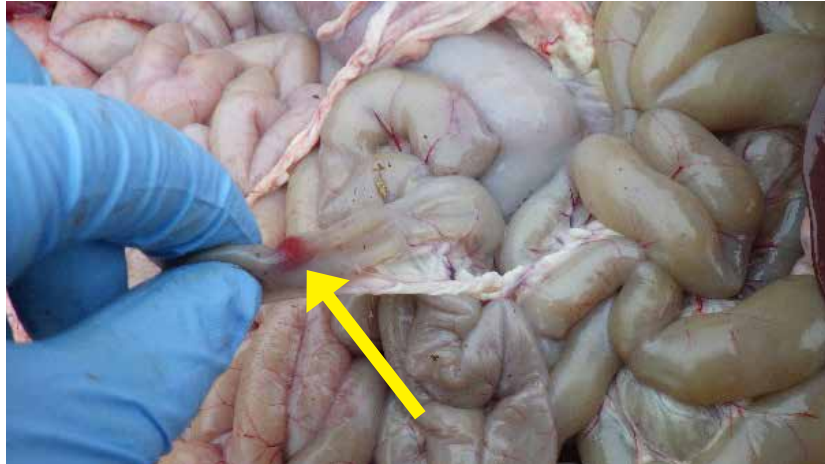
*Photo courtesy of M. Spinato.*



### 3.5. Bacterial Septicemia

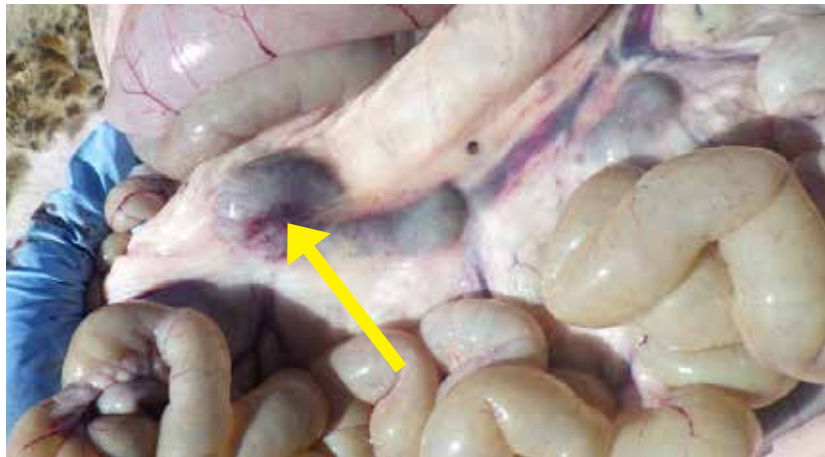**Figure 3.5.1.**

Note small hemorrhage observed in serosal surface of small intestine. This can be observed in septicemia.

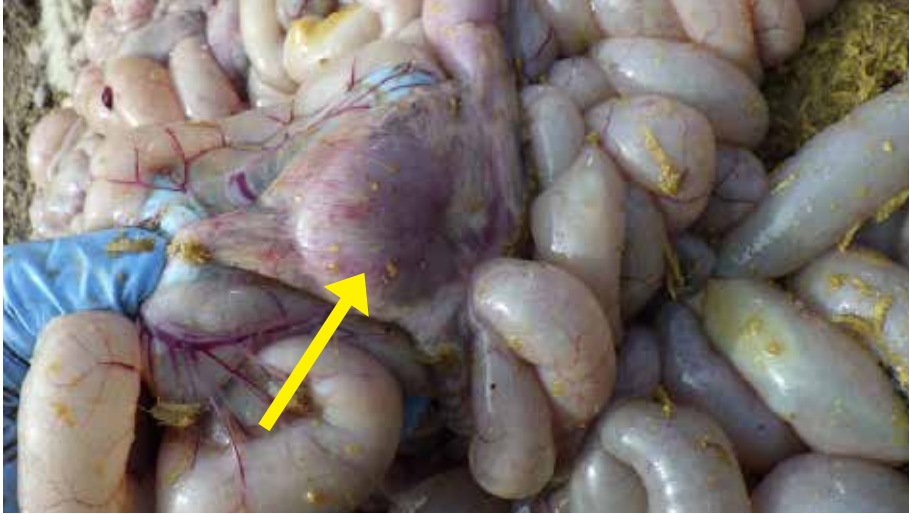

**Figure 3.5.2.**

Reactive mesenteric lymph nodes are commonly observed in animals diagnosed with septicemia.

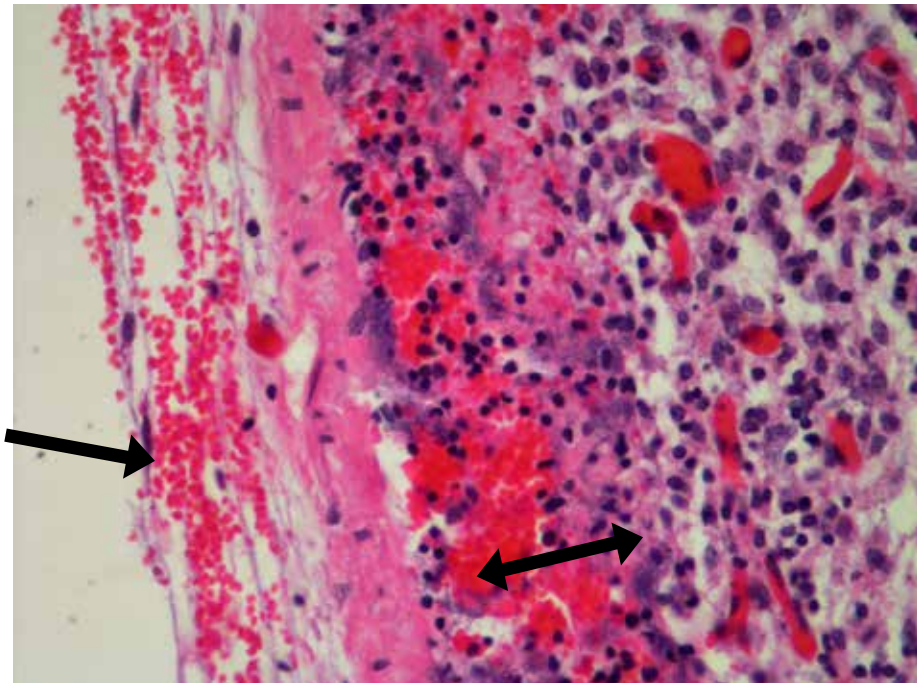






**Figure 3.5.3.**

Reactive mesenteric lymph nodes are commonly observed in animals diagnosed with septicemia.



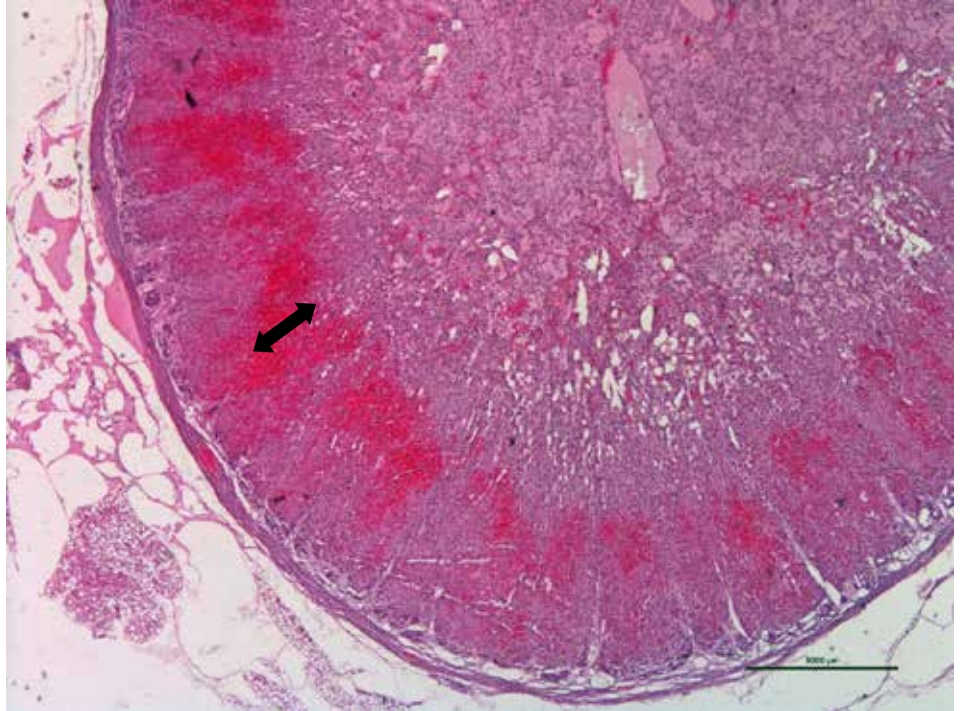
**Figure 3.5.4.**

Mesenteric lymph node from a lamb that died due to bacterial septicemia showing hemorrhage in the capsule and sinus (red cells) and bacterial colonies. Multisystemic showering of bacterial colonies noted in this animal. Pure culture of *E. coli* was isolated from lung and liver.

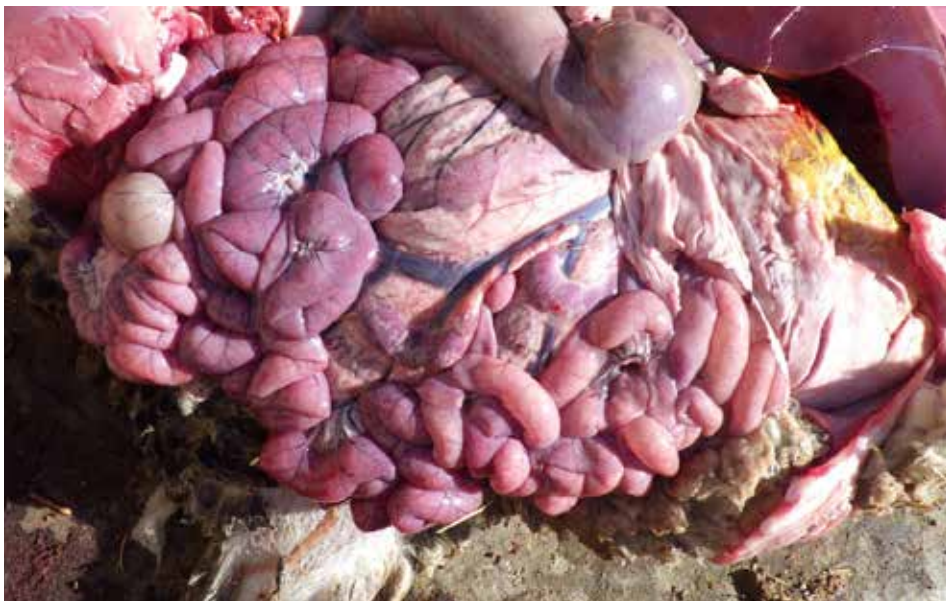**Figure 3.5.5.**

Adrenal gland from a lamb that died due to bacterial septicemia showing hemorrhages in the cortex (double headed arrow).

It is also called as Waterhouse-Friderichsen syndrome, lesions commonly seen in overwhelming septicemia in animals.

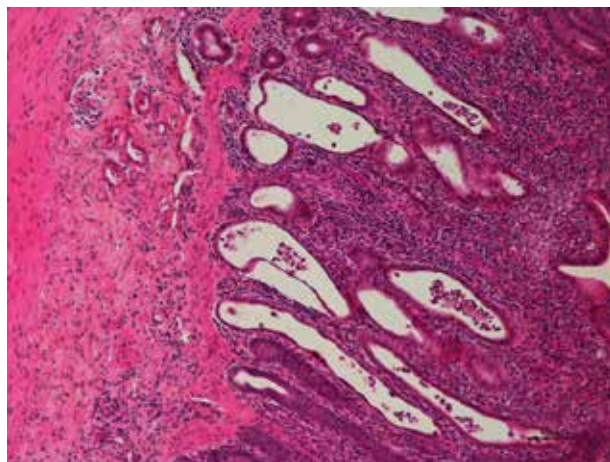


### 3.6. Enteritis



**Figure 3.6.1.**

Dilated enlarged reddened loops of intestine observed in enteritis.



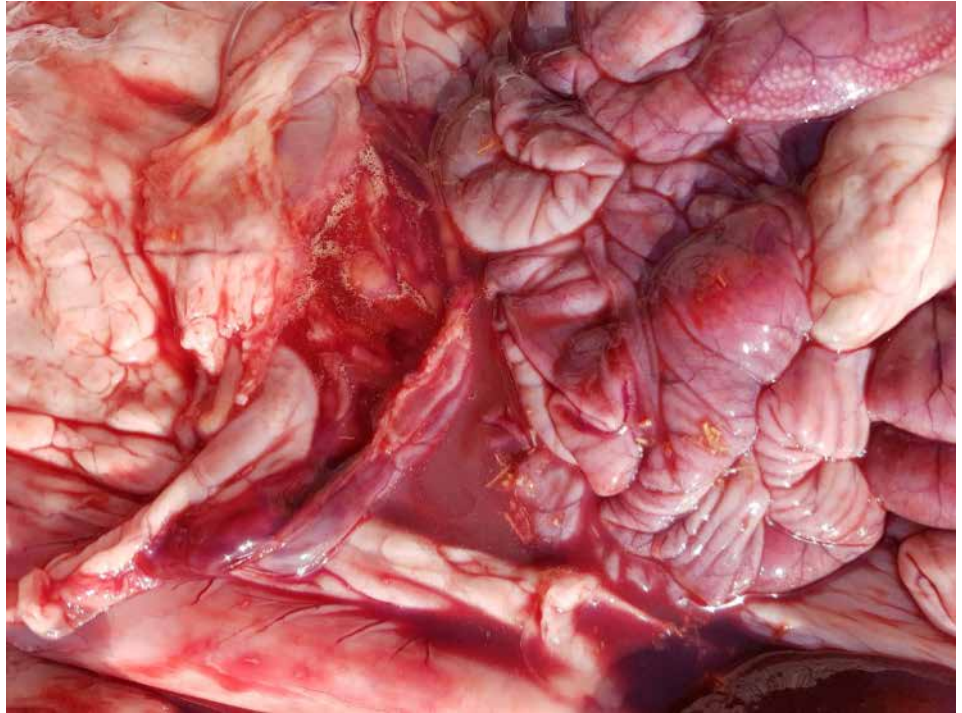**Figure 3.6.2.**

Duodenum: Mucosa is markedly expanded and infiltrated with large numbers of inflammatory cells. Crypts are elongated, tortuous, dilated and lined by attenuated epithelium, and filled with cellular debris admixed with neutrophils (crypt abscesses). Inflammation extends to submucosa. *E. coli* was isolated from intestines and the tissues tested negative for rota and corona viruses. This animal also was diagnosed with Haemonchosis.



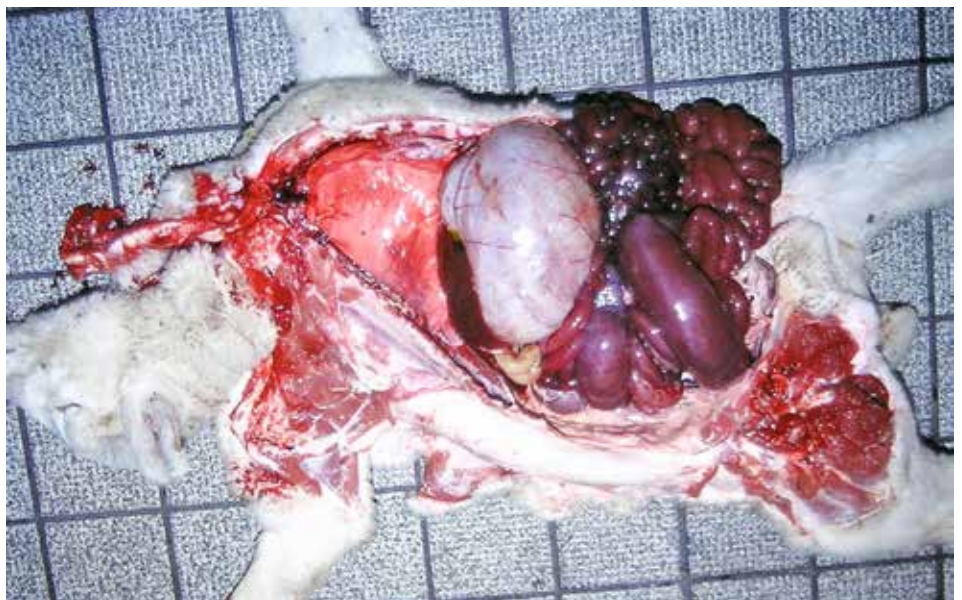
**Figure 3.6.3.**

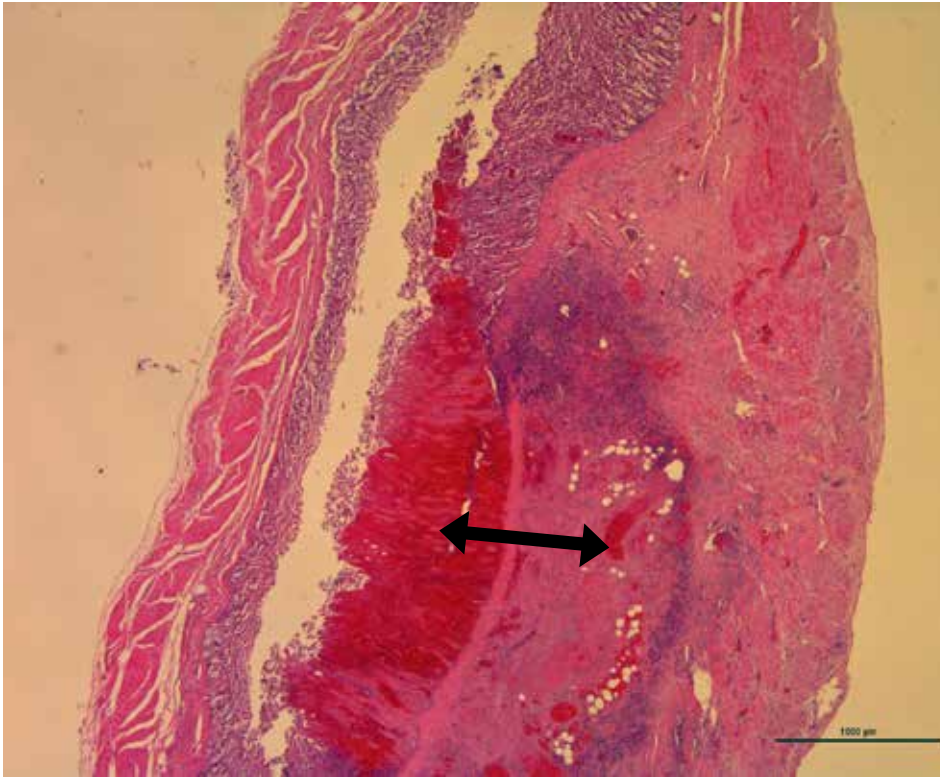
Hemorrhagic intestinal content (tomato soup-like), as observed with enterotoxaemia caused by *Clostridium perfringens* type D.



**Figure 3.6.4.**

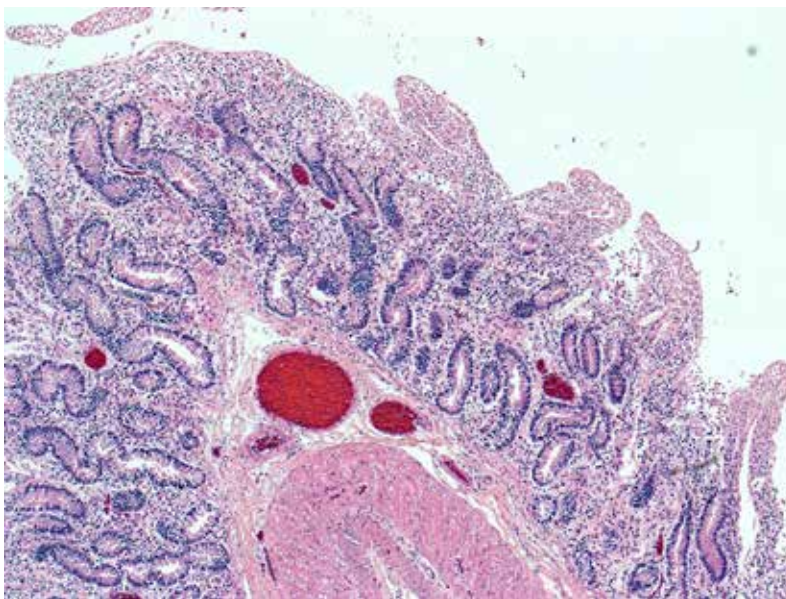
Clostridial enterotoxaemia in a lamb showing severely hemorrhagic intestinal loops.





**Figure 3.6.5.**

*Clostridium perfringens* enteritis in a lamb showing mucosal necrosis and hemorrhage in jejunum (double headed arrow).



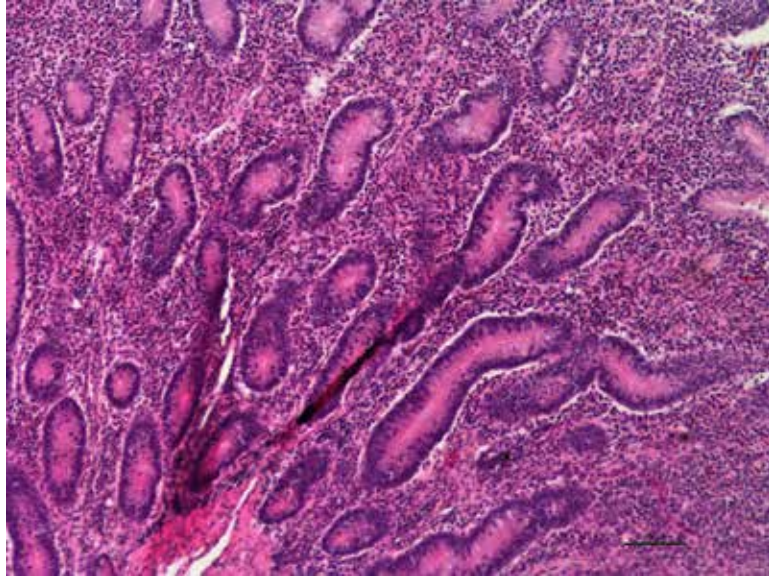
**Figure 3.6.6.**

Enterotoxemia – 4X. Small intestine is often autolyzed, and the only remarkable lesion is prominent transverse congestion. A few large bacterial rods may be scattered over the mucosal surface. Photo courtesy of M. Spinato.



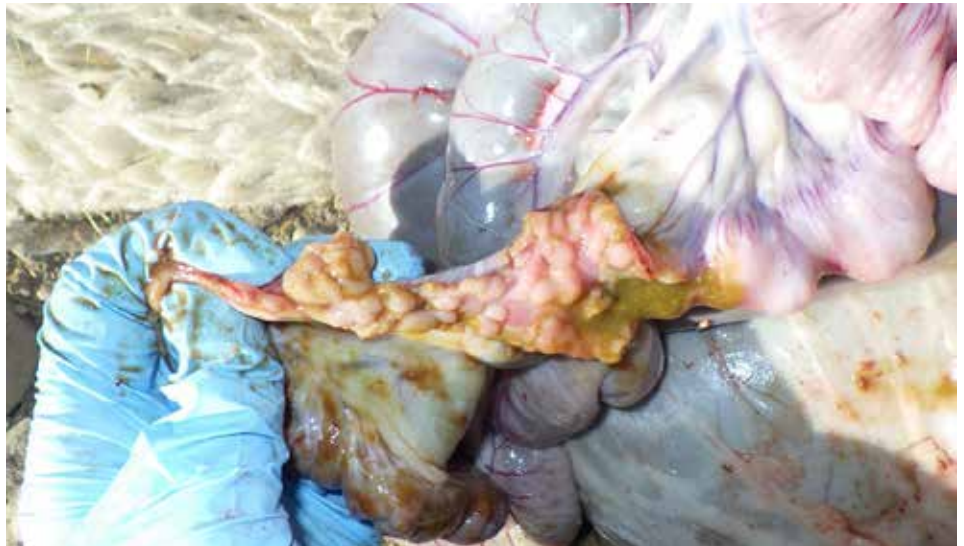
**Figure 3.6.7.**

Chronic enteritis in lamb showing small intestine (jejunum) with increased lymphocytes and plasma cells, and hyperplastic crypts.



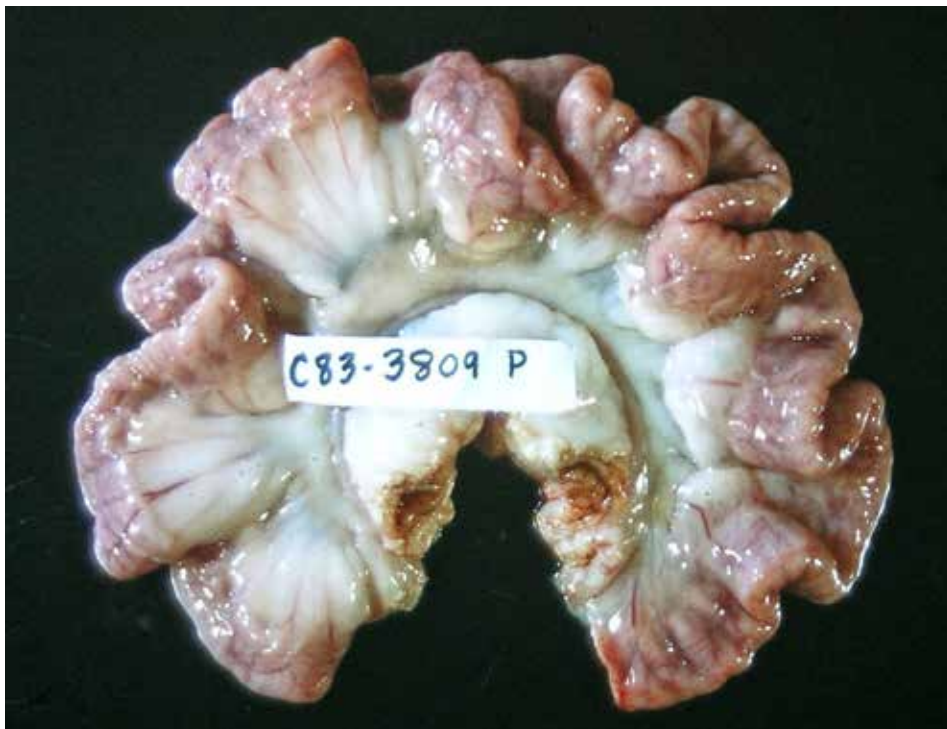**Figure 3.6.8.**

Chronic proliferative enteritis in a lamb.



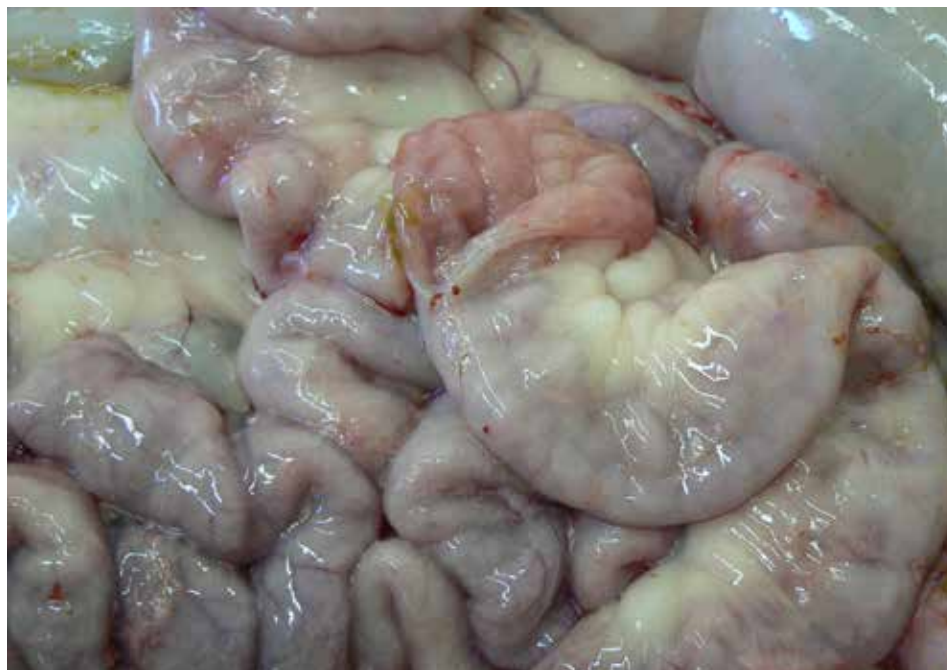

### 3.7. Paratuberculosis (Johne's Disease)



**Figure 3.7.1.**

Johne's disease in a sheep caused by *Mycobacterium paratuberculosis*. Note the thickened lower small intestinal loops. Histopathological examination will help to confirm the diagnosis.

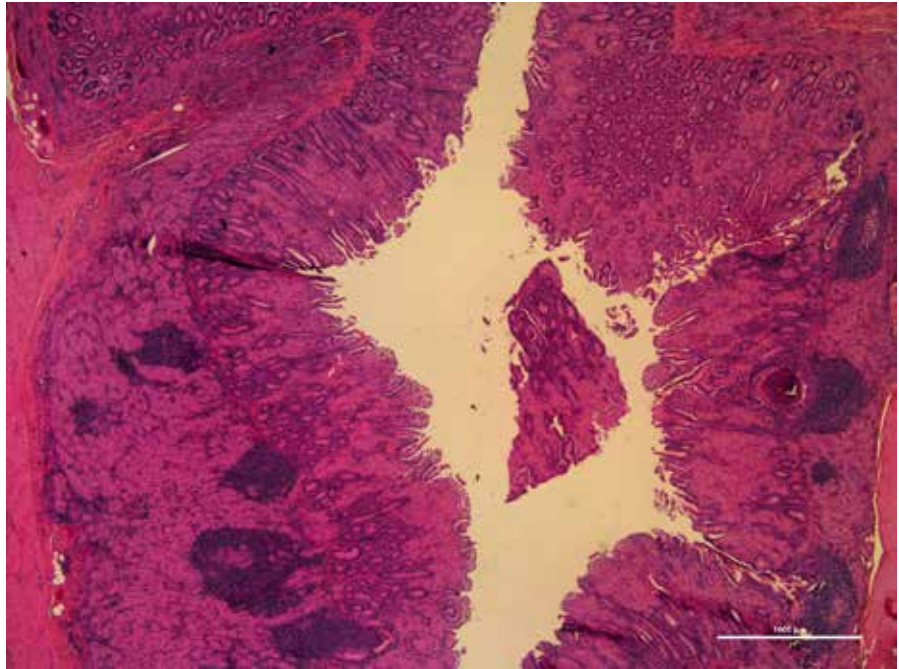


**Figure 3.7.2.**

Thickened intestinal loops from paratuberculosis.  
*Photo courtesy of P. Menzies.*

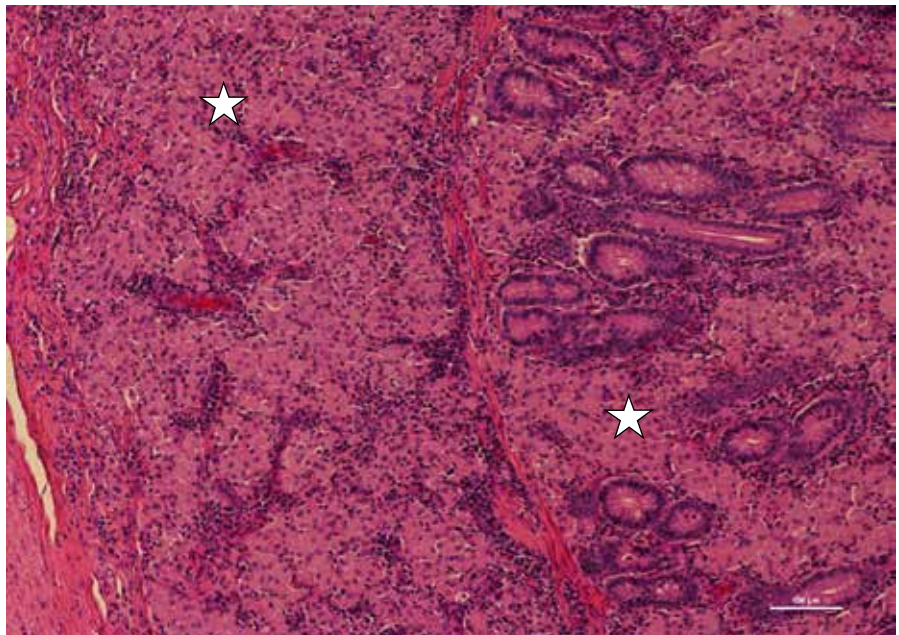
**Figure 3.7.3.**

Sheep that died due to severe dehydration. Histologically, there is granulomatous ileitis with diffuse expansion of mucosa and submucosa with inflammatory cells.

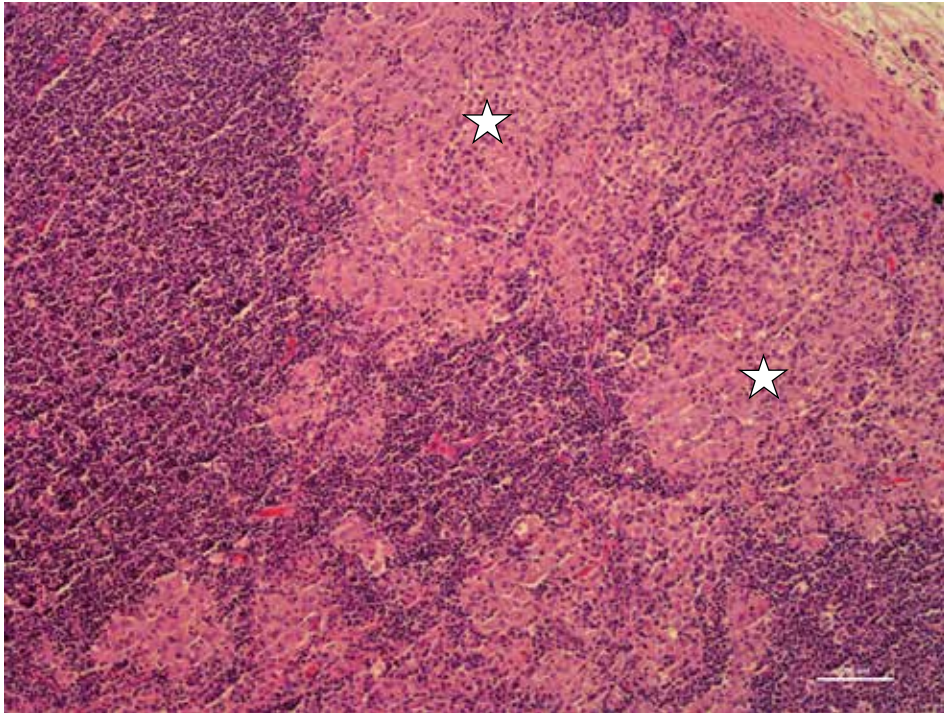


**Figure 3.7.4.**

High power view of granulomatous ileitis with diffuse expansion of mucosa and submucosa with epithelioid macrophages (stars).

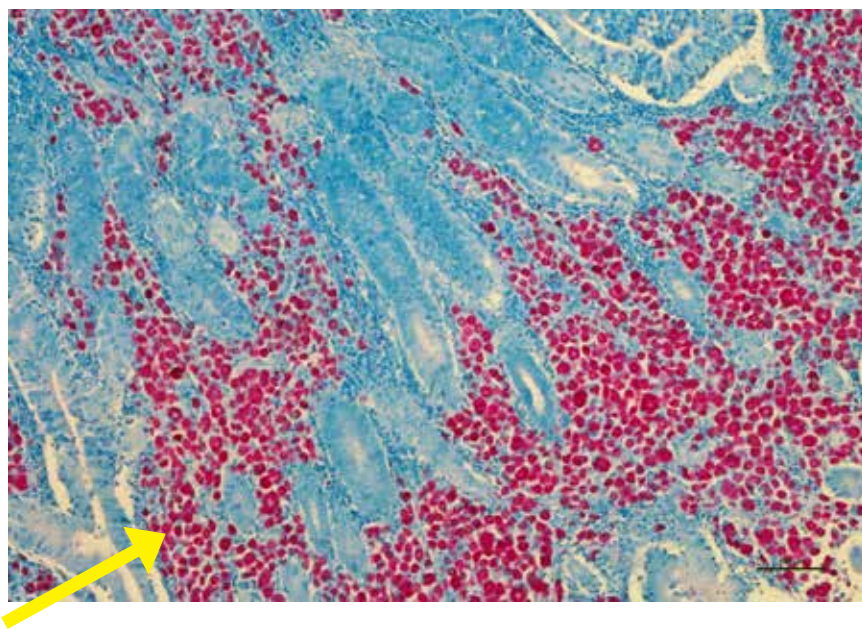






**Figure 3.7.5.**

Ileocecal and mesenteric lymph nodes will be enlarged in Johne's disease. Mesenteric lymph node showing epithelioid macrophages in lymph node sinuses (stars). Acid fast stains can be used to demonstrate Mycobacteria in macrophages.



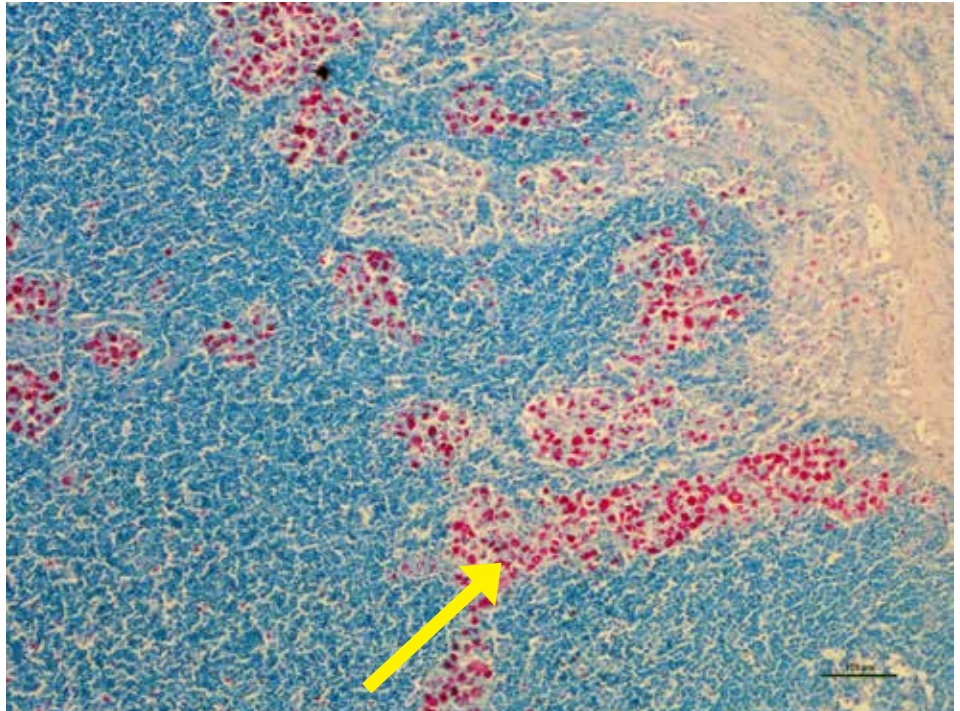
**Figure 3.7.6.**

Ileum showing myriads of red stained acid-fast positive bacilli (arrow) consistent with Johne's disease.



**Figure 3.7.7.**

Mesenteric lymph node showing aci-fast positive bacilli (arrow) consistent with Johne's disease.

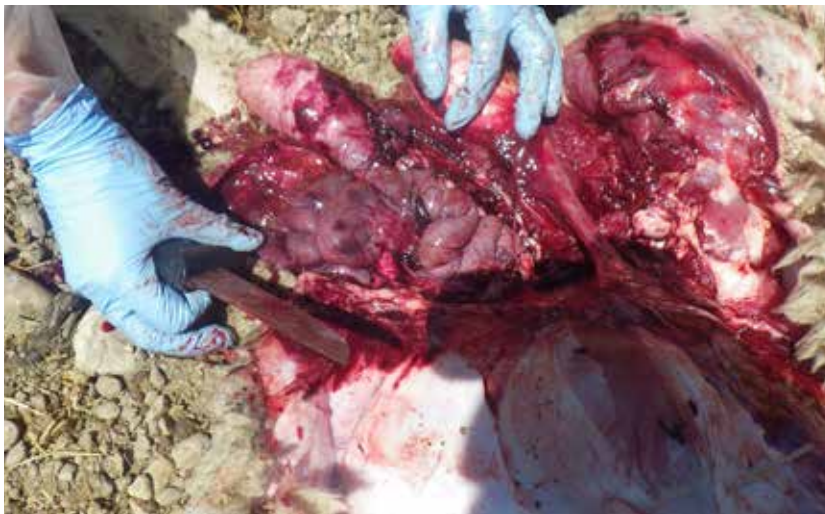

### 3.8. Inguinal Hernia



**Figure 3.8.1.**

Inguinal hernia in a feedlot ram.



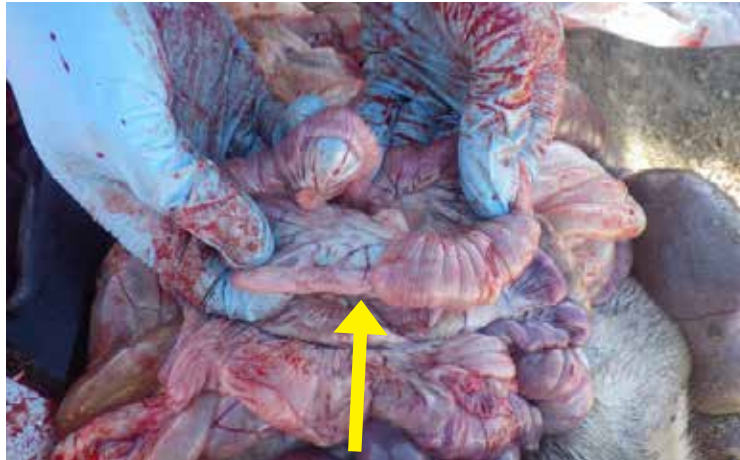**Figure 3.8.2.**

Inguinal hernia in a feedlot ram.

### 3.9. Intussusception

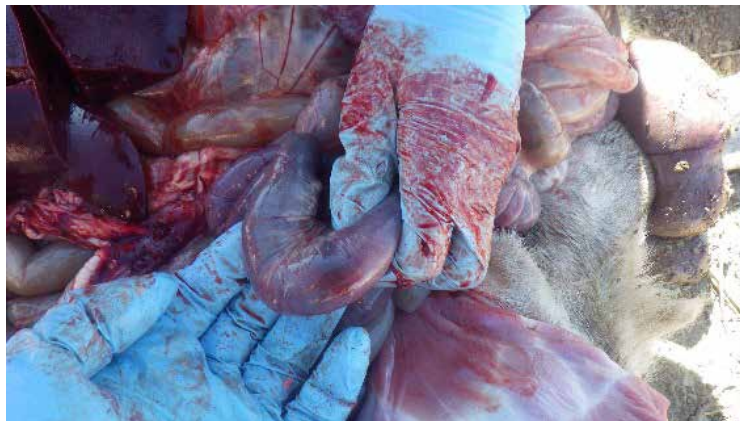**Figure 3.9.1.**

Intussusception can occur due to ongoing peristalsis and may cause minor congestion. Severe intestinal worm infestation and localized intestinal problems can cause intussusception in lambs.



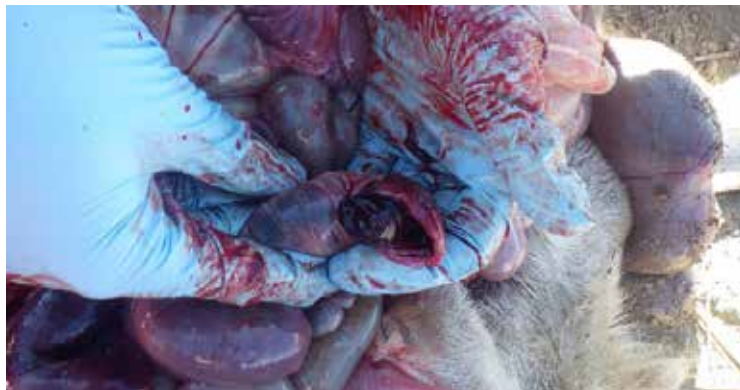**Figure 3.9.2.**

Intussusception with congested small intestine.

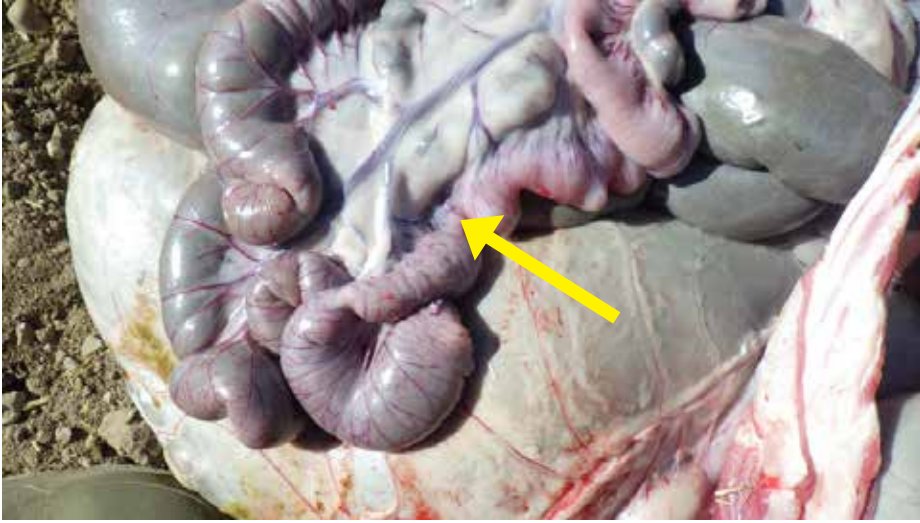


**Figure 3.9.3.**

Clinically significant intussusception will have edema and congestion of the affected intestinal segments as well as blockage of fecal contents.







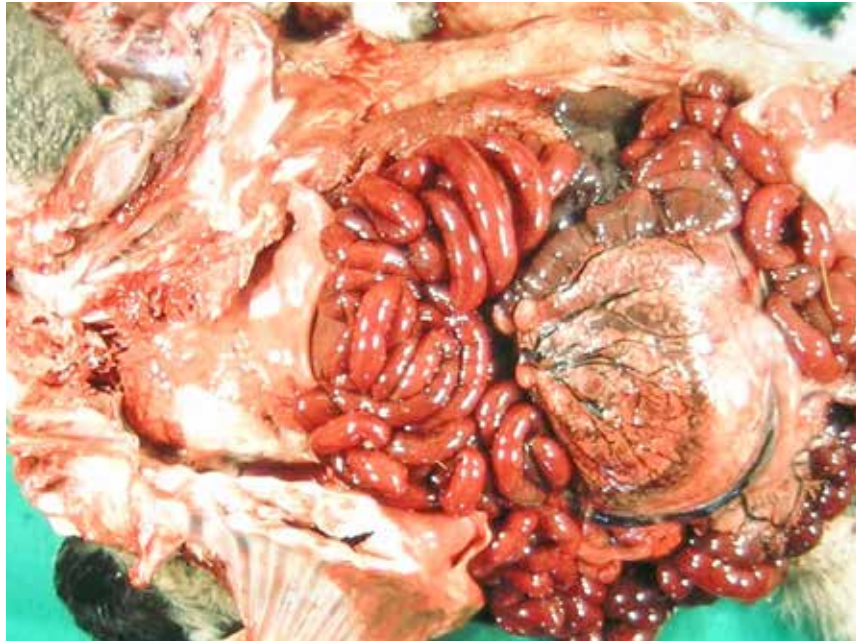**Figure 3.9.4.**

Intussusception  
of small intestine.

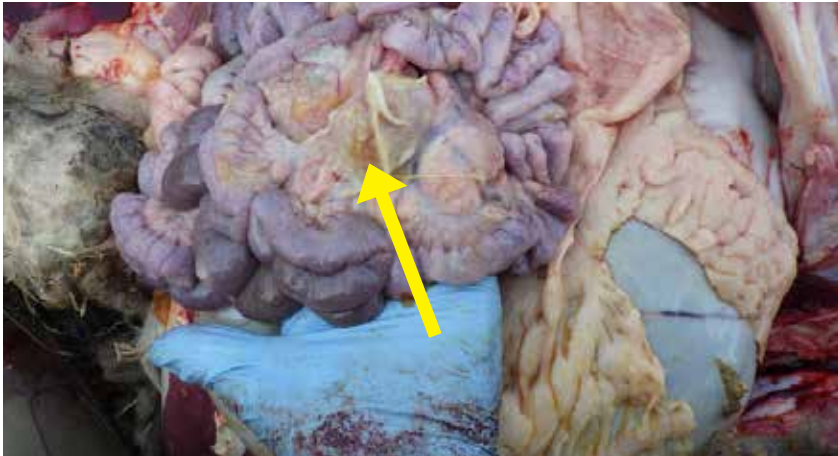### 3.10. Intestinal Torsion

**Figure 3.10.1.**

Intestinal torsion in a sheep showing congested and hemorrhagic intestinal loops.

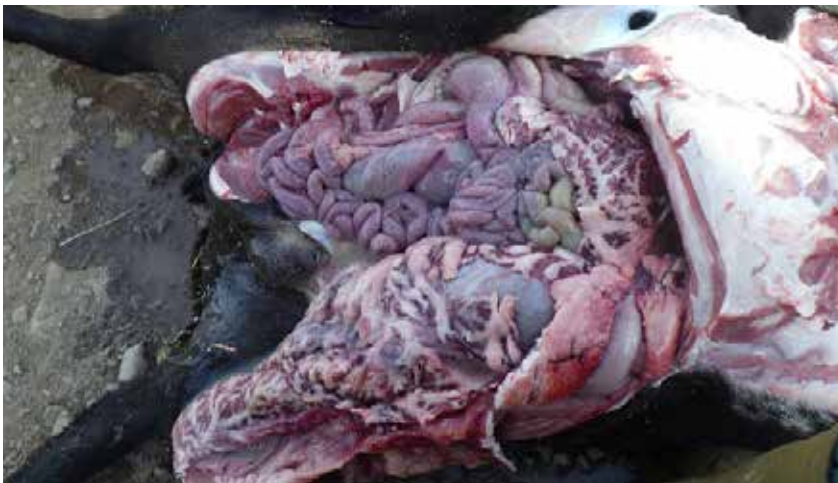

### 3.11. Peritonitis



**Figure 3.11.1.**

Fibrin strands present in peritonitis usually seen with systemic bacterial septicemia or gastrointestinal perforations.



**Figure 3.11.2.**

Severe peritonitis due to ruminal ulcer.



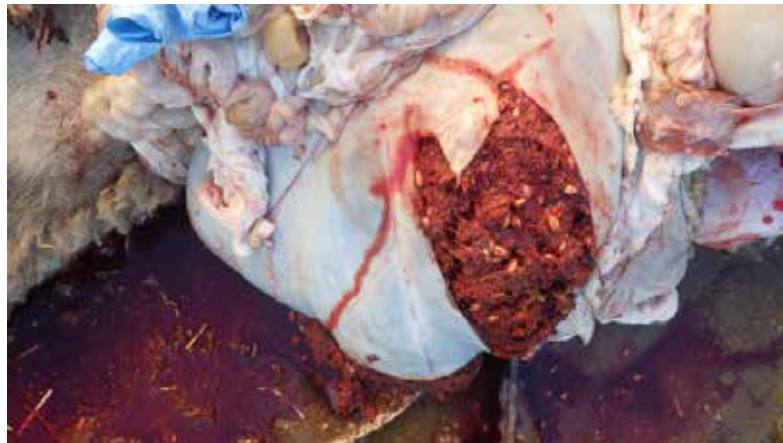**Figure 3.11.3.**

Ruminal ulcer.

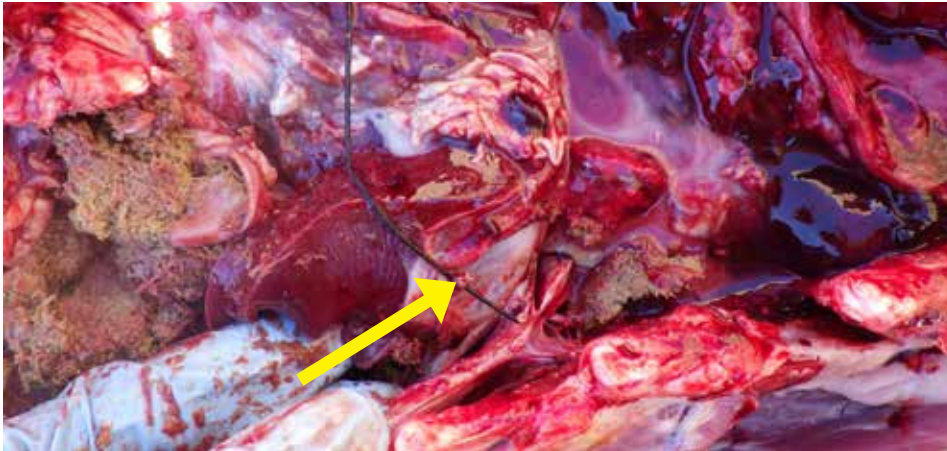


**Figure 3.11.4.**

Blood in rumen due to bleeding ulcer.

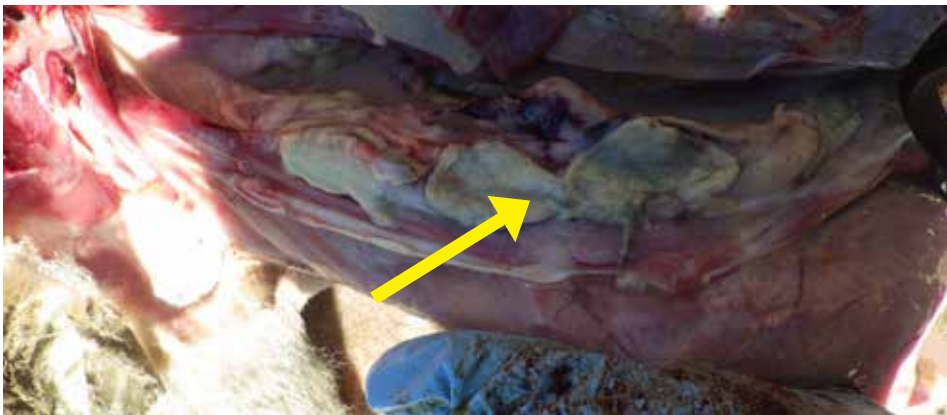

### 3.12. Hardware Disease – Reticuloperitonitis



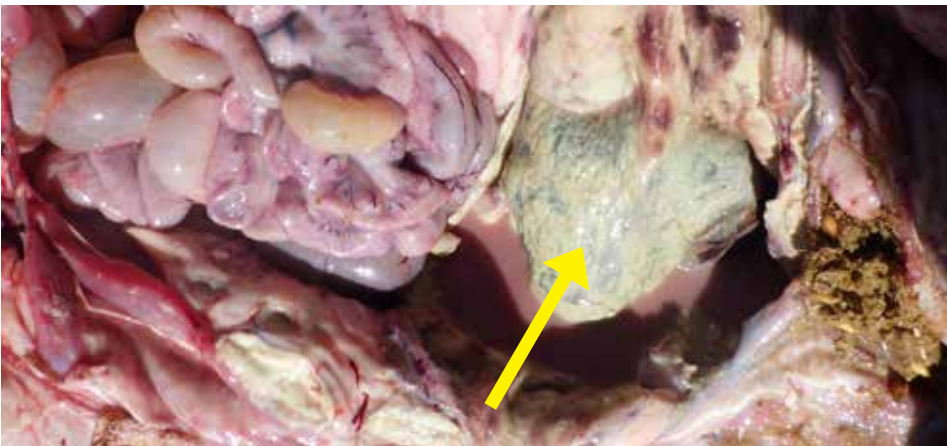**Figure 3.12.1.**

Wire found causing pericarditis (inflammation around the heart). Wire typically perforates one of the chambers of the stomach and then can perforate other organs, including the diaphragm into the heart, as in this case.



**Figure 3.12.2.**

Necrotizing tract where wire was found.



**Figure 3.12.3.**

Necrotizing pericarditis from wire above.



### 3.13. Tapeworm (Cestodiasis/Moneziasis)

**Figure 3.13.1.**

Freed tapeworm (*Monezia expansa*) from rectum.  
*Photo courtesy of P. Menzies.*

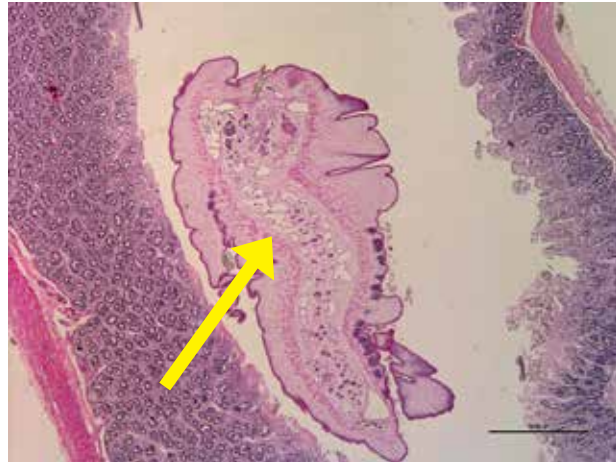

**Figure 3.13.2.**

Tapeworm (*Taenia ovis*).  
*Photo courtesy of P. Menzies.*

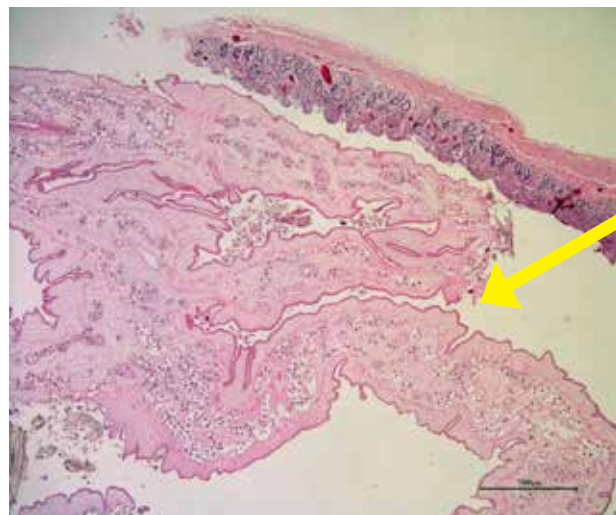





**Figure 3.13.3.**

Section of a tapeworm noted incidentally in the section of small intestine in a lamb.



**Figure 3.13.4.**

Cross section of tapeworm in small intestine.

### 3.14. Rectal Prolapse

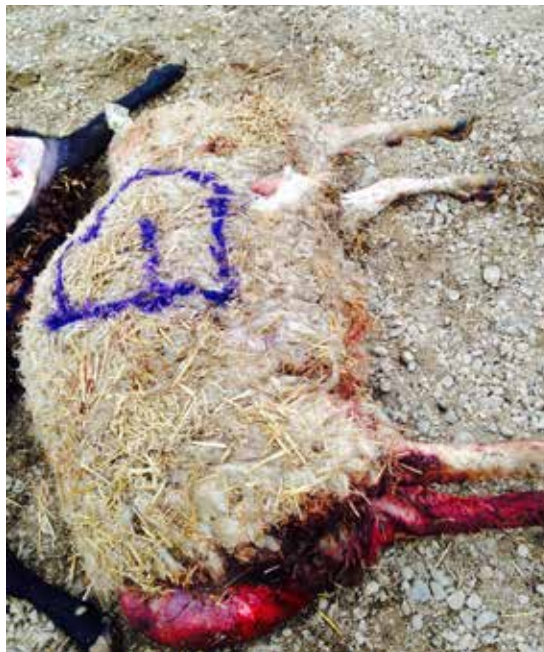**Figure 3.14.1.**

Rectal and vaginal prolapse.



**Figure 3.14.2.**

Rectal prolapse.





**Figure 3.14.3.**

Rectal prolapse.

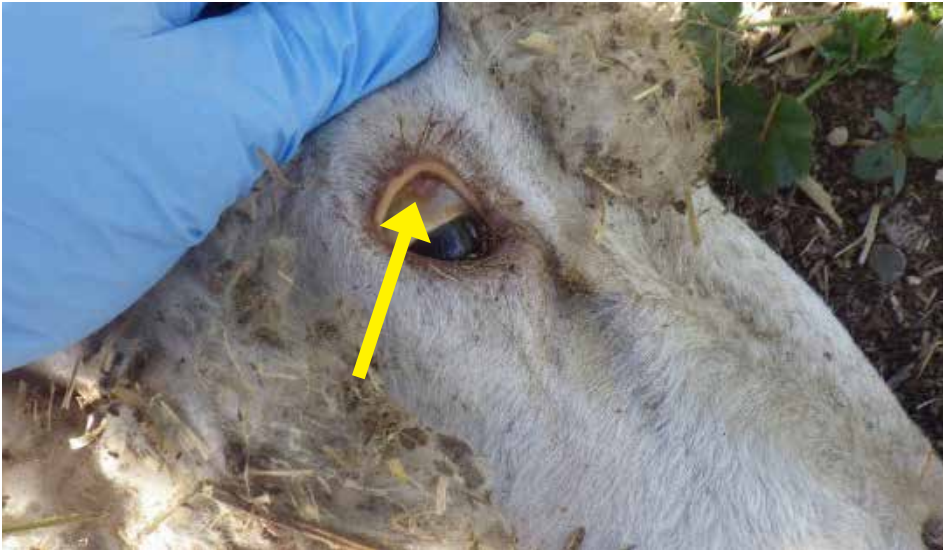

## IV. HEPATOBILIARY SYSTEM

1. Copper Toxicity.....	132
2. Liver Fluke Infestation.....	137
3. Bacterial Septicemia .....	141
4. Fatty Liver Disease .....	147
5. Caudal Vena Cava Thrombosis.....	149
6. Campylobacteriosis.....	151
7. Hepatic Cestodiasis.....	153
8. Caseous Lymphadenitis .....	154
9. Hepatic Necrobacillosis .....	155

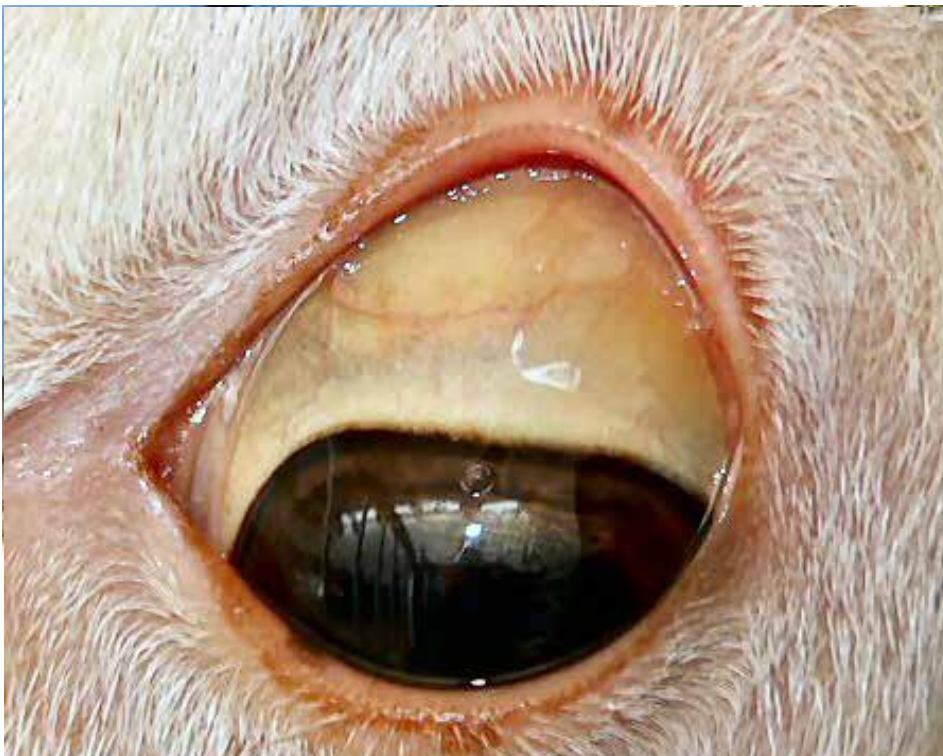## IV. HEPATOBILIARY SYSTEM

### 4.1. Copper Toxicity



**Figure 4.1.1.**

Jaundice (yellow color of the sclera) can be seen in the ocular mucous membranes on ante-mortem and post-mortem examination in copper toxicity.

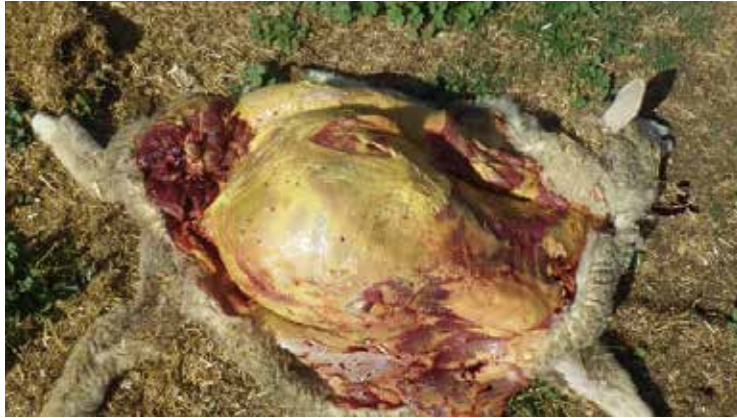

**Figure 4.1.2.**

Jaundice (yellow color of the sclera) in copper toxicity.  
*Photo courtesy of P. Menzies.*

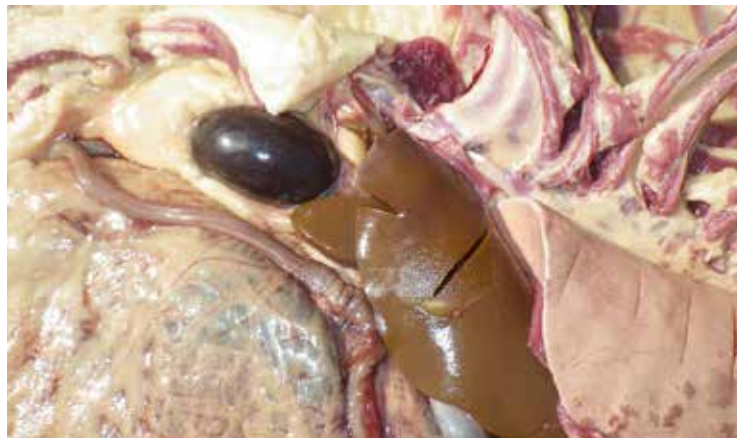**Figure 4.1.3.**

Severe jaundice in a feedlot lamb that died of copper toxicity. Subcutaneous fat yellow.



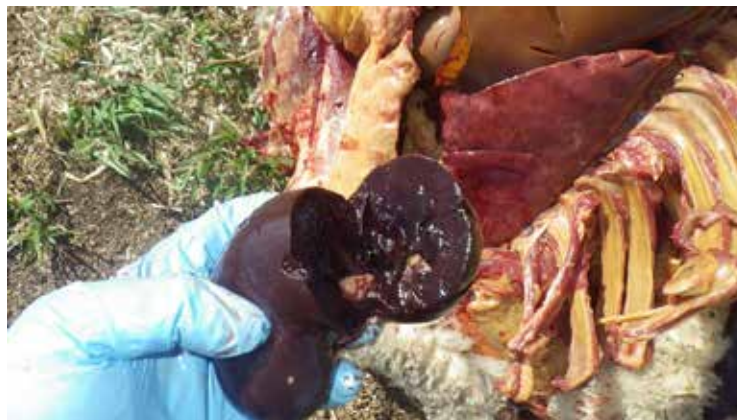**Figure 4.1.4.**

Dark kidneys and enlarged, pale, friable liver due to necrosis of hepatic cells.

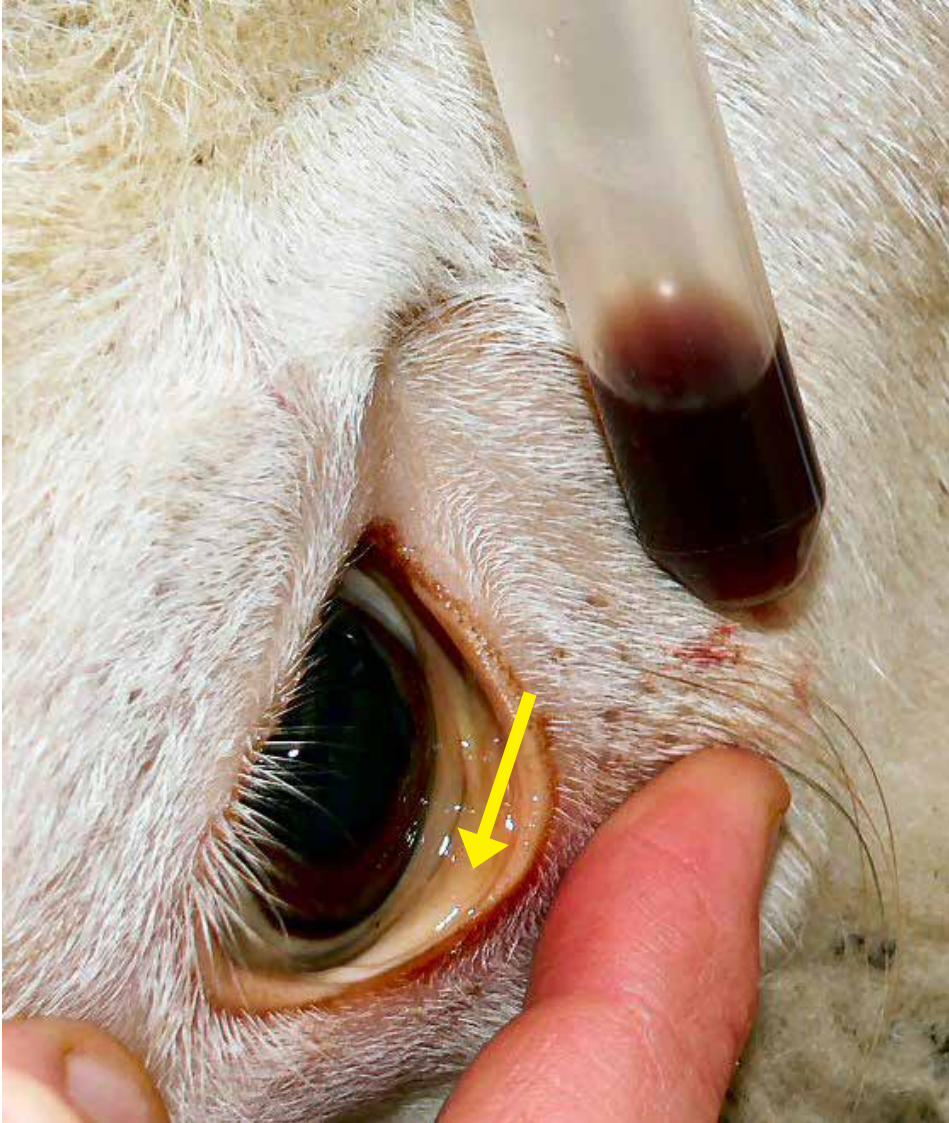


**Figure 4.1.5.**

“Gun Metal Black” coloured kidneys which had a copper level of 83.3 ppm.







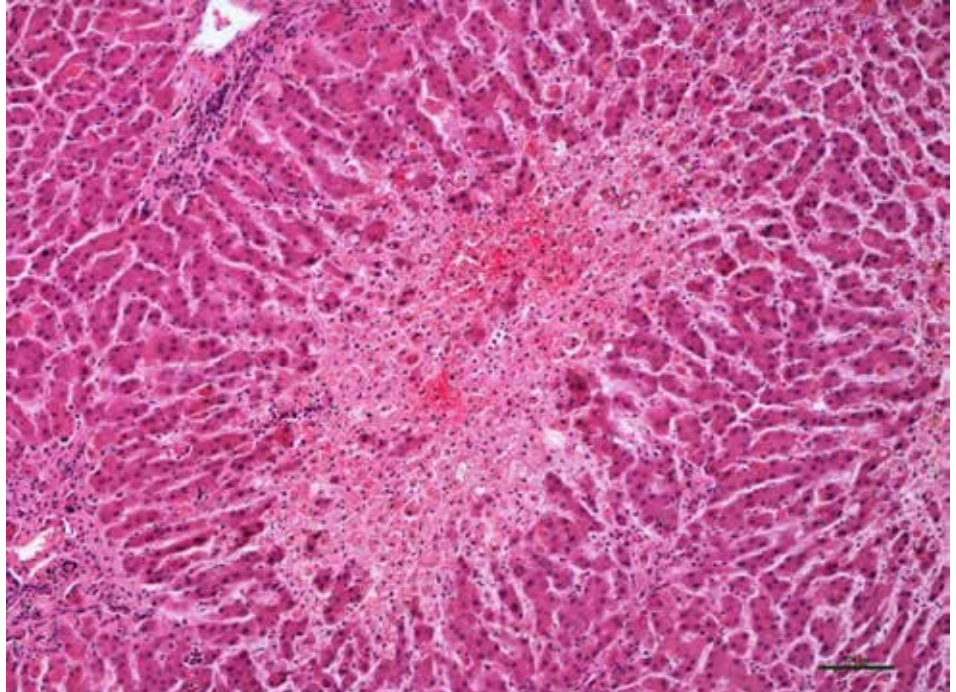
**Figure 4.1.6.**

Yellow discoloration (jaundice) of conjunctiva (arrow) and port-wine-colored urine from a sheep affected with copper toxicity.

*Photo courtesy of P. Menzies.*

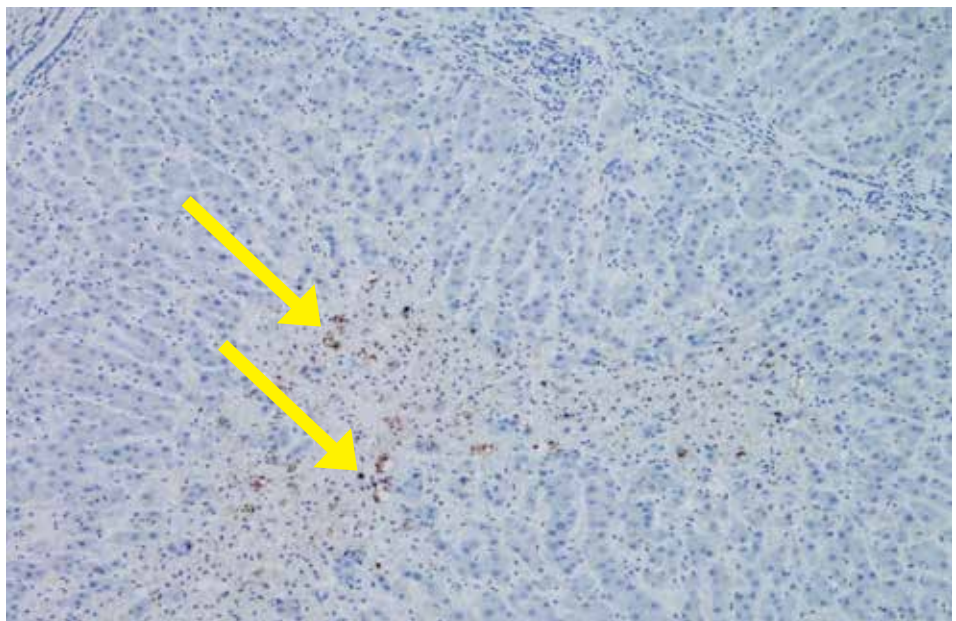
**Figure 4.1.7.**

Copper toxicity in a lamb –  
Liver showing centrilobular  
hepatocyte necrosis  
with hemorrhage.

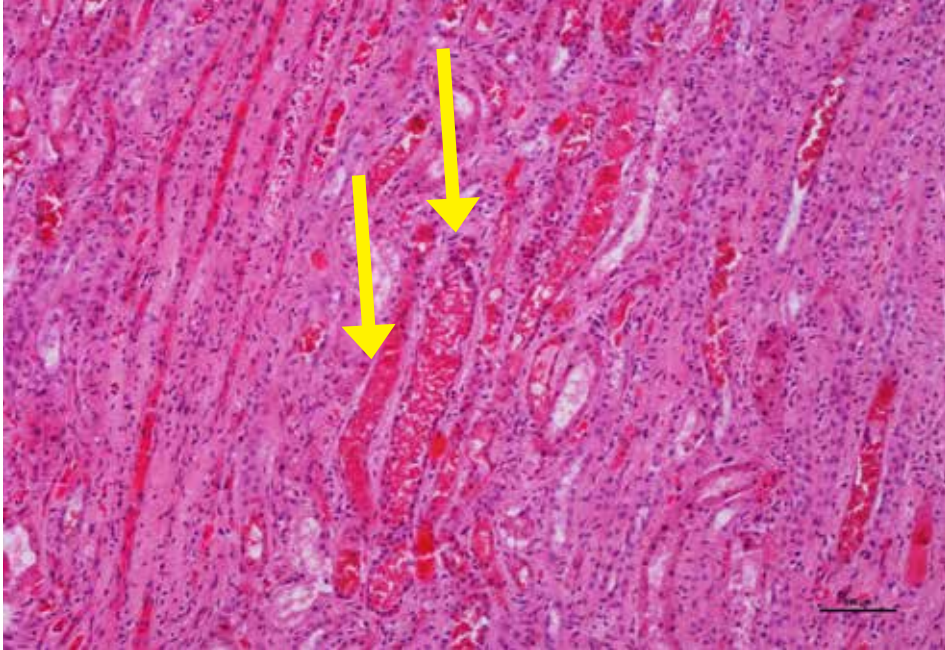


**Figure 4.1.8.**

Copper toxicity in a lamb –  
Liver showing copper  
accumulation in hepatocytes  
demonstrated by special stain,  
Rhodanine (arrows).

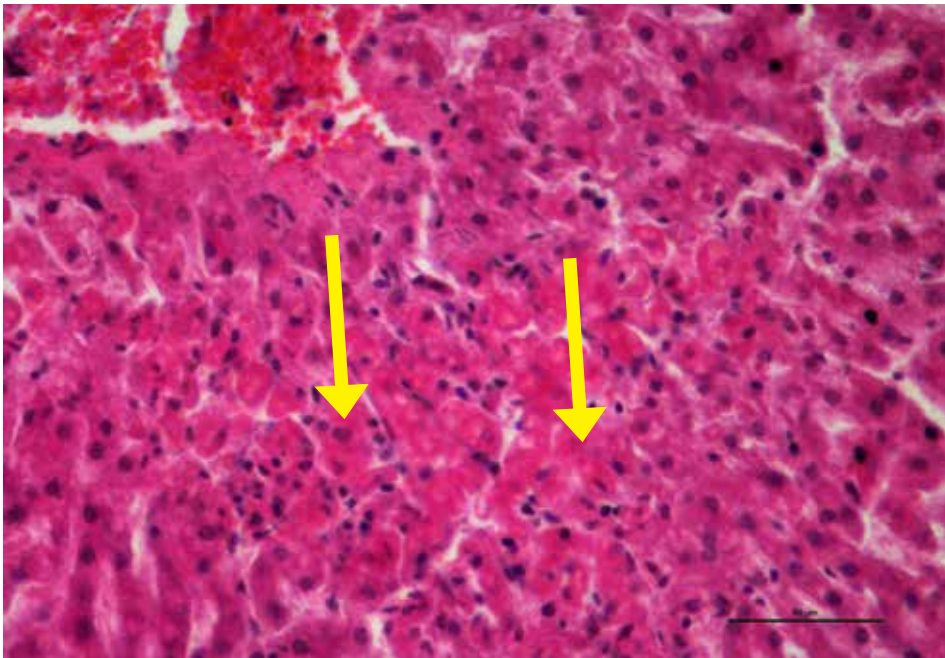






**Figure 4.1.9.**

Copper toxicity in lamb showing red pigmented material (arrows) in the many renal tubules (pigmentary (haemoglobinuric nephrosis).



**Figure 4.1.10.**

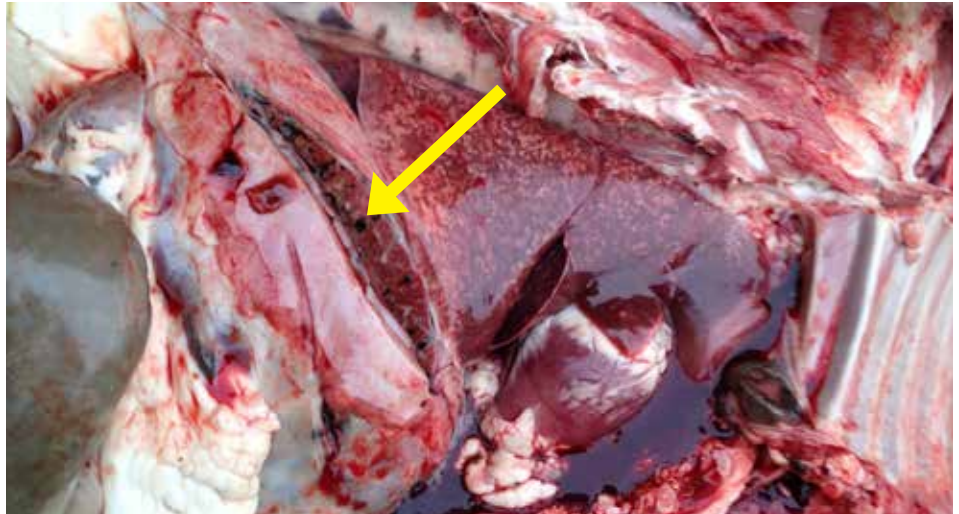
Copper toxicity in lamb showing acute hepatocyte degeneration and necrosis (arrows).



## 4.2. Liver Fluke Infestation

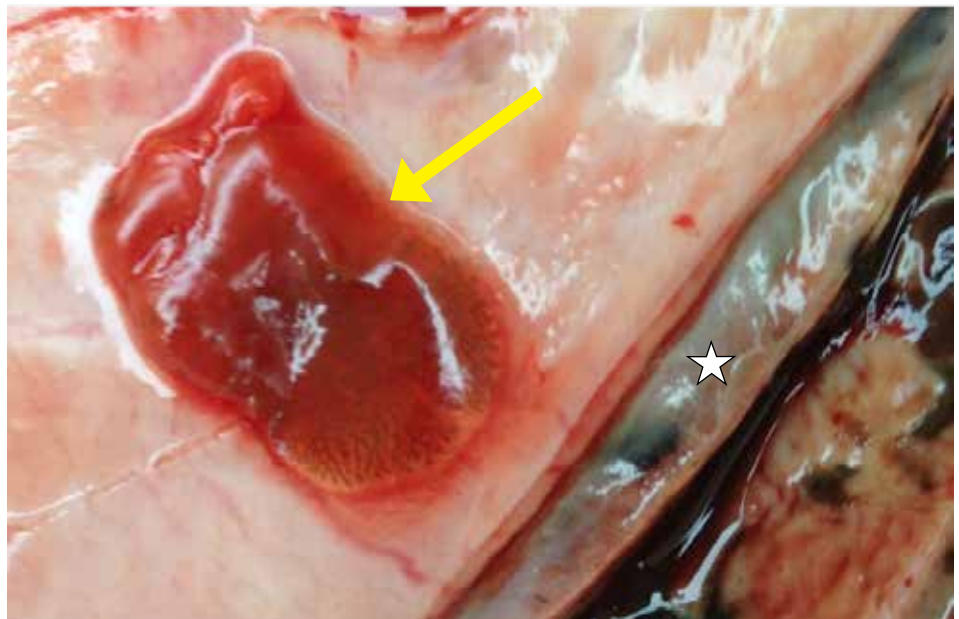
**Figure 4.2.1.**

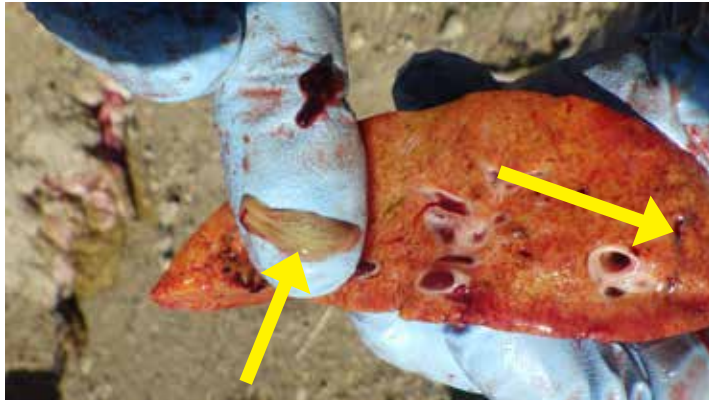Liver fluke infestation (*Fascioloides magna*) with migration tracts through liver parenchyma (arrow pointing to black tracts through liver).



**Figure 4.2.2.**

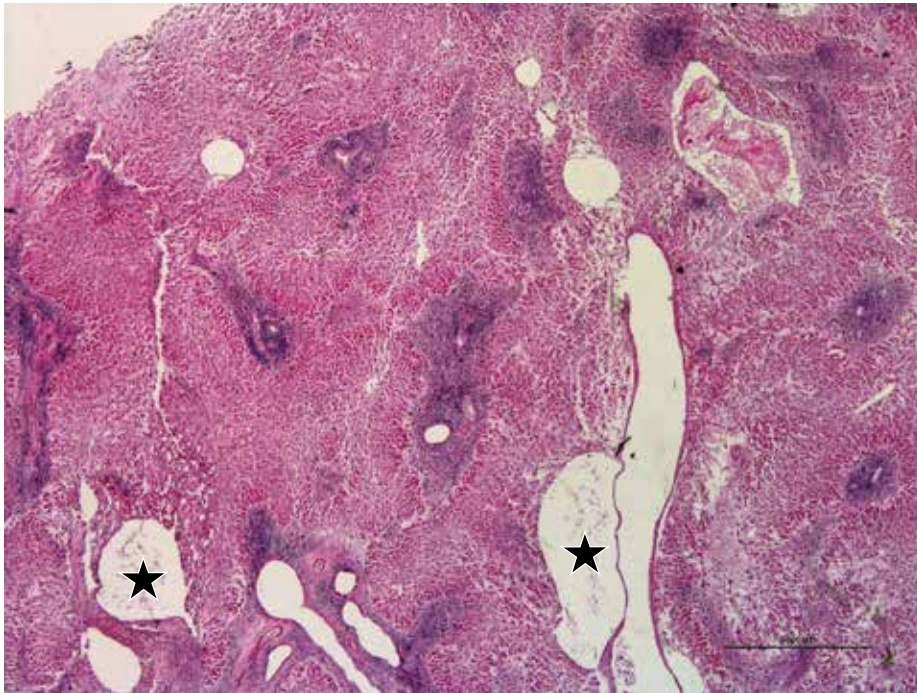
Diaphragm adhered to liver (star) of a lamb infected with liver flukes. Necrotic migrating tracts were noted in liver. Arrow showing liver fluke that was taken from the migratory tracts of liver.





**Figure 4.2.3.**

Liver fluke *Fascioloides magna* (arrow to left) and yellow liver with black tracts (arrow to right) from liver fluke migration.



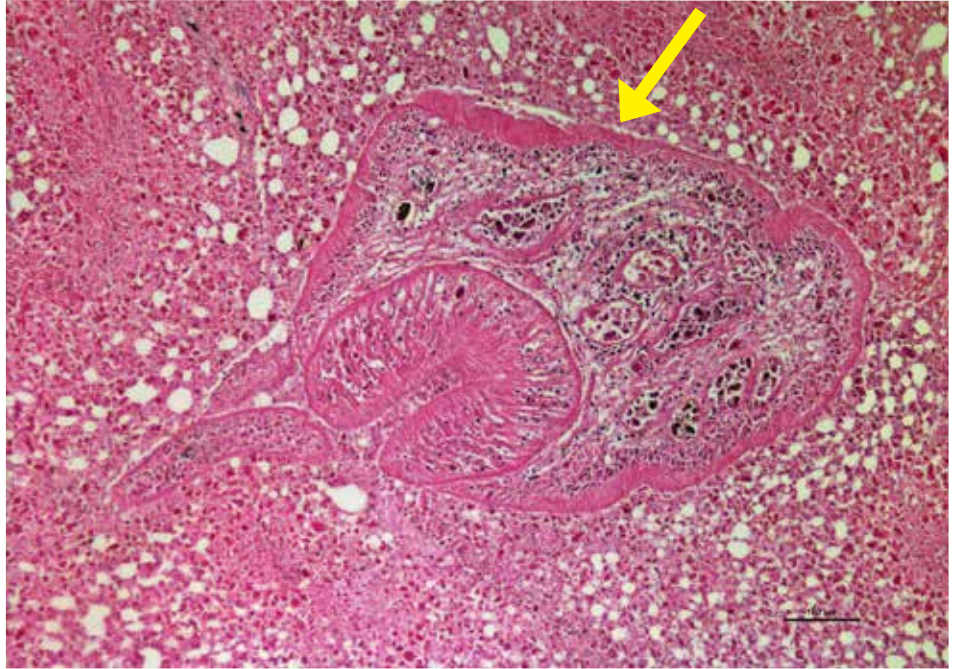**Figure 4.2.4.**

Liver showing fluke migration tracts (stars).

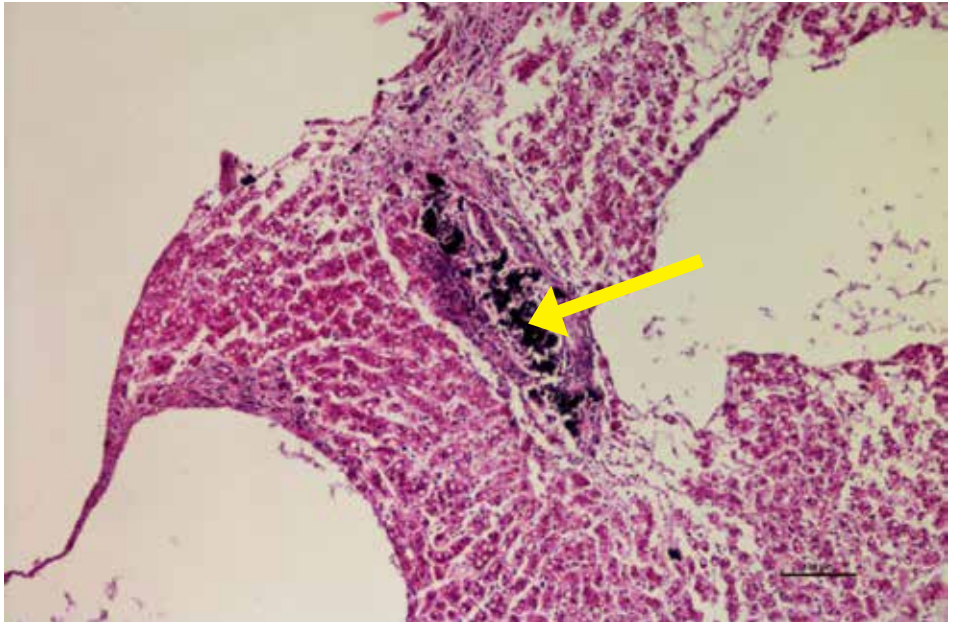


**Figure 4.2.5.**

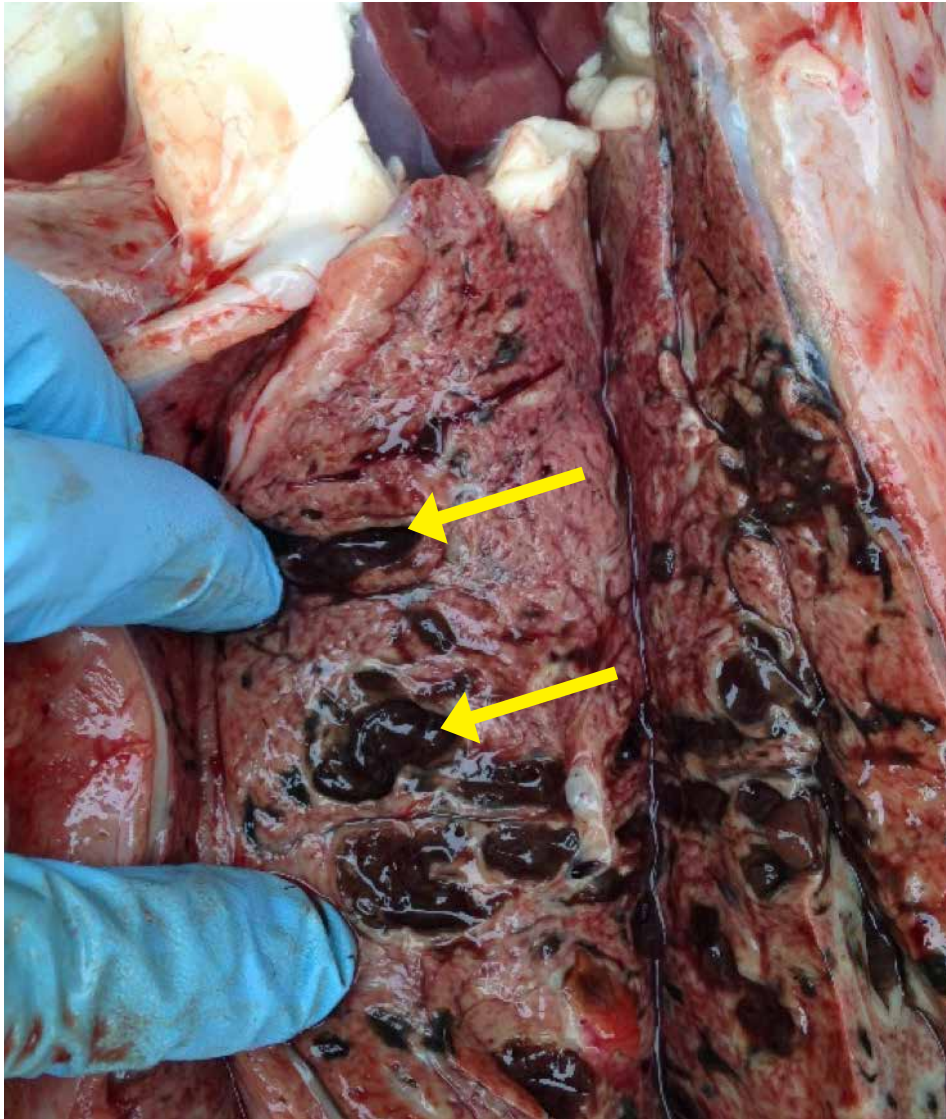
Liver fluke in a section of liver  
(arrow).

**Figure 4.2.6**

Liver with migratory tracts and  
black excrement from flukes  
(arrow).







**Figure 4.2.7.**

Damage caused by liver flukes can predispose sheep to Black disease (bacillary haemoglobinuria) caused by *Clostridium novyi*. Section of liver fluke, fluke excrement and fluke migration tracks in the liver. *Fasciola hepatica*, *Fascioloides magna* and *Dicrocoelium dendriticum* are three trematodes or “flukes” which can infect sheep. It is important to determine which species of liver fluke is involved since diagnosis and control for each is different.

### 4.3. Bacterial Septicemia

**Figure 4.3.1.**

Liver showing miliary areas of necrotizing hepatitis from bacterial septicemia with *Bibersteinia trehalosi*. Tularemia caused by *Francisella tularensis* should be considered as a differential for this type of liver lesion in endemic areas.

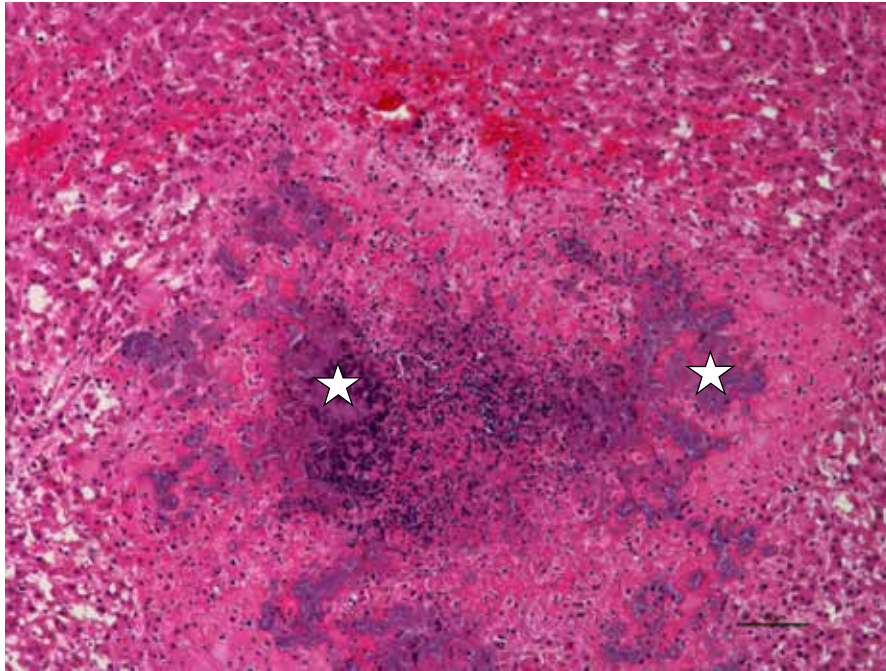


**Figure 4.3.2.**

Liver showing miliary areas of necrotizing hepatitis.

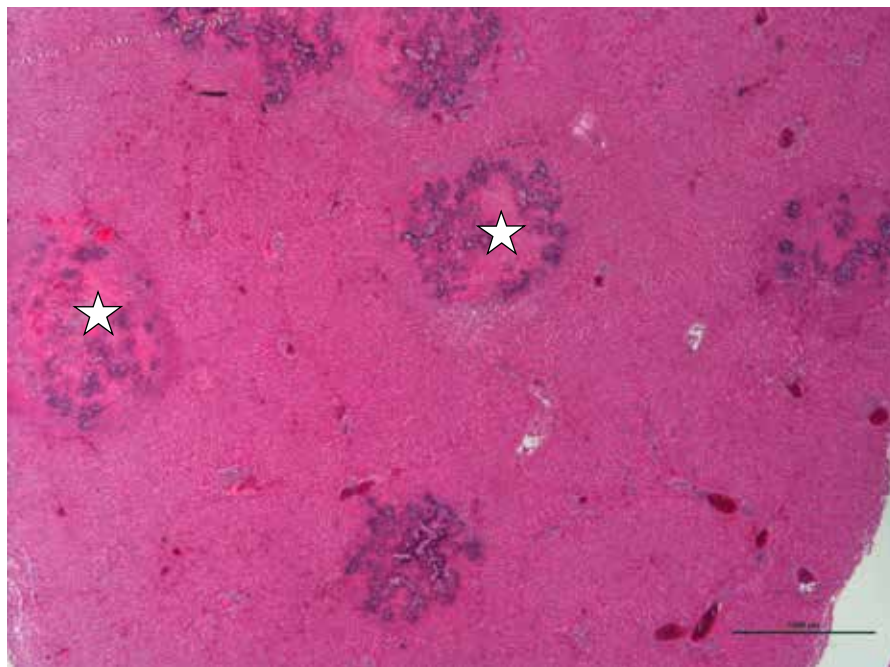






**Figure 4.3.3.**

Liver is congested, hemorrhagic and edematous with multifocal bacterial emboli (stars) surrounded by streaming leukocytes. *Bibersteinia trehalosi* was isolated from liver.



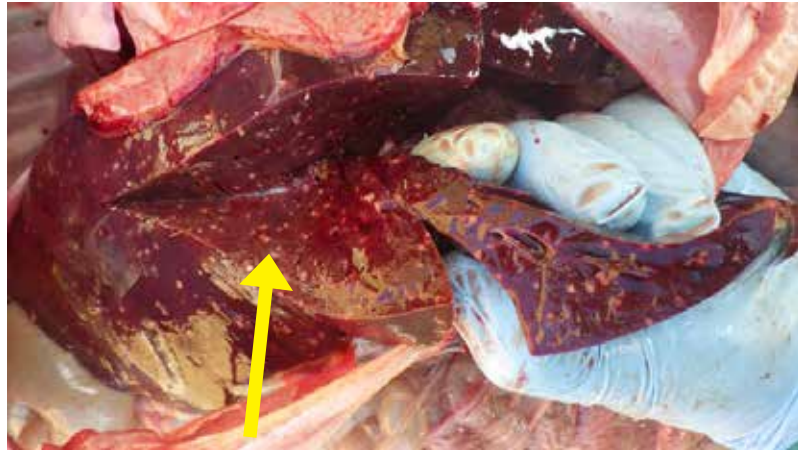**Figure 4.3.4.**

Low power view of liver showing multifocal (embolic) necrotizing hepatitis (stars) in a lamb that died due to bacterial septicemia caused by *Bibersteinia trehalosi*.



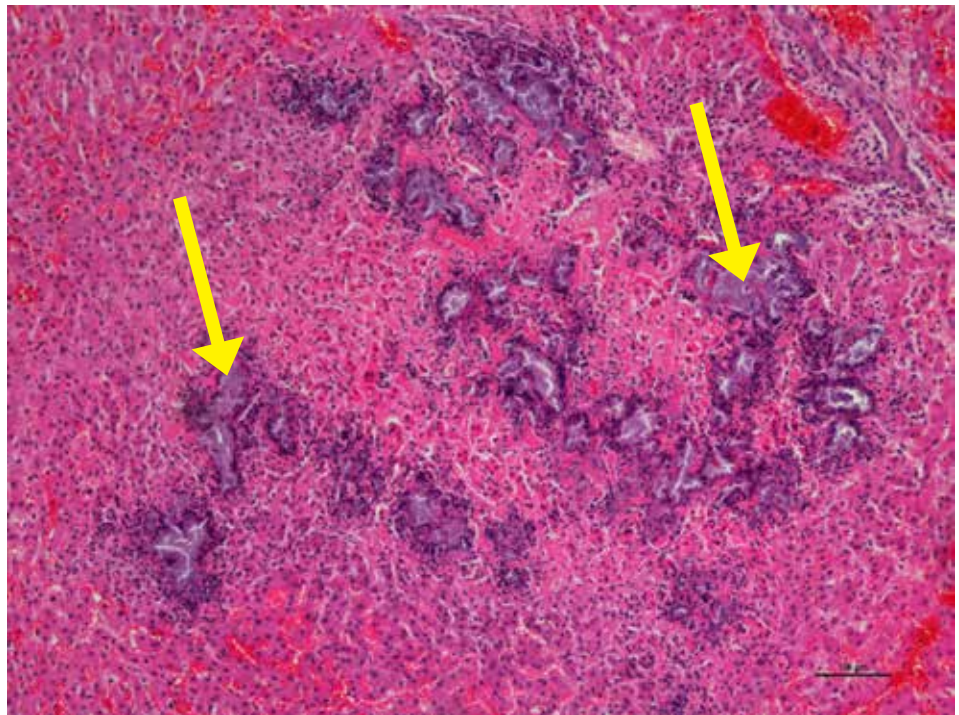
**Figure 4.3.5.**

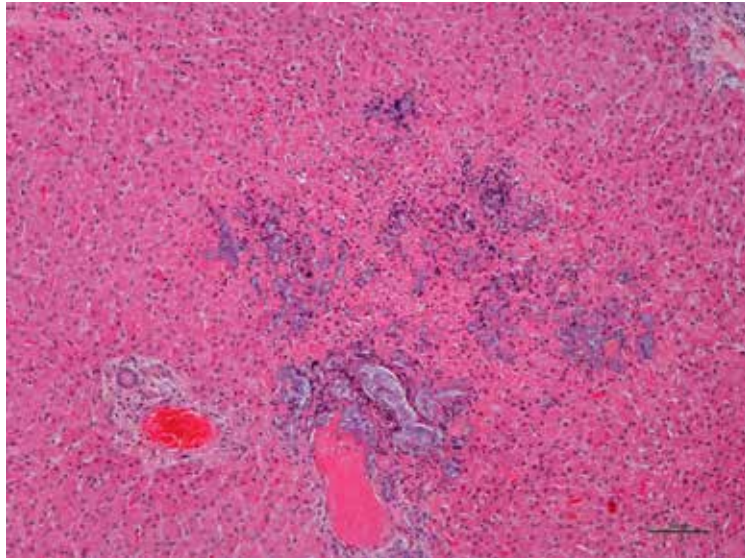
Miliary white areas of necrosis (arrow) in liver of a lamb that died due to bacterial septicemia caused by *Bibersteinia trehalosi*.



**Figure 4.3.6.**

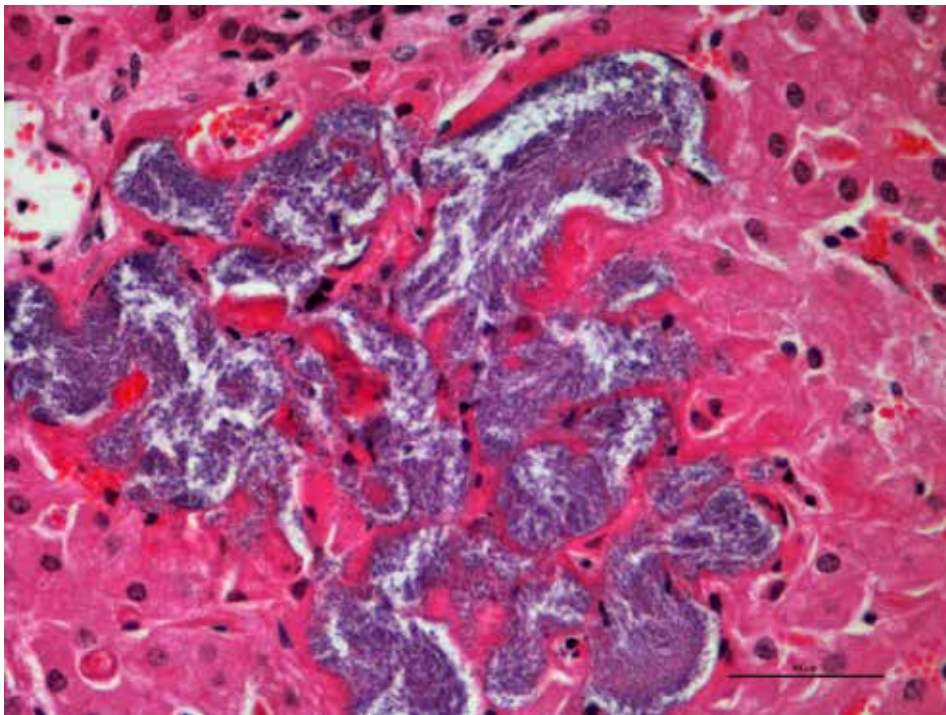
Liver from the same lamb (Fig 4.3.5) showing extensive necrotizing hepatitis with bacterial colonies (arrows).





**Figure 4.3.7.**

Necrotizing hepatitis and intralesional bacterial colonies. Streaming of leukocytes around bacterial colonies is a common histological finding. *Bibersteinia trehalosi* was isolated from the liver. Copper deficiency was noted in trace mineral analysis of liver.



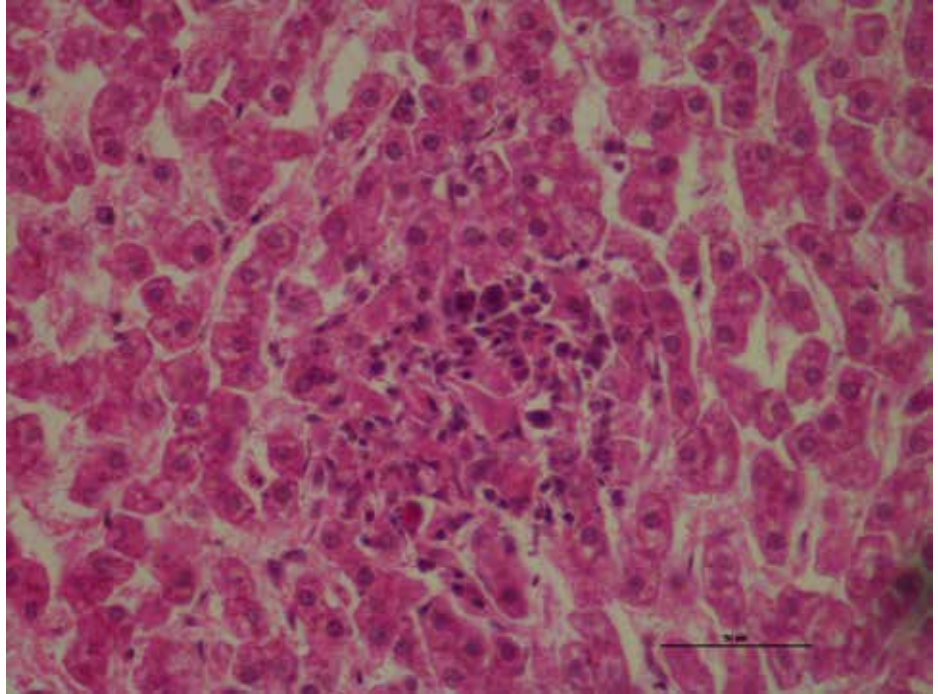
**Figure 4.3.8.**

Liver: Acute hepatic necrosis with large bacterial colonies in the hepatic sinuses.



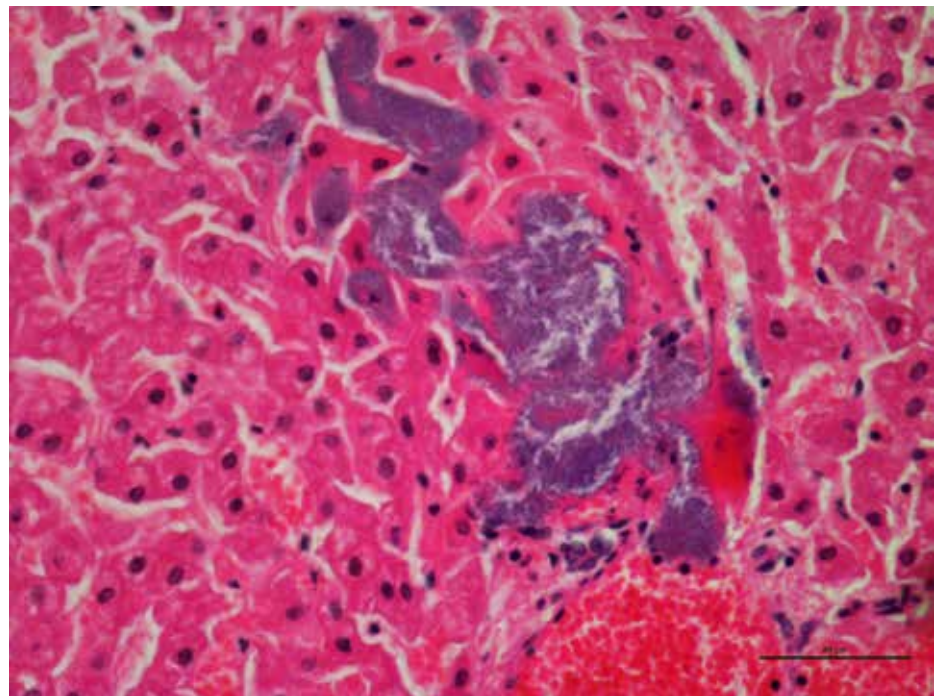
**Figure 4.3.9.**

Liver showing evidence of foci of hepatic necrosis.

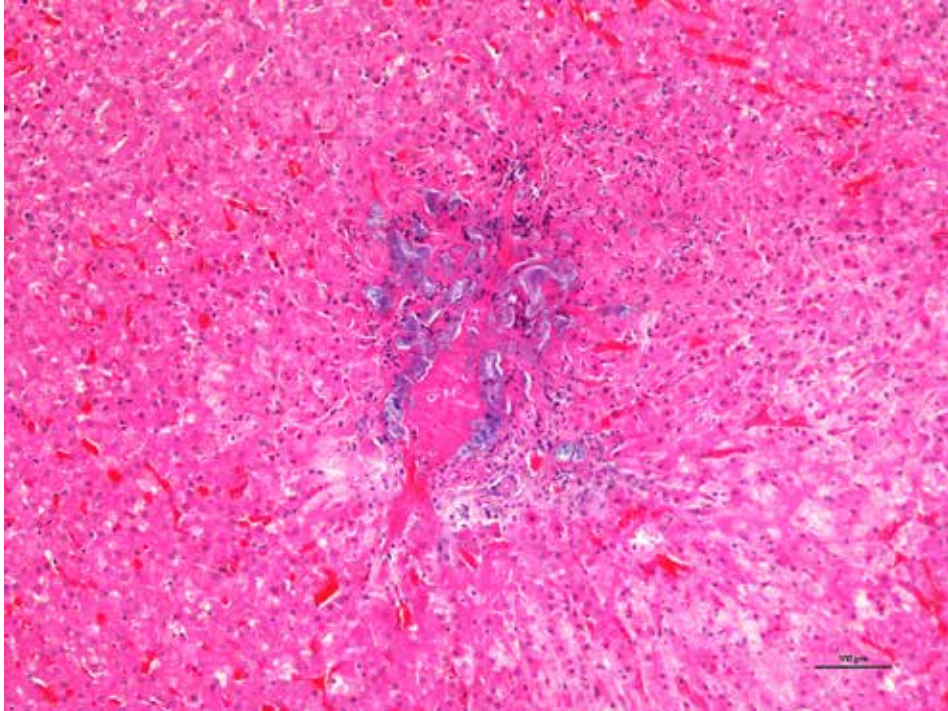


**Figure 4.3.10.**

Liver showing embolic showering of bacteria and hemorrhage.







**Figure 4.3.11.**

Liver showing embolic acute necrotizing hepatitis with intralesional bacterial colonies.

#### 4.4. Fatty Liver Disease (Hepatic Lipidosis)

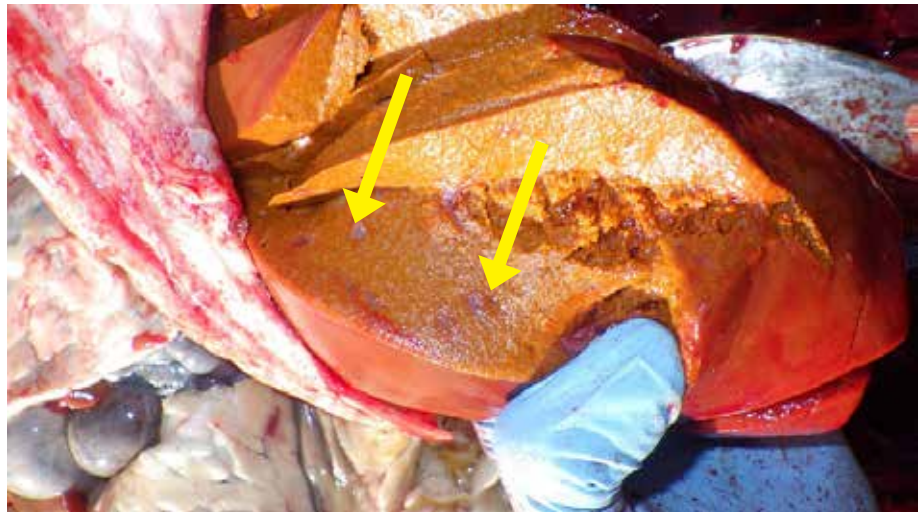
**Figure 4.4.1.**

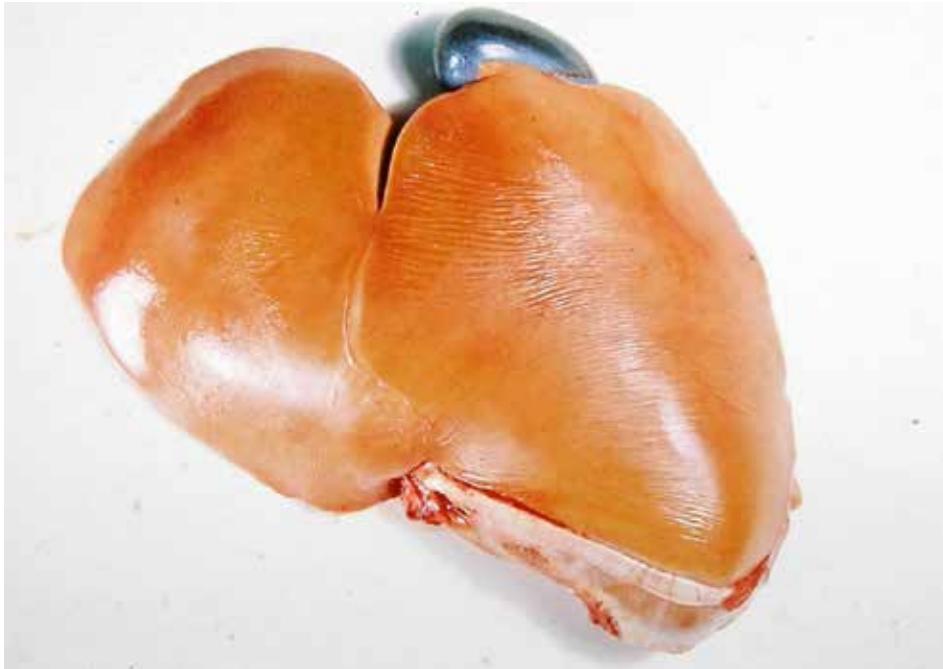Yellow fatty liver in a lamb.



**Figure 4.4.2.**

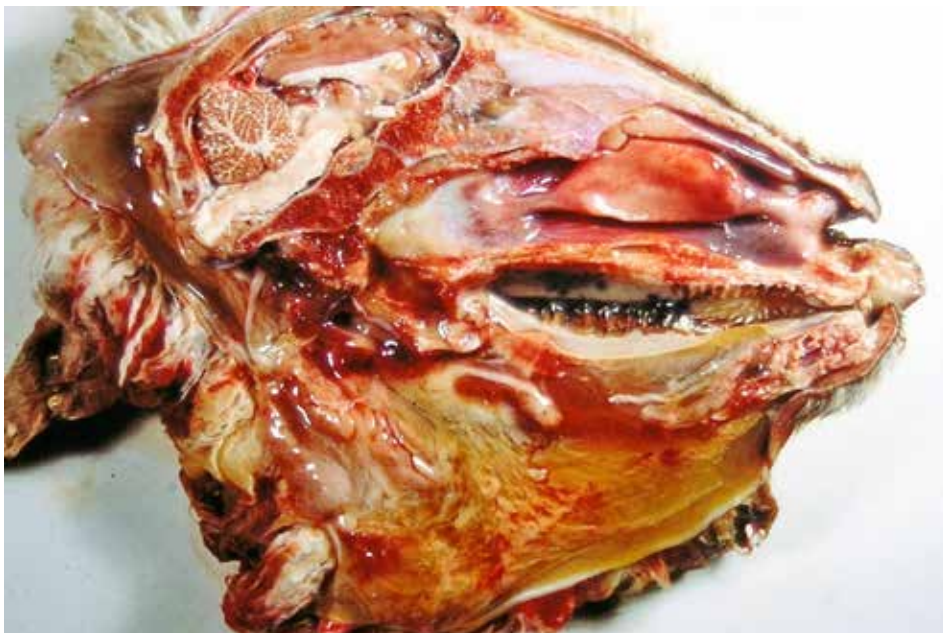Hepatic Lipidosis in an animal that died of severe bacterial pleuropneumonia, pericarditis and septicemia. Necrotic areas can be seen in the liver parenchyma.





**Figure 4.4.3.**

Lamb with white liver disease had a yellow fatty liver. It is associated with cobalt deficiency.



**Figure 4.4.4.**

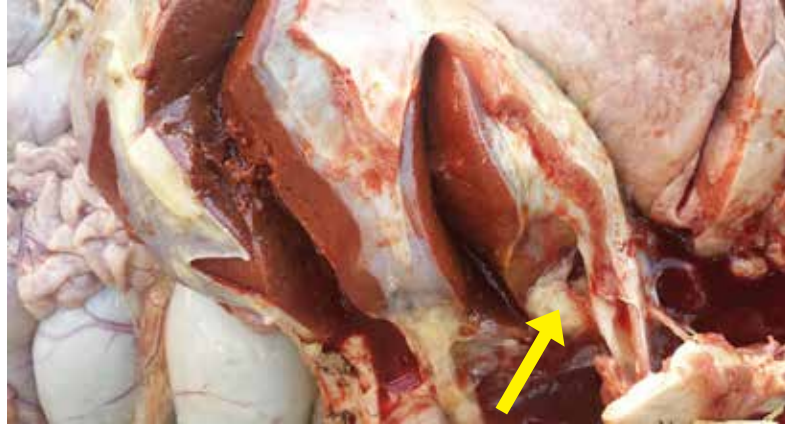Lambs affected with white liver disease showing head with yellow discoloration of tissues.



## 4.5. Caudal Vena Cava Thrombosis

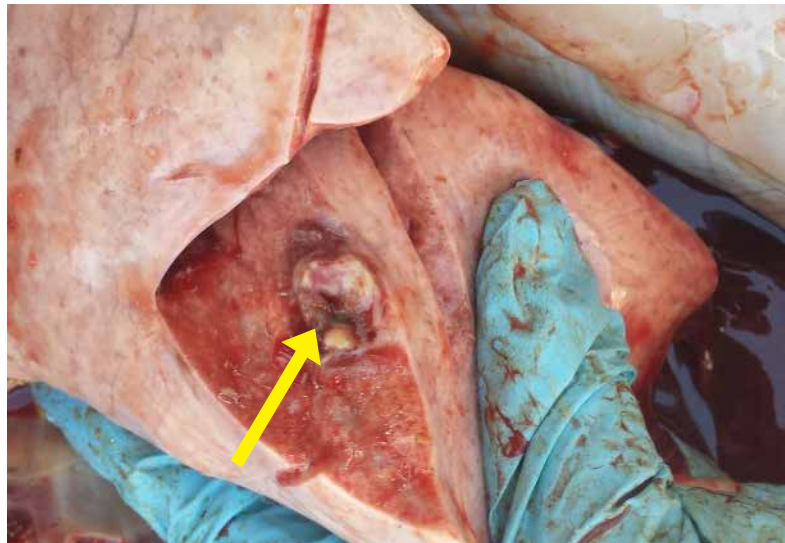
**Figure 4.5.1.**

Abscess in the liver that grew into the caudal vena cava and showered pus and bacteria to the lung. Typically known as caudal vena cava thrombosis.



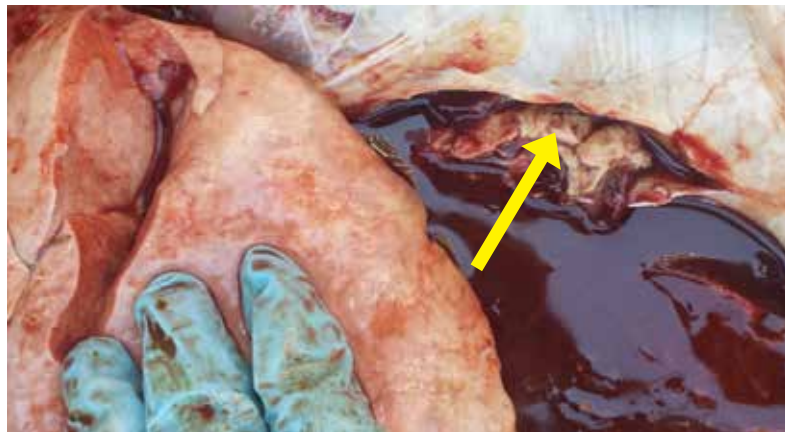**Figure 4.5.2.**

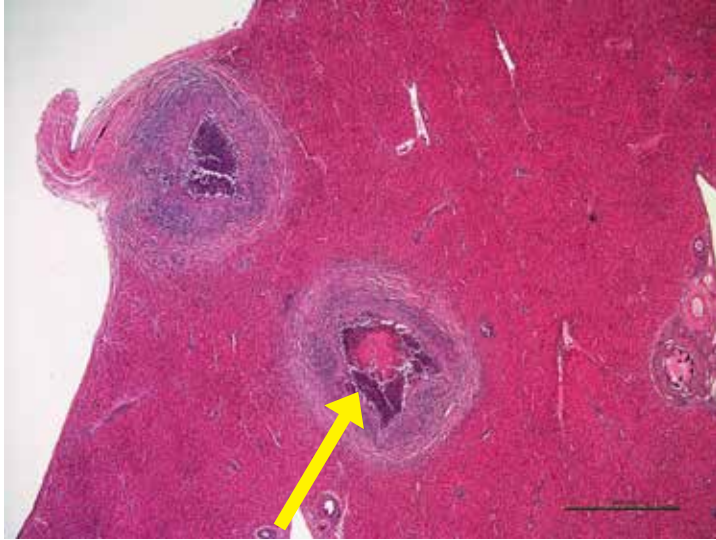Abscess in the lung due to showering of bacterial emboli from the liver.



**Figure 4.5.3.**

Caudal Vena Cava full of pus from a liver abscess that ruptured into the blood vessel.





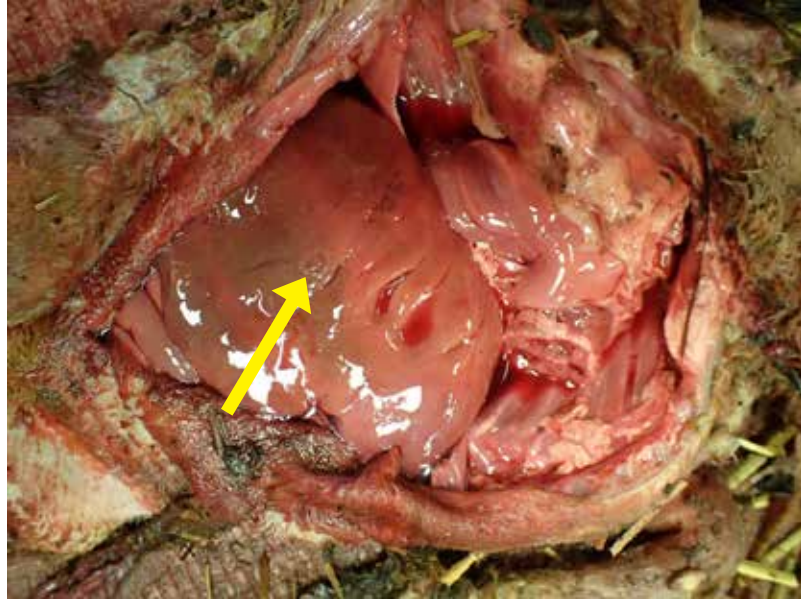
**Figure 4.5.4.**

Low power view of abscesses in the liver.

## 4.6. Campylobacteriosis

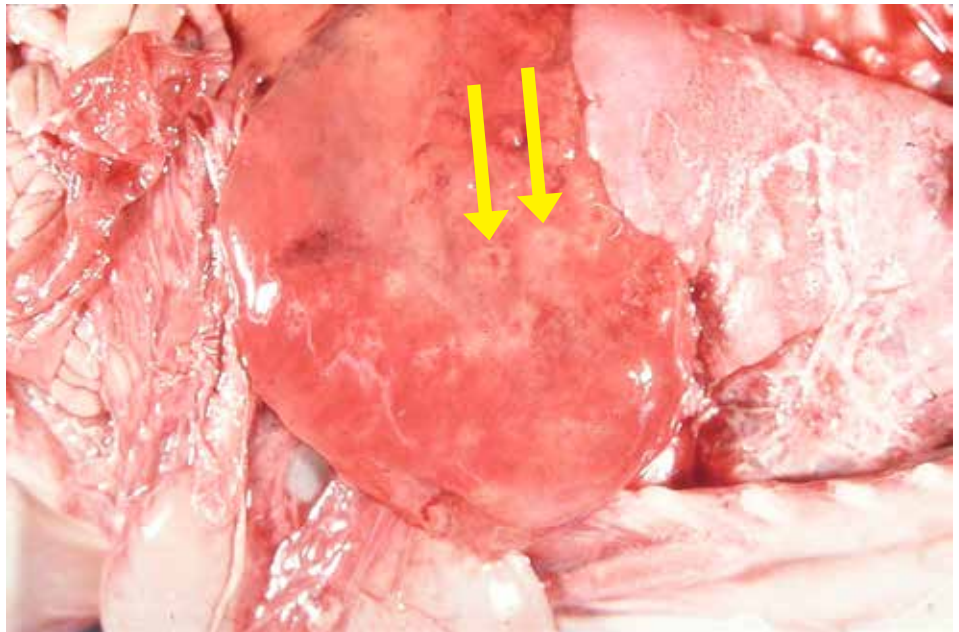
**Figure 4.6.1.**

Liver from an aborted lamb showing swollen liver and multifocal, circular areas of hepatic necrosis.

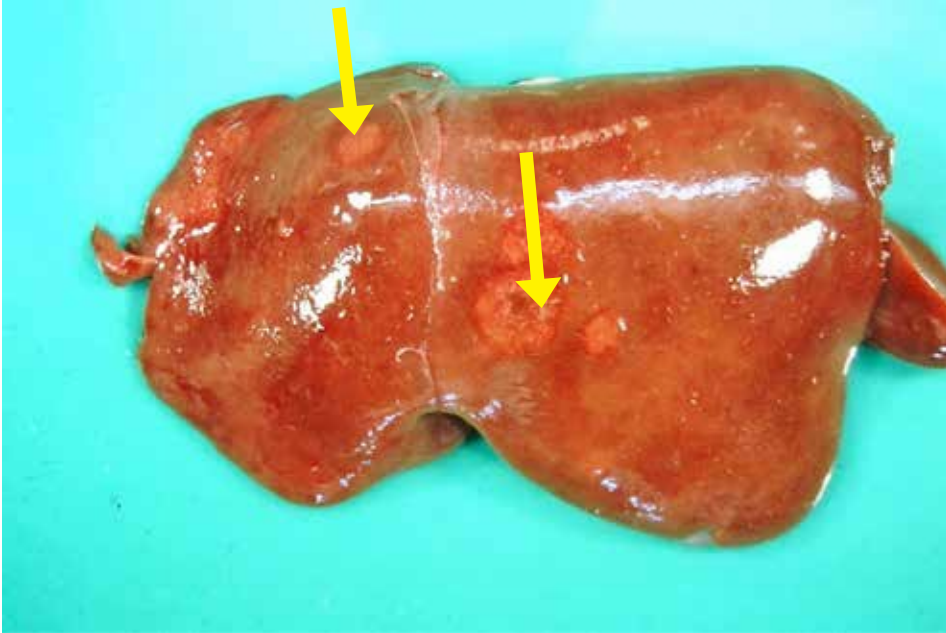


**Figure 4.6.2.**

Liver from an aborted lamb showing swollen liver with multifocal, circular areas of hepatic necrosis.

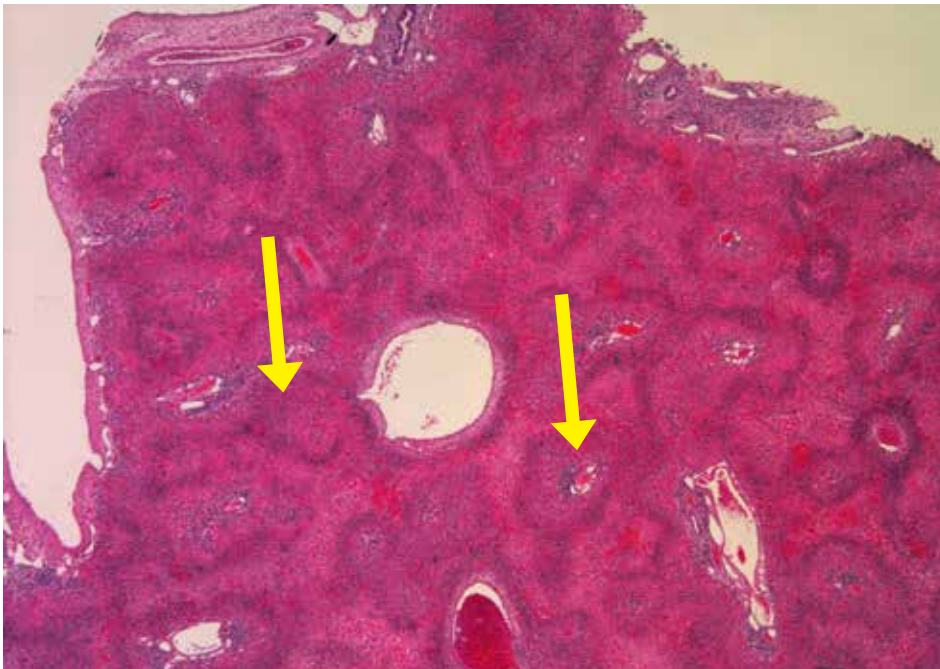






**Figure 4.6.3.**

Liver from an aborted lamb showing swollen liver multifocal, circular areas of hepatic necrosis.



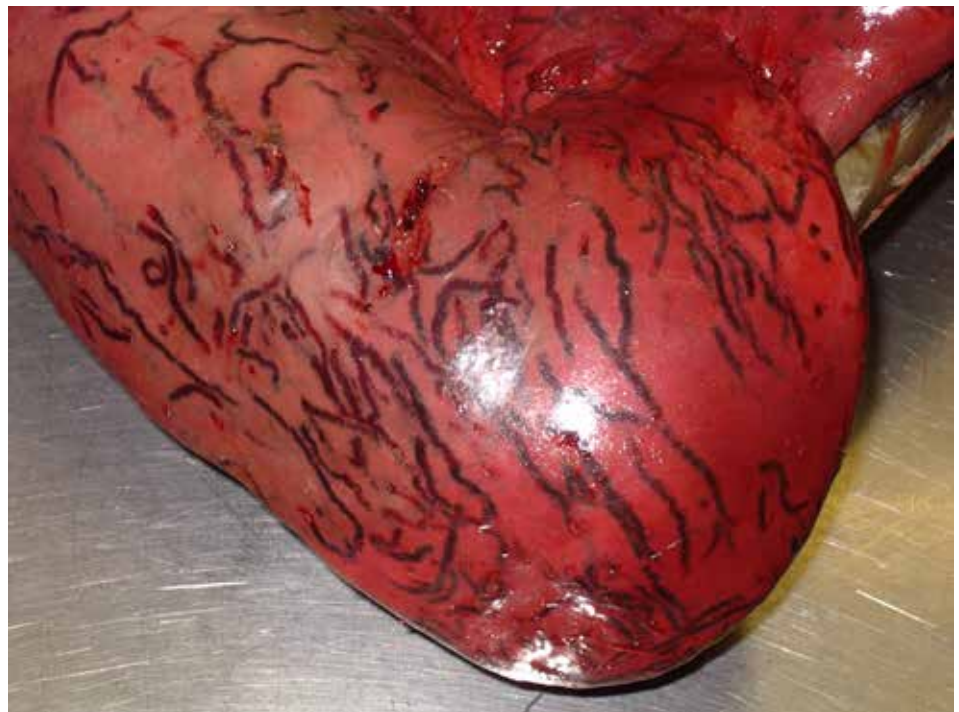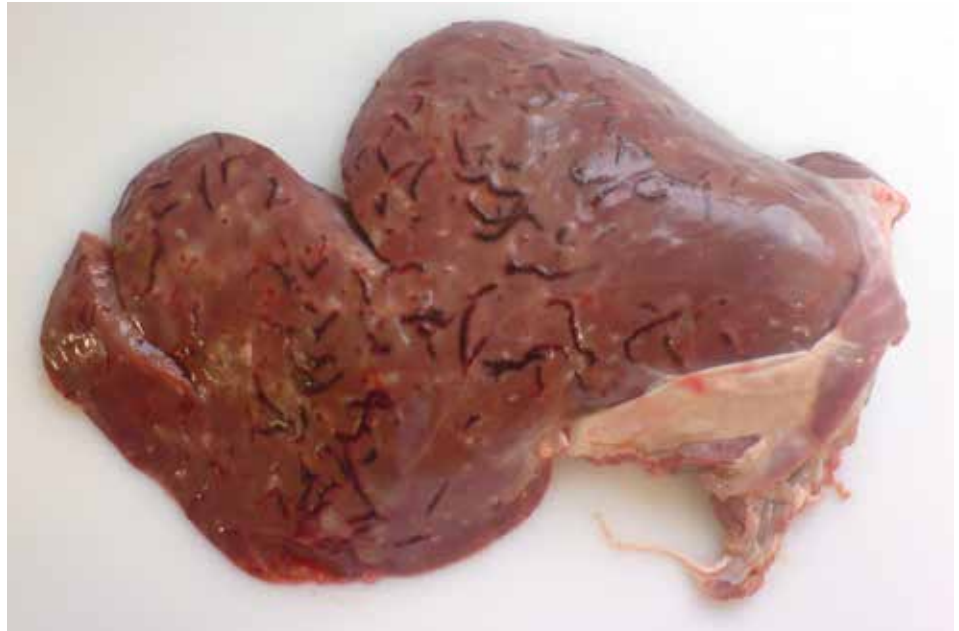**Figure 4.6.4.**

Liver from a lamb aborted due to *Campylobacter jejuni* showing multifocal to coalescing areas of necrosis (arrows).

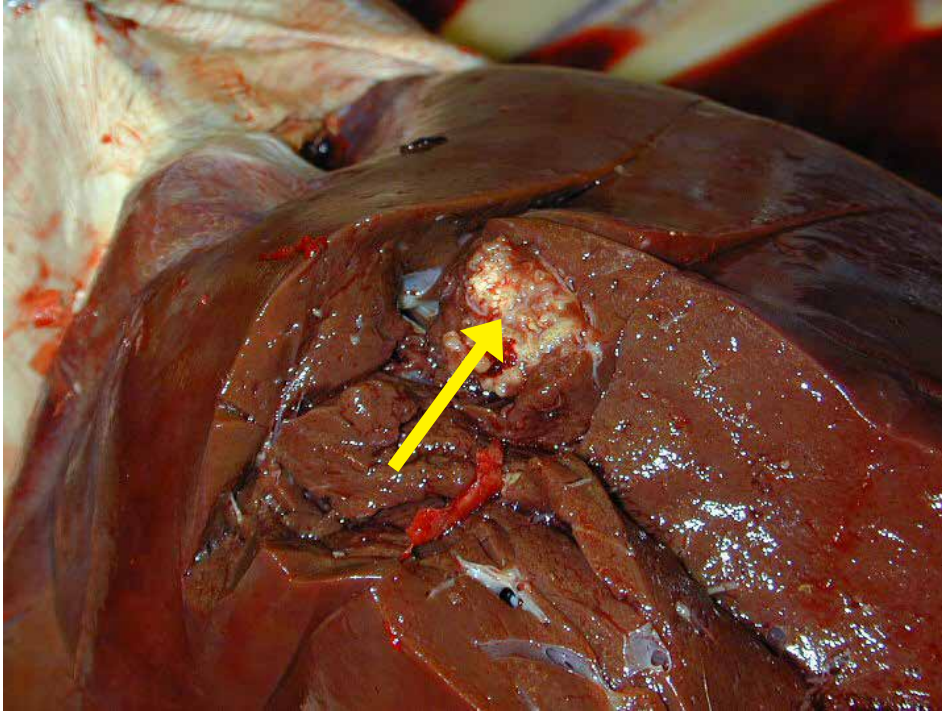
## 4.7. Hepatic Cesticercosis

**Figure 4.7.1.**

Liver from lambs showing tapeworm larvae (*Taenia ovis*) migration tracts.  
*Photos courtesy of P. Menzies.*



## 4.8. Caseous Lymphadenitis



**Figure 4.8.1.**

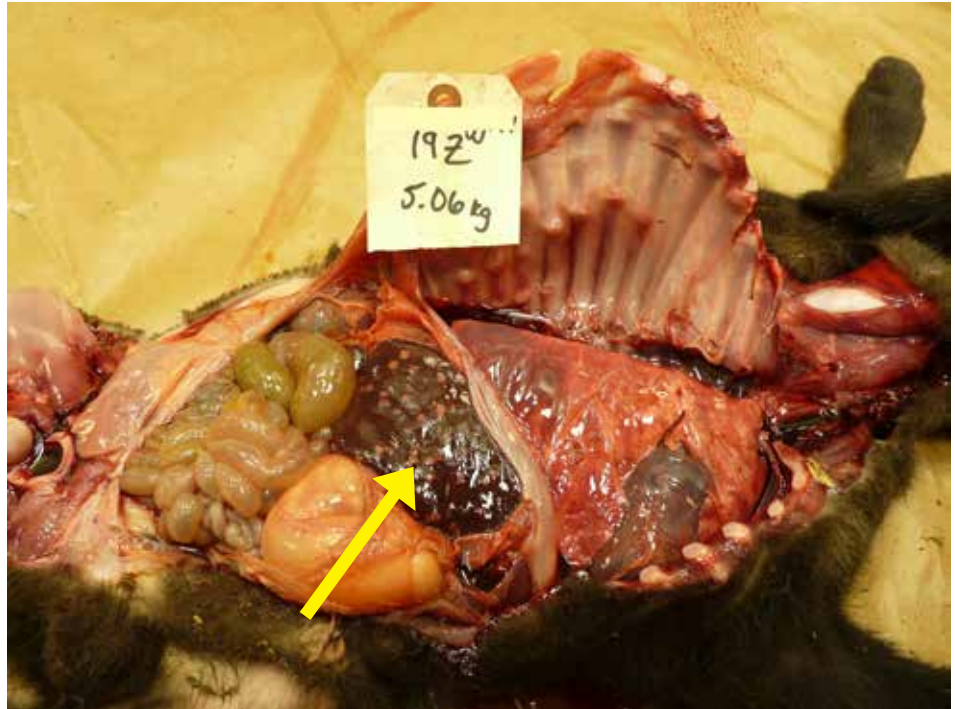
Caseous lymphadenitis (CL) in an ewe showing focalized abscess (arrow) in the liver.  
*Photo courtesy of P. Menzies.*

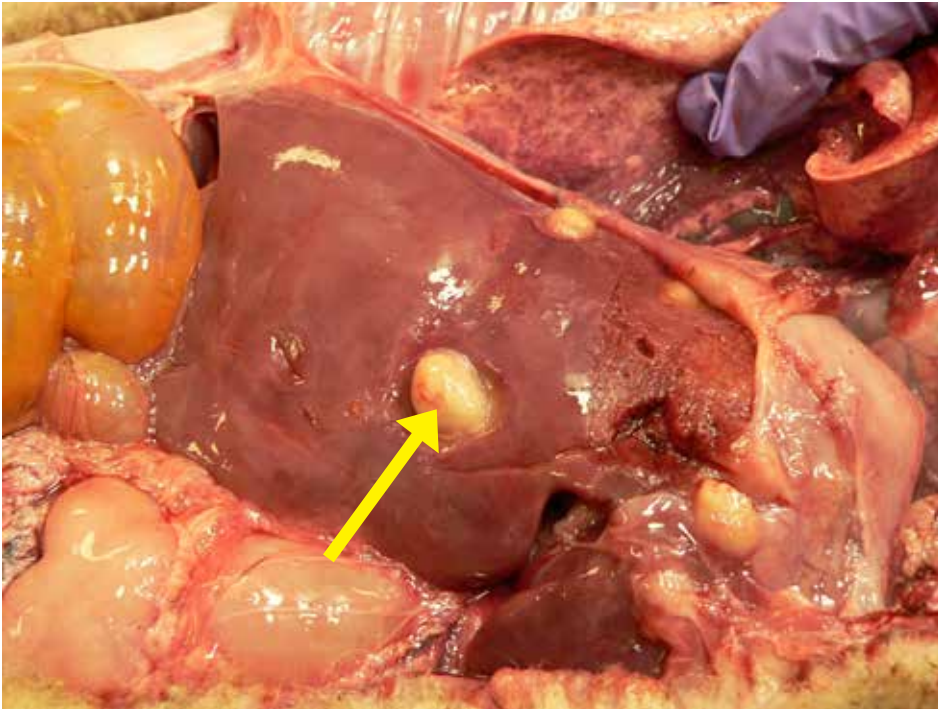


## 4.9. Hepatic Necrobacillosis

**Figure 4.9.1.**

Liver with multiple abscesses (arrow). Disease caused by bacteria called *Fusobacterium necrophorum*.  
*Photo courtesy of P. Menzies.*





**Figure 4.9.2.**

Liver with large abscesses  
(arrow).

*Photo courtesy of P. Menzies.*

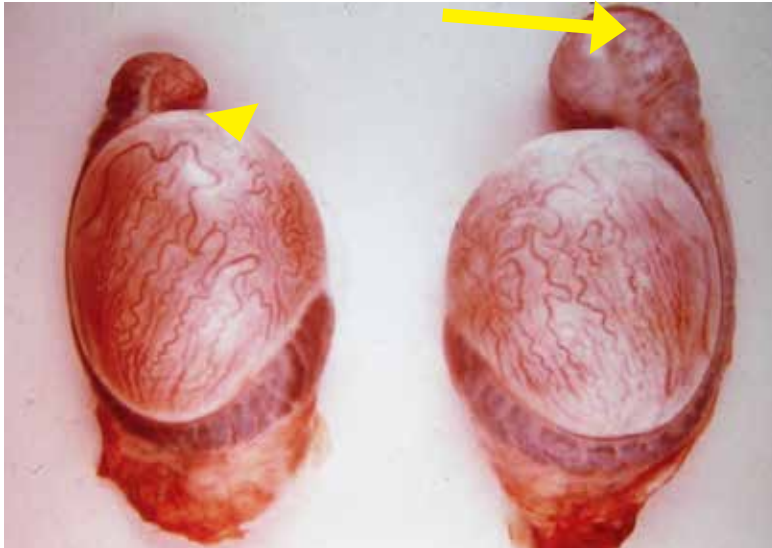
## VI. REPRODUCTIVE AND ENDOCRINE SYSTEMS

1. Epididymitis .....	174
2. Metritis/Pyometra .....	177
3. Abortion/Stillbirth .....	178
4. Enzootic Abortion (Chlamydiosis) .....	181
5. Campylobacteriosis (Vibriosis).....	185
6. Goiter .....	189
7. Border Disease .....	191
8. Cache Valley Virus.....	192
9. Q fever (Coxiellosis).....	194



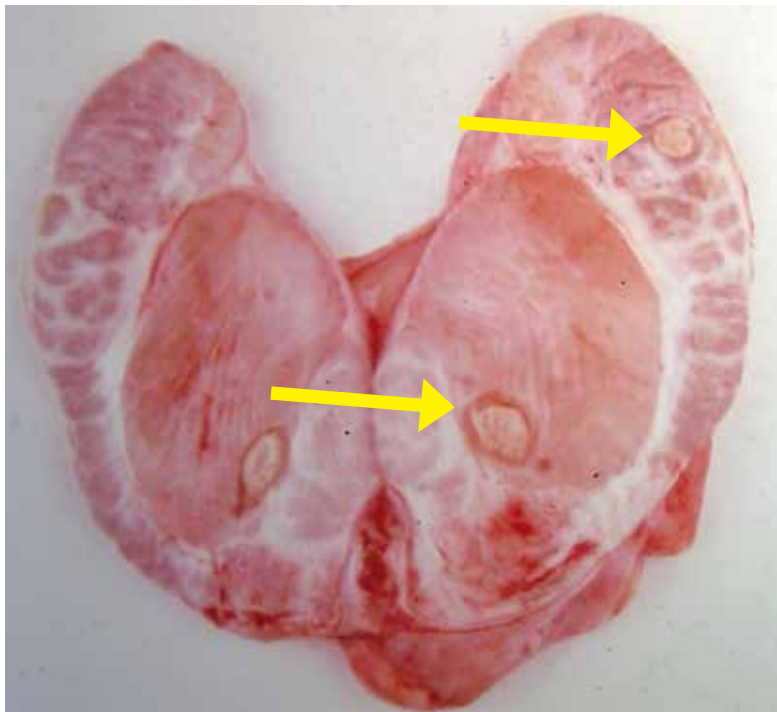
## VI. REPRODUCTIVE AND ENDOCRINE SYSTEMS

### 6.1. Epididymitis



**Figure 6.1.1.**

Testicles showing epididymitis in a ram. Left side (arrow head) – Normal testes. Right side image showing enlarged tail portion of epididymis (arrow). *Brucella ovis* was identified from the testes.

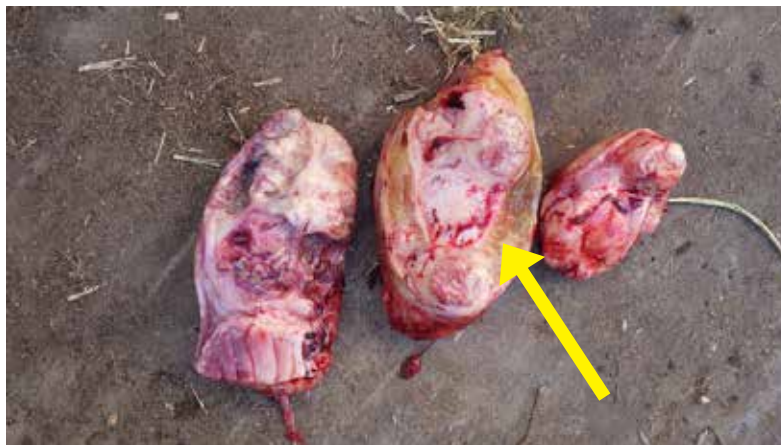

**Figure 6.1.2.**

Orchitis in a ram showing cut section of affected testes and epididymis with areas of necrosis (arrows).

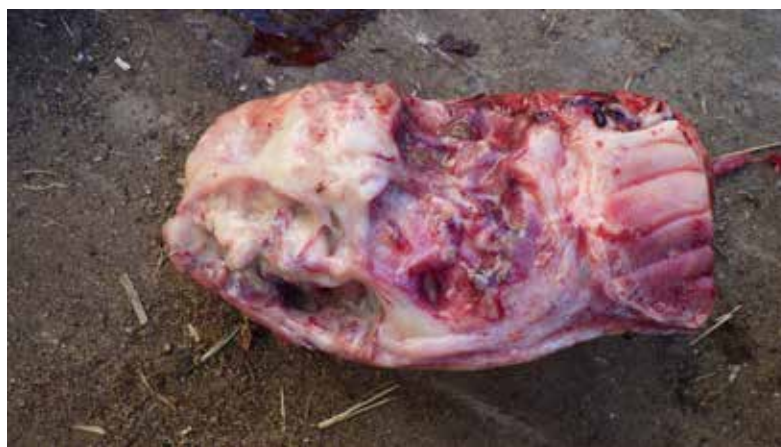**Figure 6.1.3.**

Epididymitis and edema noted around the scrotum.



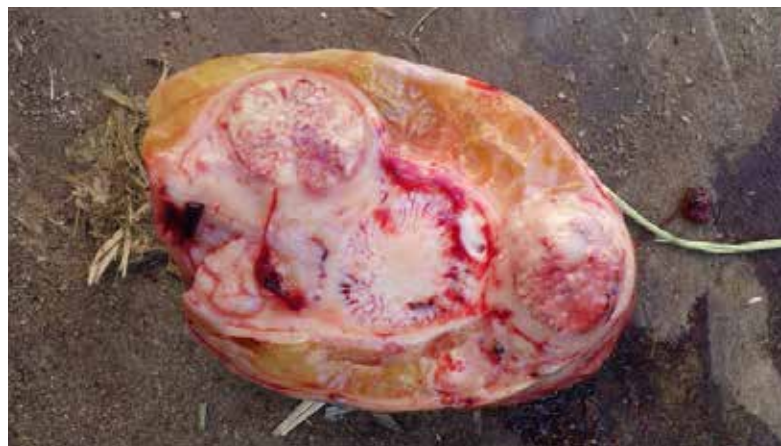**Figure 6.1.4.**

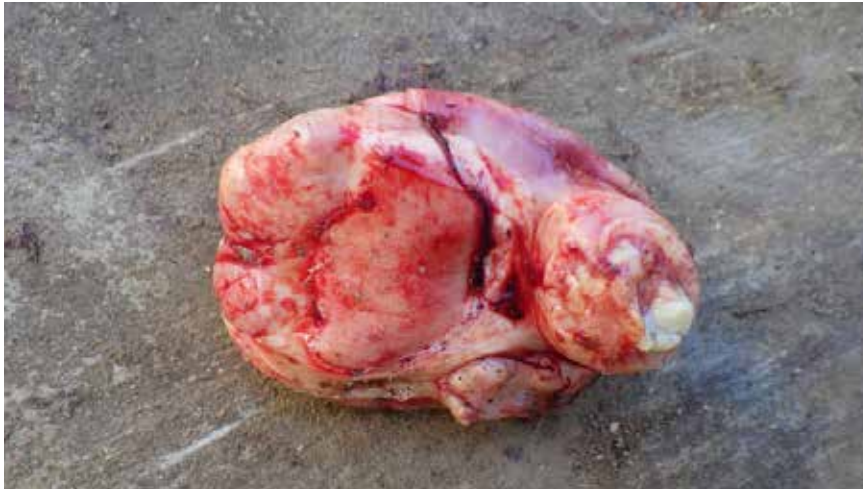Epididymitis in a ram.



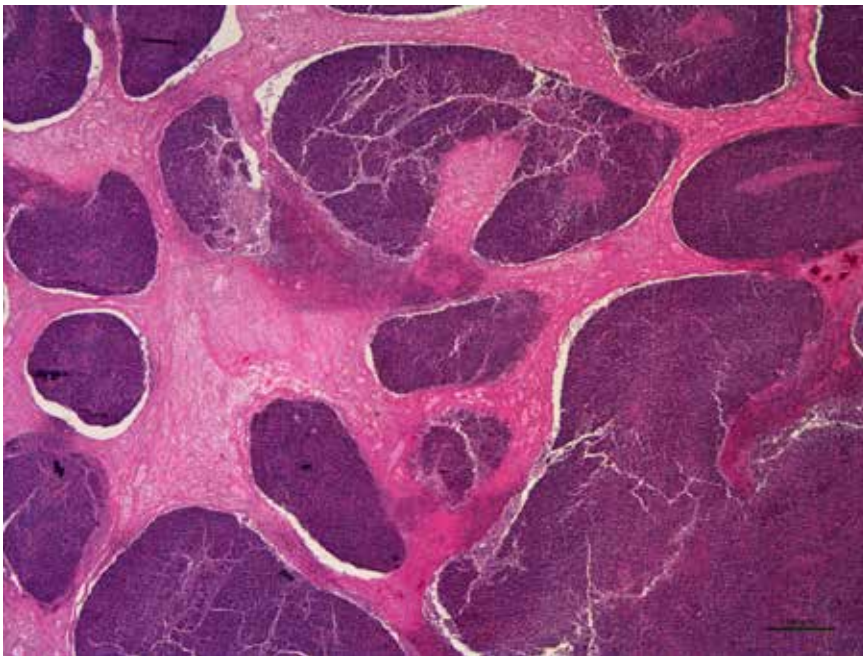
**Figure 6.1.5.**

Epididymitis.





**Figure 6.1.6.**  
Epididymitis.



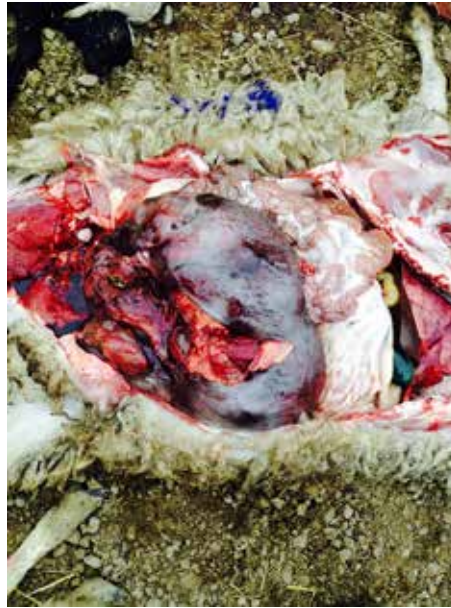**Figure 6.1.7.**  
Chronic suppurative epididymitis in a lamb showing large aggregates of neutrophils. The tissue tested positive for *Mycoplasma* species. No significant pathogenic bacteria isolated from bacterial culture of testes.



## 6.2. Metritis/Pyometra

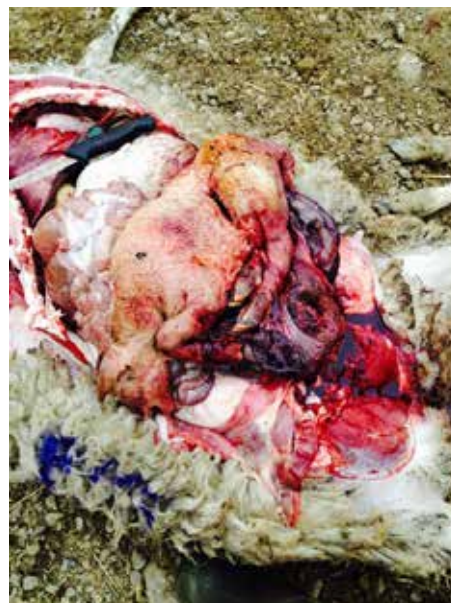**Figure 6.2.1.**

Metritis with dead lamb  
within uterus.



**Figure 6.2.2.**

Metritis with autolyzed fetus.

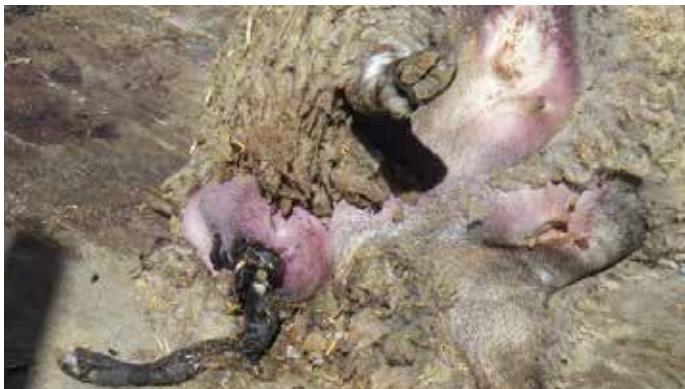

### 6.3. Abortion / Stillbirth



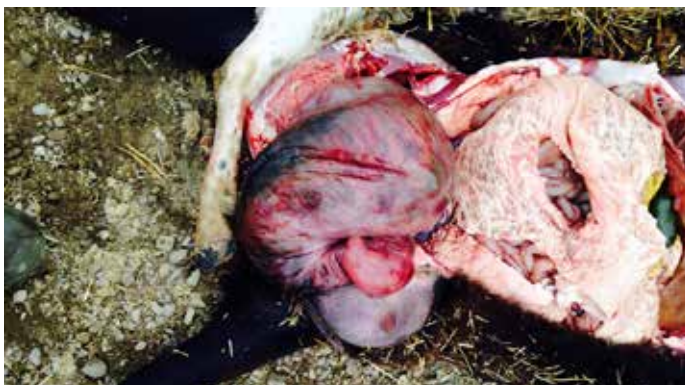**Figure 6.3.1.**

Ewe died while lambing. Note purple udder indicating toxemia.



**Figure 6.3.2.**

Dead lamb protruding from vulva.



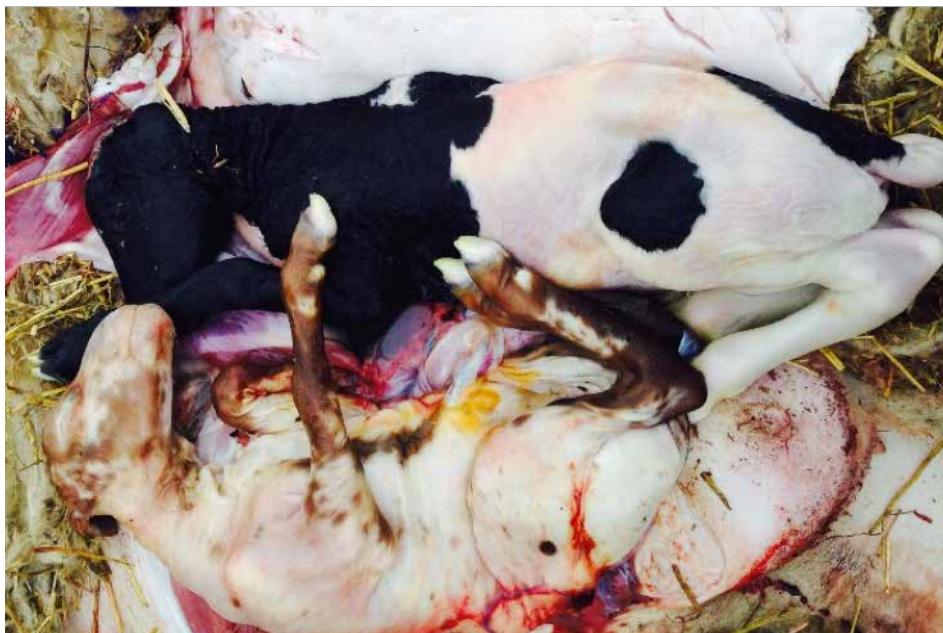**Figure 6.3.3.**

Uterus hemorrhagic and necrotic with dead lamb within.



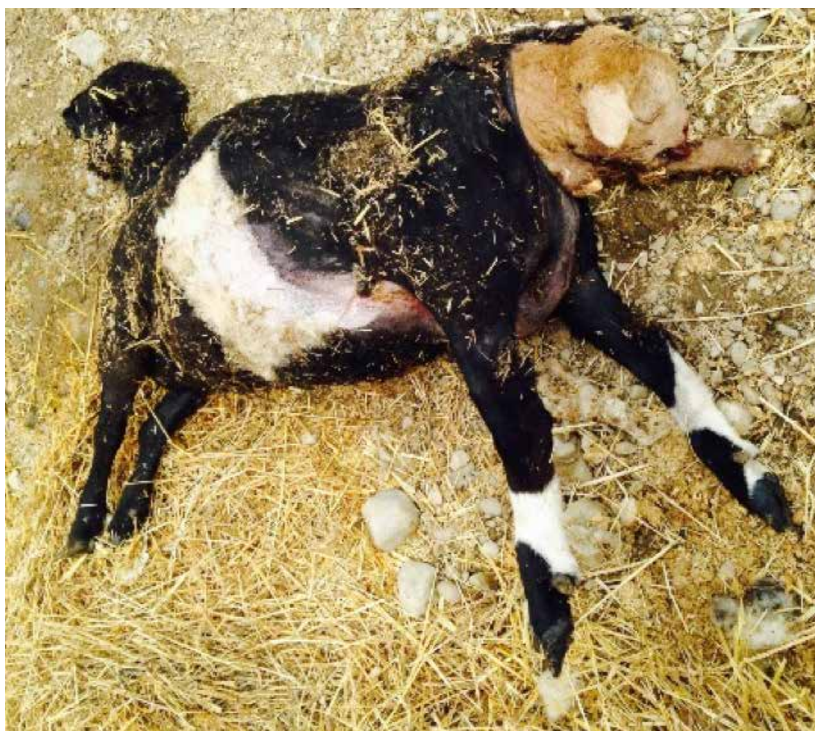**Figure 6.3.4.**

Twins coming through the pelvis at the same time, or intertwined, can cause dystocia.

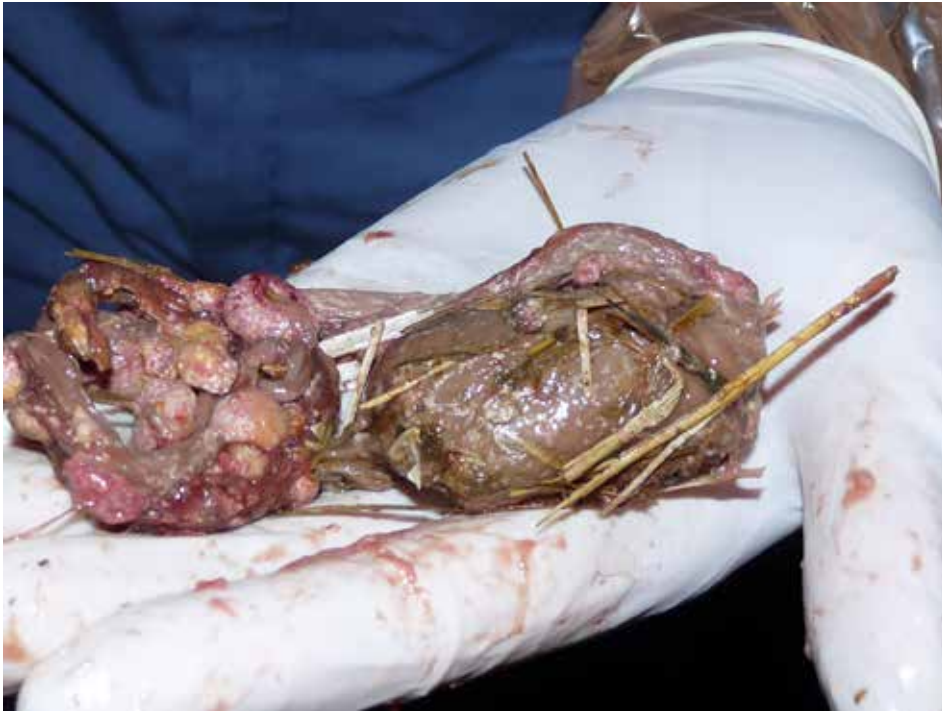

**Figure 6.3.5.**

Appears to have “elbow lock” – it is important to repel fetuses before trying to change a malposture as the birth canal in sheep is very small.







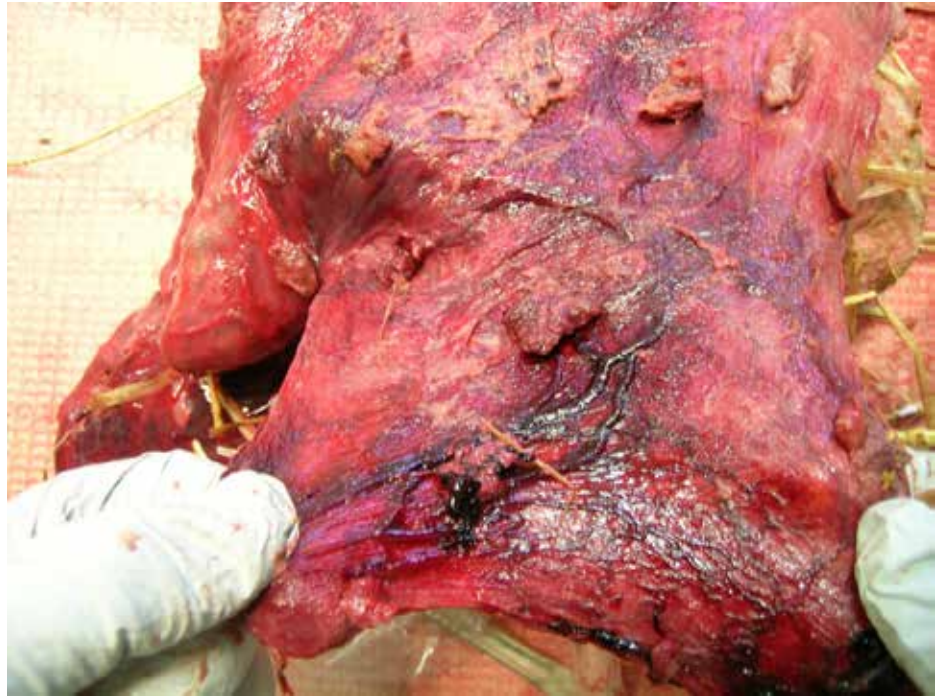
**Figure 6.3.6.**

Toxoplasma abortion.  
*Photo courtesy of P. Menzies.*

## 6.4. Enzootic Abortion (Chlamydiosis)

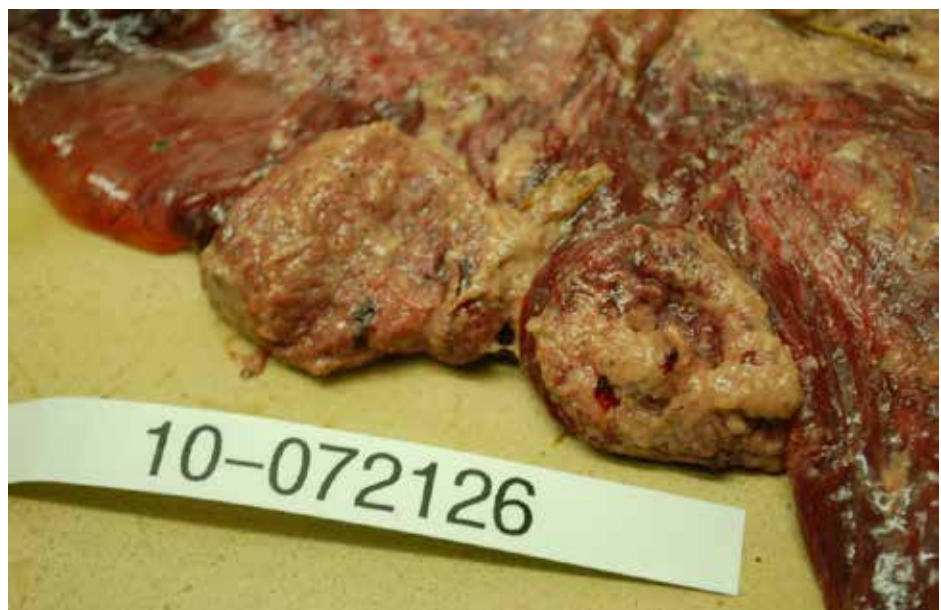**Figure 6.4.1.**

Placenta from an aborted ewe due to chlamydiosis (Enzootic Abortion). Note thickened intercotyledonary areas that is covered with inflammatory exudate admixed with necrotic material, and necrotic cotyledons. Normal intercotyledonary membranes should be translucent and pale. The tissues tested positive for *Chlamydia abortus* by PCR.

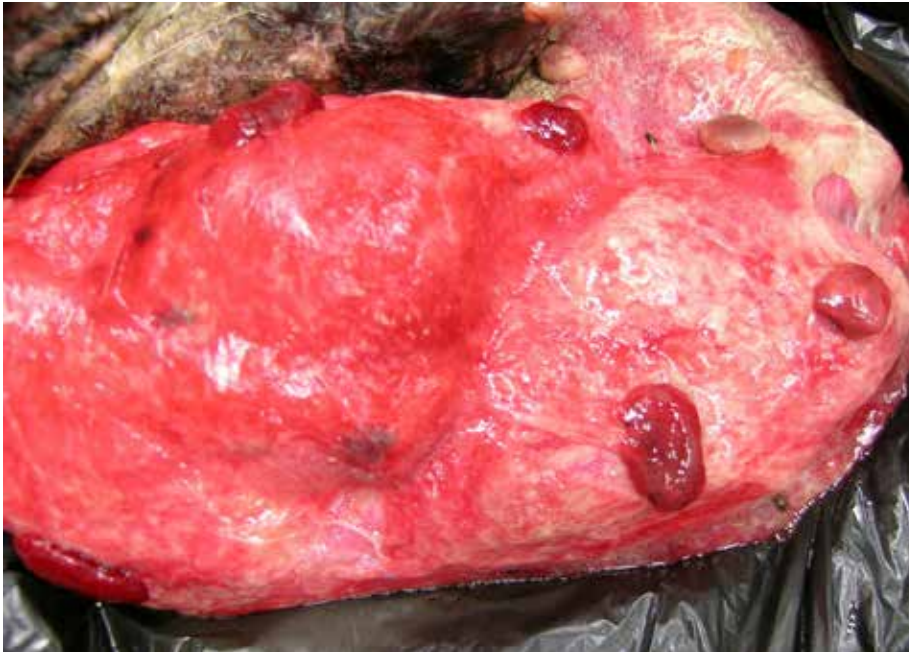

**Figure 6.4.2.**

Chlamydia abortion.  
Photo courtesy of  
Dr. Murray Hazlett,  
University Guelph.

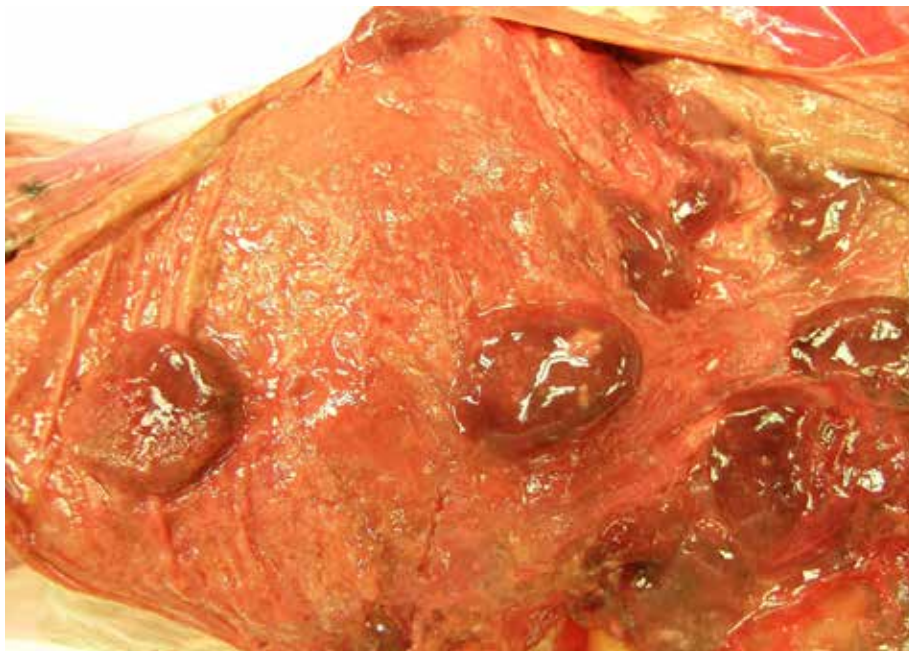






**Figure 6.4.3.**

Placenta from an aborted ewe due to Chlamydiosis. Intercotyledonary areas are thickened and opaque, and cotyledons are congested and edematous with necrotic center. The tissues tested positive for *Chlamydomphila abortus* by PCR.



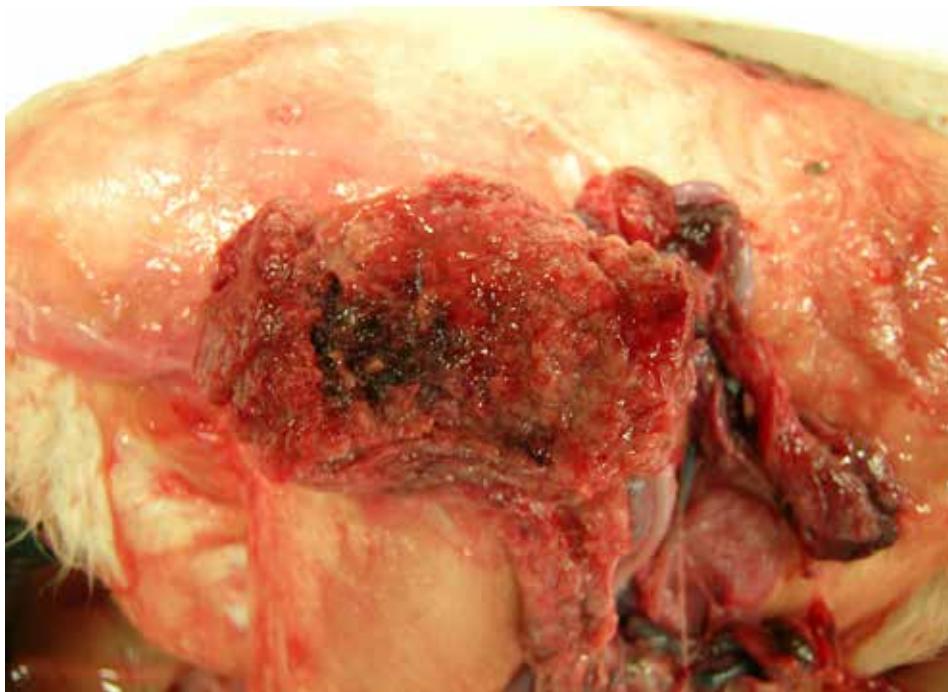
**Figure 6.4.4.**

Placenta from an aborted ewe due to chlamydiosis. Intercotyledonary areas are thickened and opaque, and covered with exudate. Cotyledons were edematous and necrotic. The tissues tested positive for *Chlamydomphila abortus* by PCR.



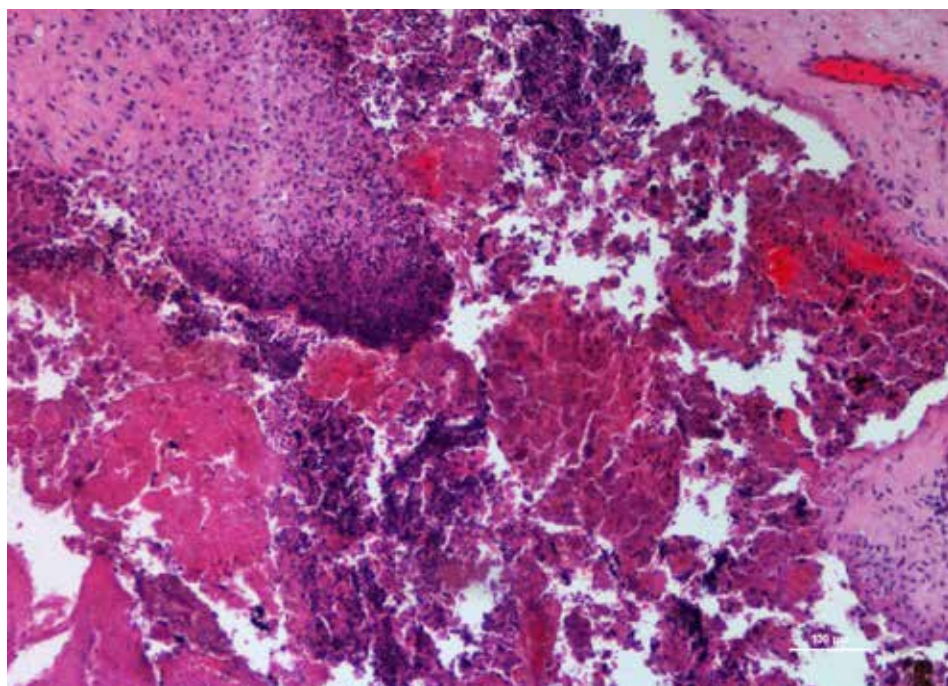
**Figure 6.4.5.**

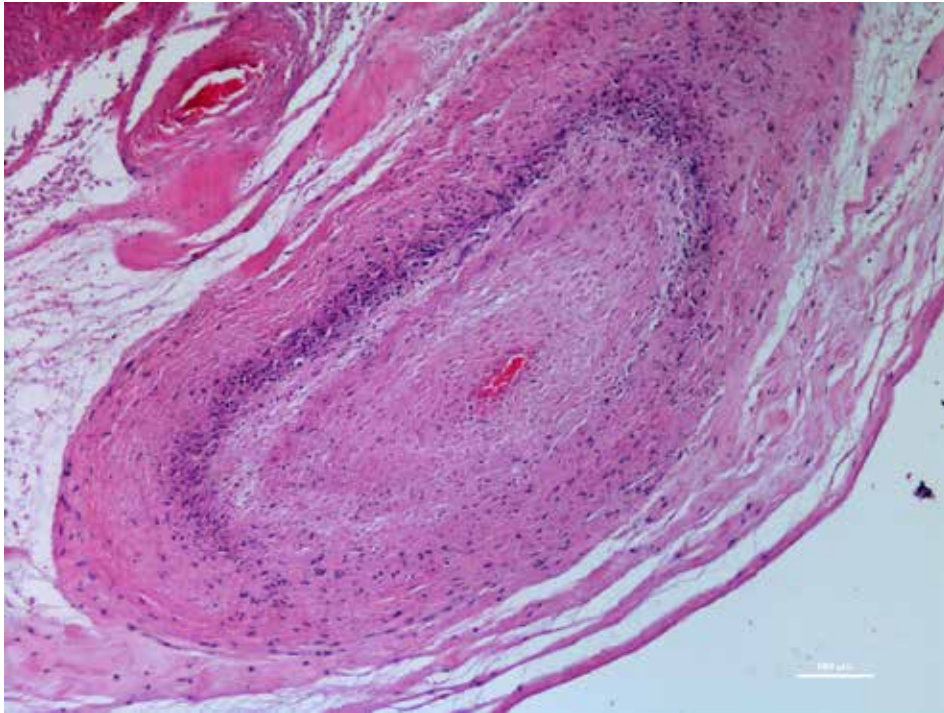
Placenta from an aborted ewe due to chlamydiosis. Close-up view of necrotic and hemorrhagic cotyledon.



**Figure 6.4.6.**

Placenta from an aborted ewe due to Chlamydiosis (Enzootic Abortion). Histologically severe necrotizing placentitis was evidenced.





**Figure 6.4.7.**

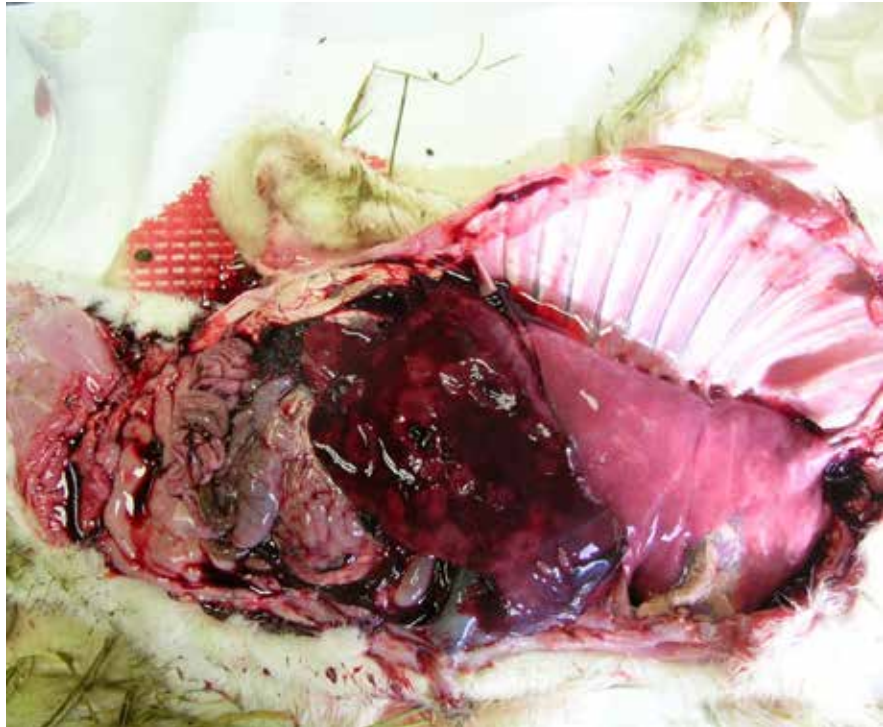
Placentitis with necrotizing vasculitis is more common in lambs aborted due to Chlamydiosis. Occasionally vasculitis can be also seen in placentitis caused by *Coxiella burnetii* and severe bacterial placentitis associated with *Trueperella pyogenes*.



## 6.5. Campylobacteriosis (Vibriosis)

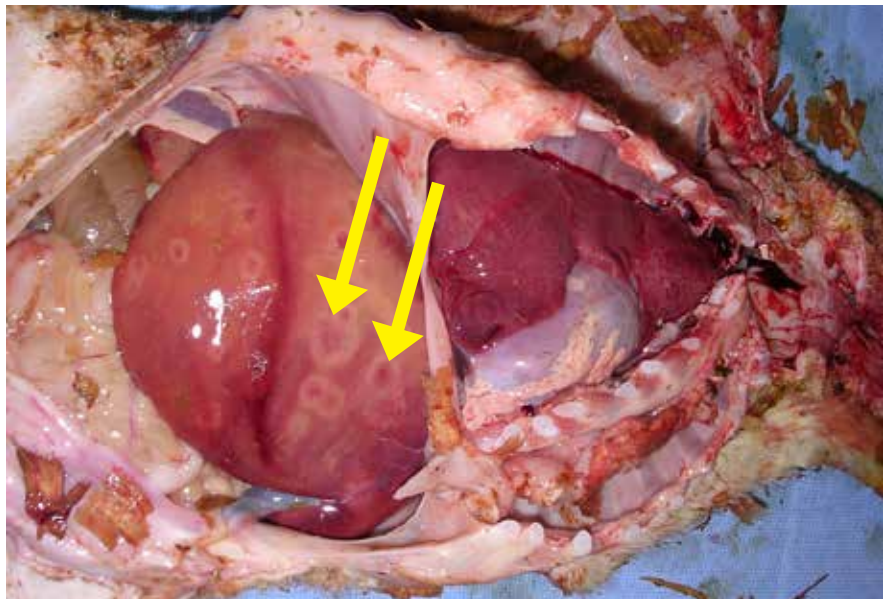
**Figure 6.5.1.**

Lamb fetus aborted due to Campylobacteriosis showing lesions in the liver with multifocal to coalescing areas of hepatic necrosis. There are two different causes of campylobacter abortion: *C. fetus fetus* and *C. jejuni*.

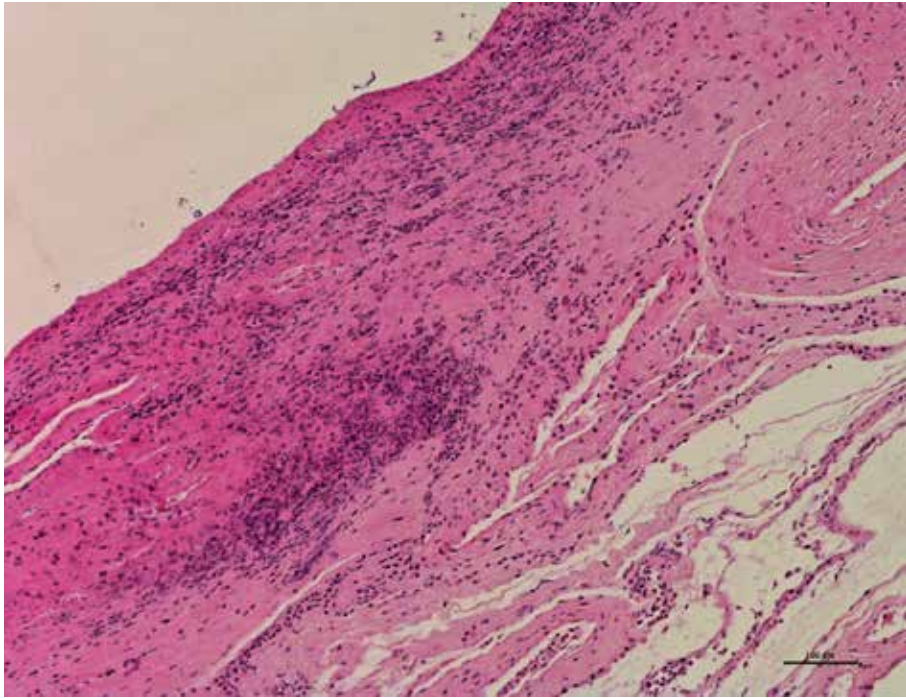


**Figure 6.5.2.**

Liver lesions in an aborted lamb caused by *Campylobacter* sp. Photo courtesy of P. Menzies.

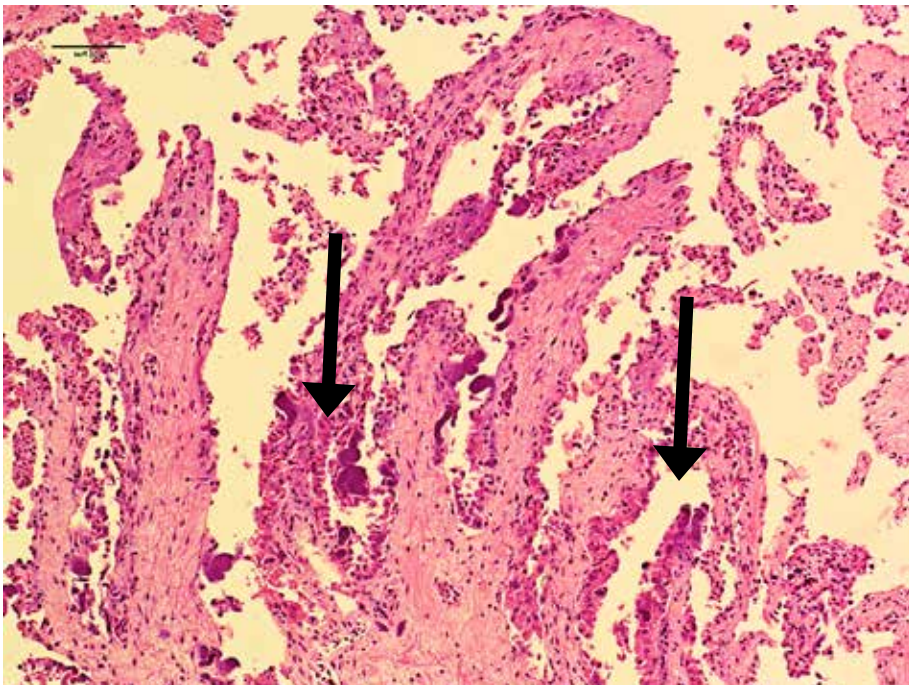






**Figure 6.5.3.**

Placenta from an aborted primiparous ewe. Placenta appear grossly normal. Histologically, there is multifocal mild necrosis and inflammation of chorionic villi. No vasculitis was noted. Placenta tested positive for *Campylobacter jejuni*.



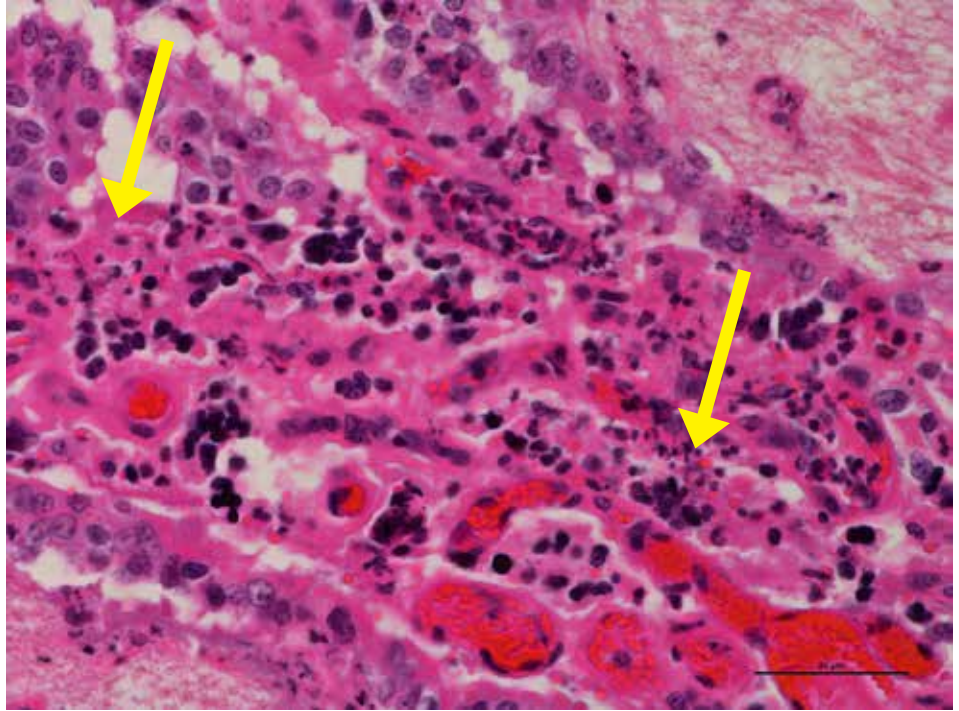
**Figure 6.5.4.**

Placenta showing mild suppurative placentitis with multifocal mineralization. (arrow) PCR testing of placenta confirmed *Campylobacter fetus subsp fetus*.



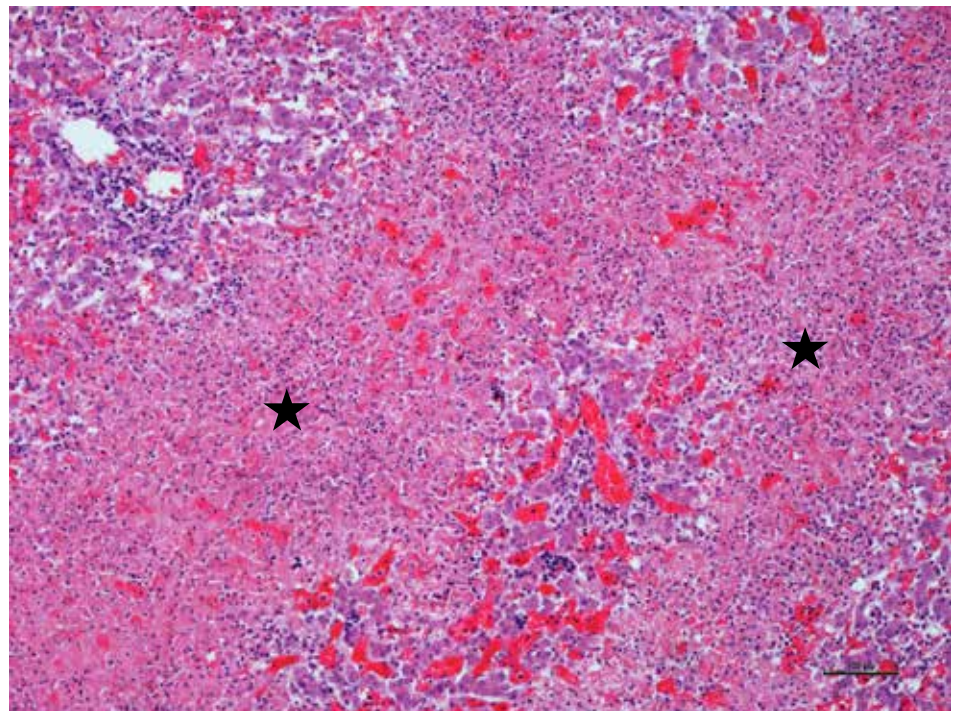
**Figure 6.5.5.**

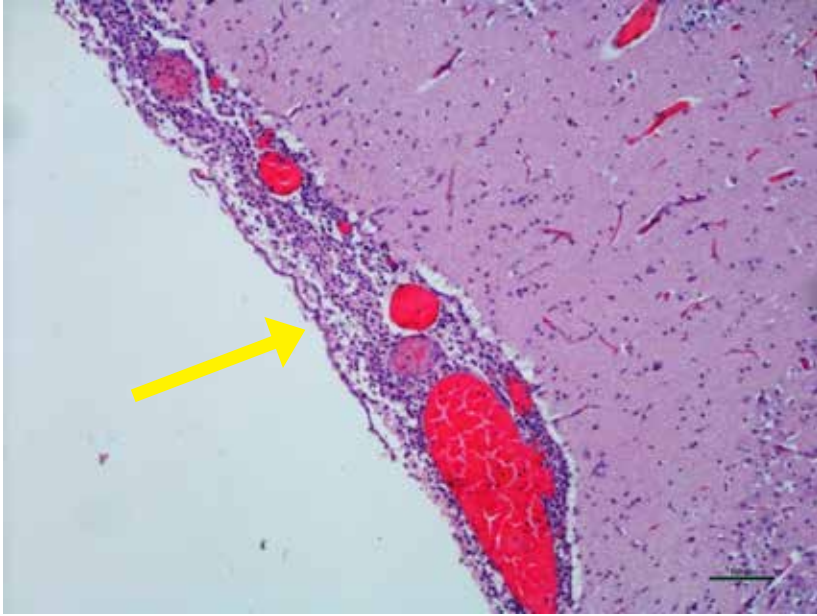
High power view of same placenta showing suppurative placentitis and chorionic villi necrosis. PCR testing of placenta confirmed *Campylobacter fetus subsp fetus*.



**Figure 6.5.6.**

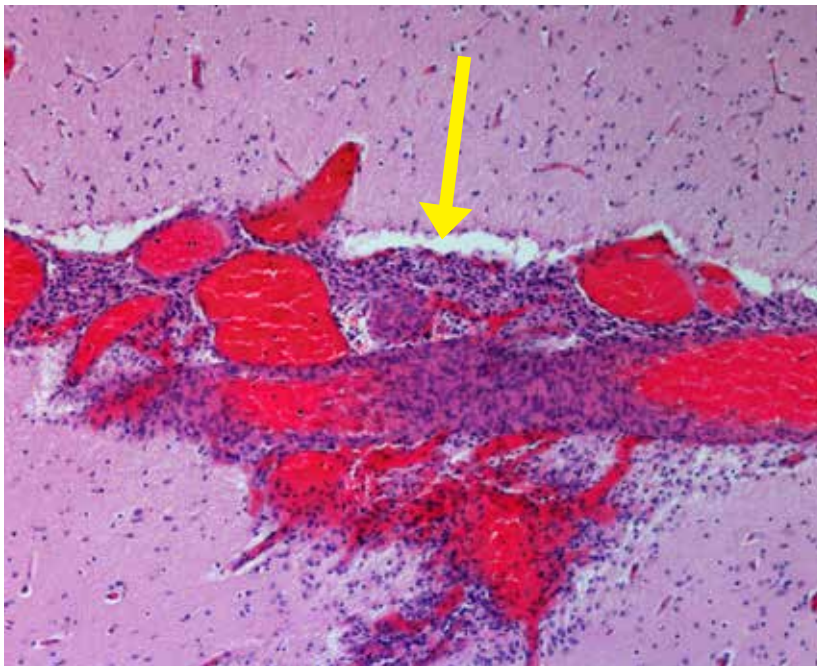
Liver from lamb fetus aborted due to campylobacteriosis showing extensive areas (stars) of hepatic necrosis.





**Figure 6.5.7.**

Lamb fetus – brain showing lymphoplasmacytic meningitis. Mild enteritis was also noted in the fetus. Placenta tested positive for *Campylobacter fetus*.



**Figure 6.5.8.**

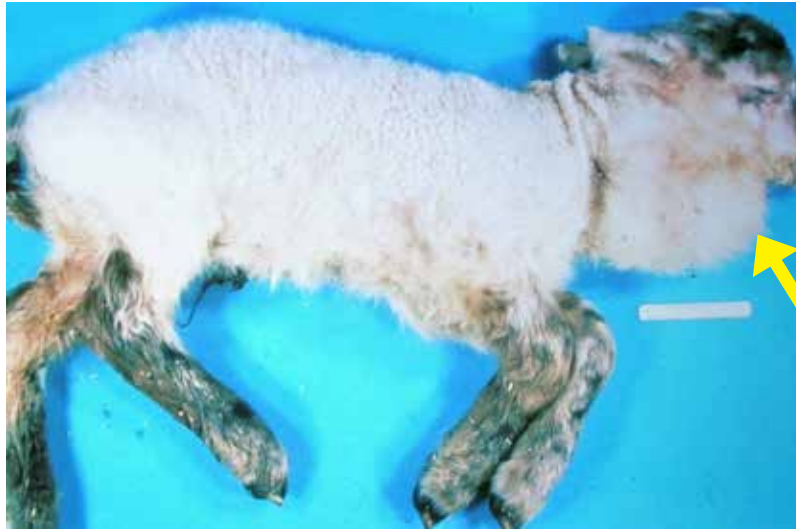Meningitis can be seen rarely in lambs aborted due to Chlamydiosis and Campylobacteriosis.



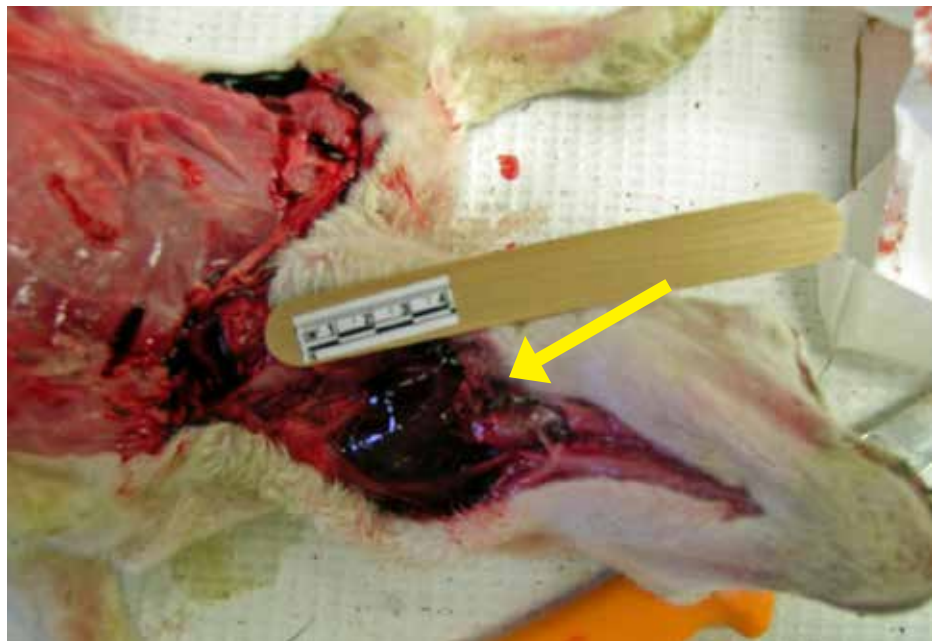
## 6.6. Goiter

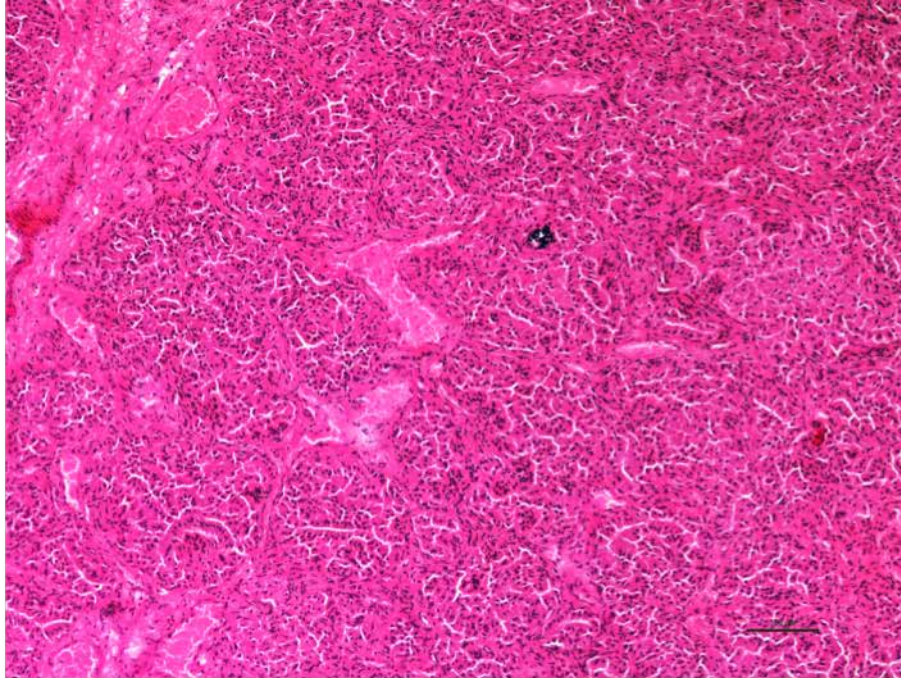
**Figure 6.6.1.**

Enlarged neck area in a lamb due to enlarged thyroid glands on both sides.

**Figure 6.6.2.**

Goiter in a new born lamb showing bilaterally enlarged thyroid glands.





**Figure 6.6.3.**

Lamb thyroid: Histologically, there is diffuse follicular hyperplasia with absence of secretory material (colloid) as is seen in lambs born with goiter.

## 6.7. Border Disease

**Figure 6.7.1.**

Image showing two litter mates. Dark one had Border disease (hairy shaker) and shed BDV persistently and the littermate was healthy and did not shed virus.  
*Photo courtesy of P. Menzies.*



**Figure 6.7.2.**

Close-up image of sheep effected with Border disease showing pigmented hairy wool over the shoulders and neck.  
*Photo courtesy of P. Menzies.*



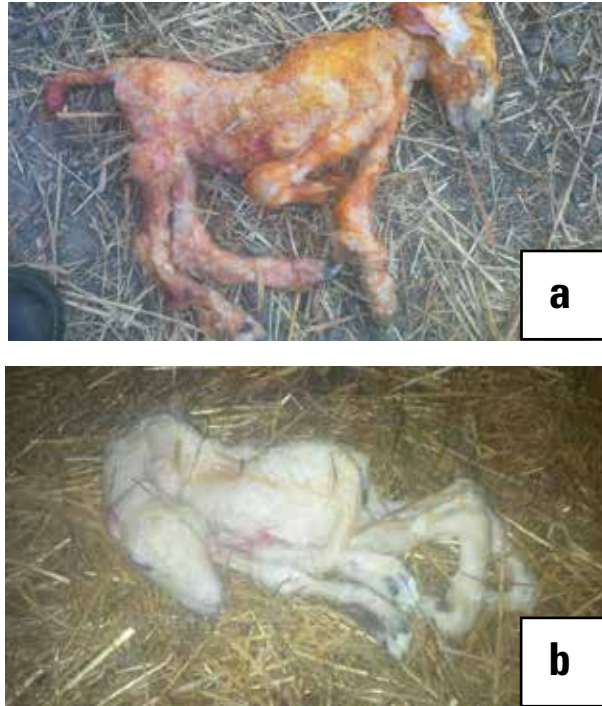
**Figure 6.7.3.**

Close-up Image of lamb effected with Border disease showing foreshortened facial skeleton.  
*Photo courtesy of P. Menzies.*





## 6.8. Cache Valley Virus



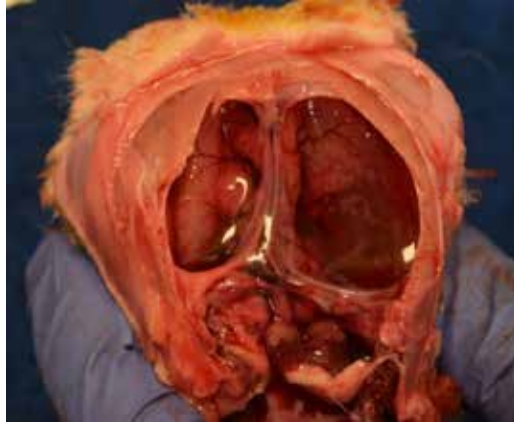**Figure 6.8.1a. & b.**

Lambs aborted due to Cache Valley virus showing various musculoskeletal abnormalities such as kyphosis (curvature of spine), arthrogryposis (crooked joints) and poor development of musculature. These lambs will also have central nervous system defects. Akabane virus and Schmallenberg virus infections do not occur in Canada but also produce similar lesions in lambs.

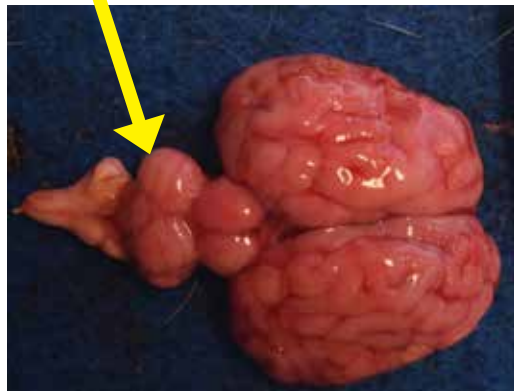
*Photo courtesy of P. Menzies.*

**Figure 6.8.2.**

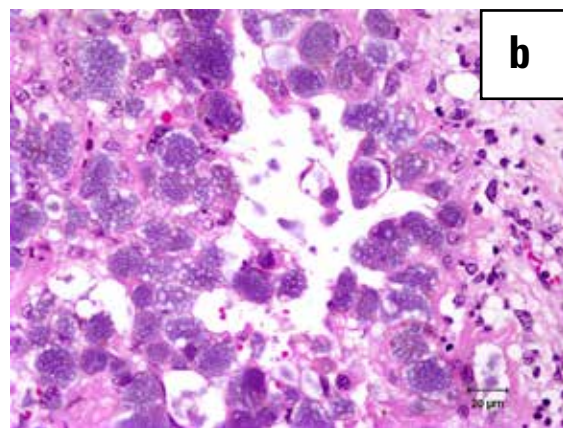
Hydranencephaly (Cerebral hemispheres are absent or poorly developed and replaced by sacs filled with cerebrospinal fluid) in a lamb caused by Cache Valley virus.  
*Photo courtesy of M. Spinato.*

**Figure 6.8.3.**

Brain showing cerebellar hypoplasia (arrow) in a lamb caused by Cache Valley virus.  
*Photo courtesy of M. Spinato.*



## 6.9. Q Fever Abortion



**Figure 6.9.1.**

Gross (a) and microscopic (b) images showing placentitis caused by *Coxiella burnetii*.  
*Photo courtesy of Murray Hazlett, University of Guelph.*



## V. URINARY SYSTEM

1. Urolithiasis (Waterbelly condition).....	158
2. Perirenal Hemorrhage .....	163
3. Hydronephrosis .....	164
4. Bacterial Septicemia .....	165
5. Pyelonephritis .....	167
6. Copper Toxicity.....	169
7. Renal Infarcts .....	171
8. Glomerulonephritis .....	171
9. Pulpy Kidney .....	172

## V. URINARY SYSTEM

### 5.1. Urolithiasis (Waterbelly condition)

Urolithiasis is the formation of stony concretions in the bladder or urinary tract.



**Figure 5.1.1.**

Waterbelly. Swelling under the belly around the prepuce.

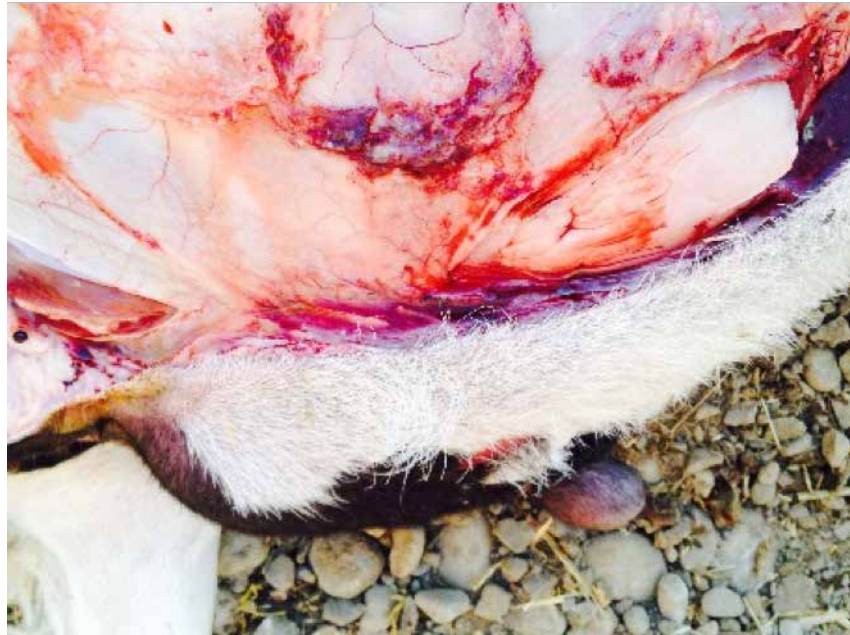

**Figure 5.1.2.**

Swollen prepuce in waterbelly.

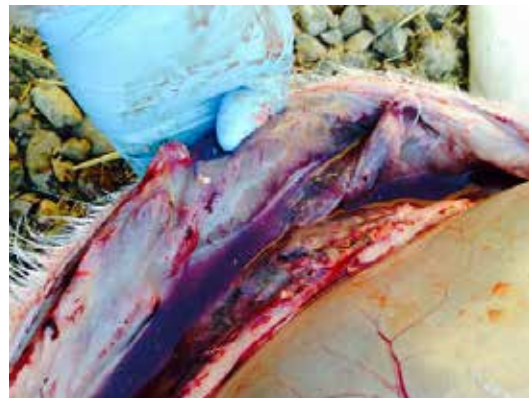**Figure 5.1.3.**

Urine accumulated under prepucial area.

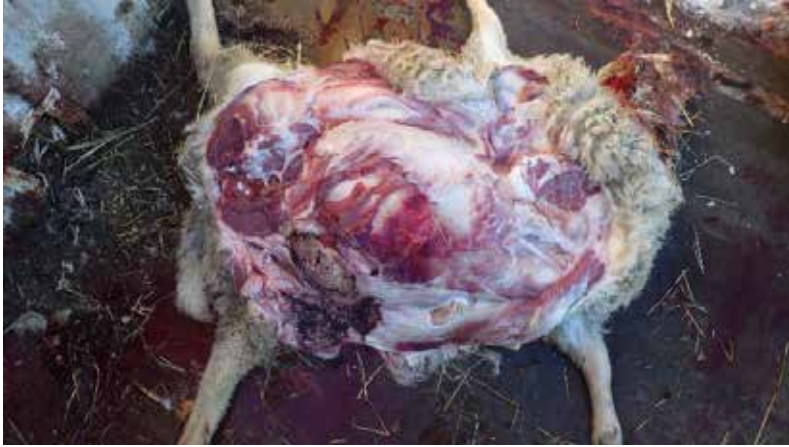

**Figure 5.1.4.**

Urolithiasis in a lamb. A swollen prepuce is the most common clinical sign of a waterbelly and occurs when there is rupture in the urethra and urine enters the subcutaneous tissue.

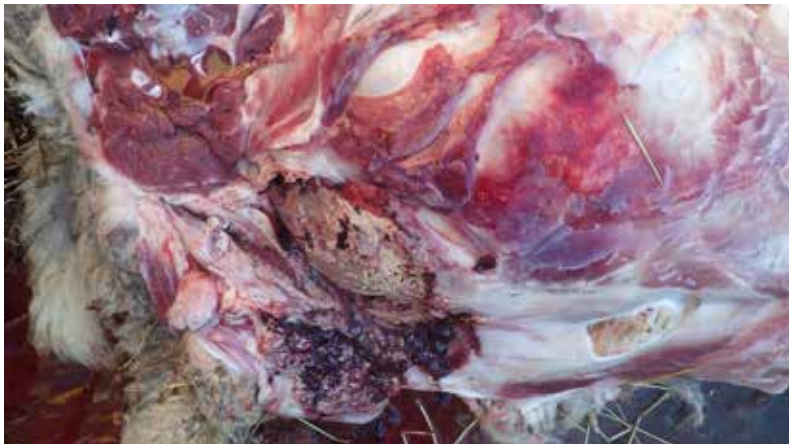





**Figure 5.1.5.**

Urolithiasis in a lamb.  
Hemorrhagic and urine filled  
area under the skin.

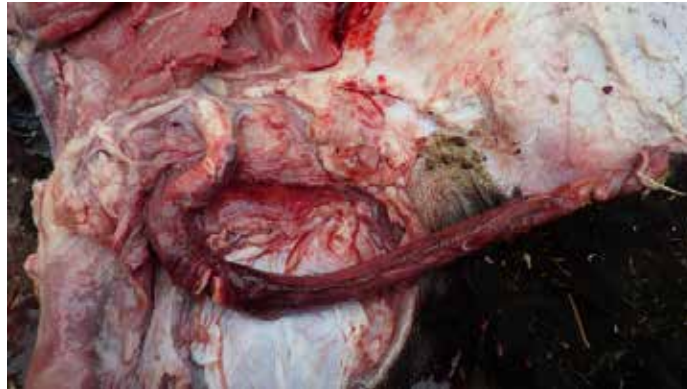

**Figure 5.1.6.**

Urolithiasis in a lamb. Necrosis  
of the subcutaneous tissues in a  
waterbelly.

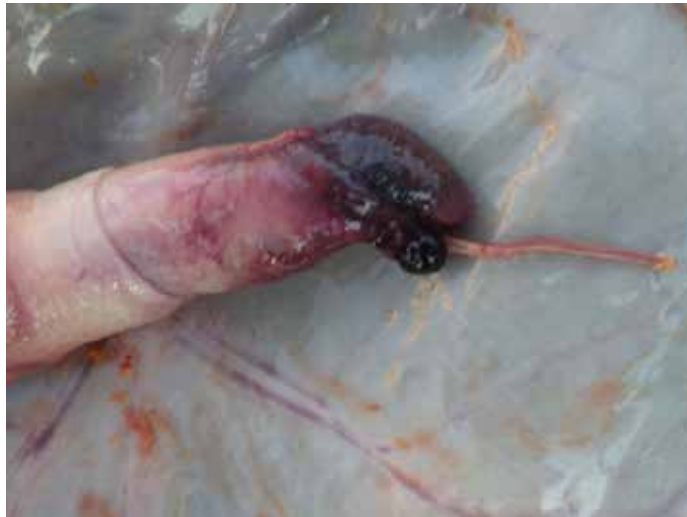**Figure 5.1.7.**

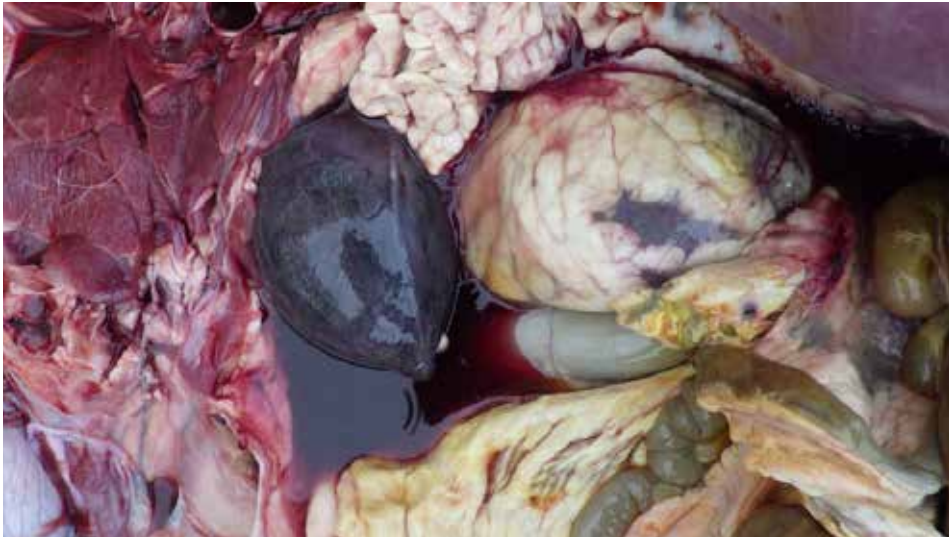
Urolithiasis in a lamb.  
Hemorrhagic penis with stone  
within ureter.



**Figure 5.1.8.**

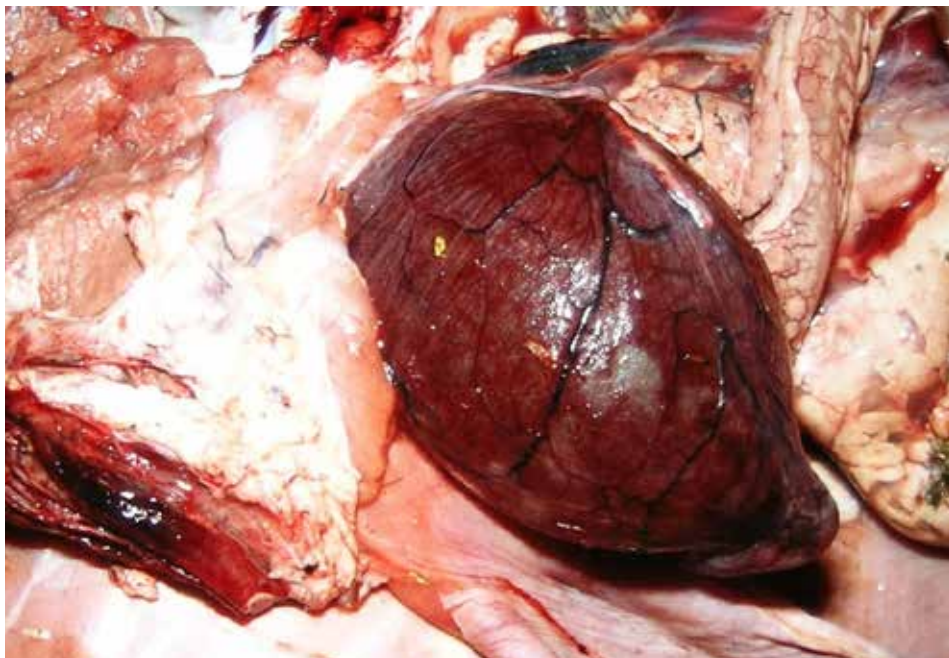
Urolithiasis in a lamb.  
Swollen tip of penile urethra  
where stone often resides.





**Figure 5.1.9.**

Urolithiasis in a lamb. Severe distended reddened urinary bladder. Area round kidney enlarged.



**Figure 5.1.10.**

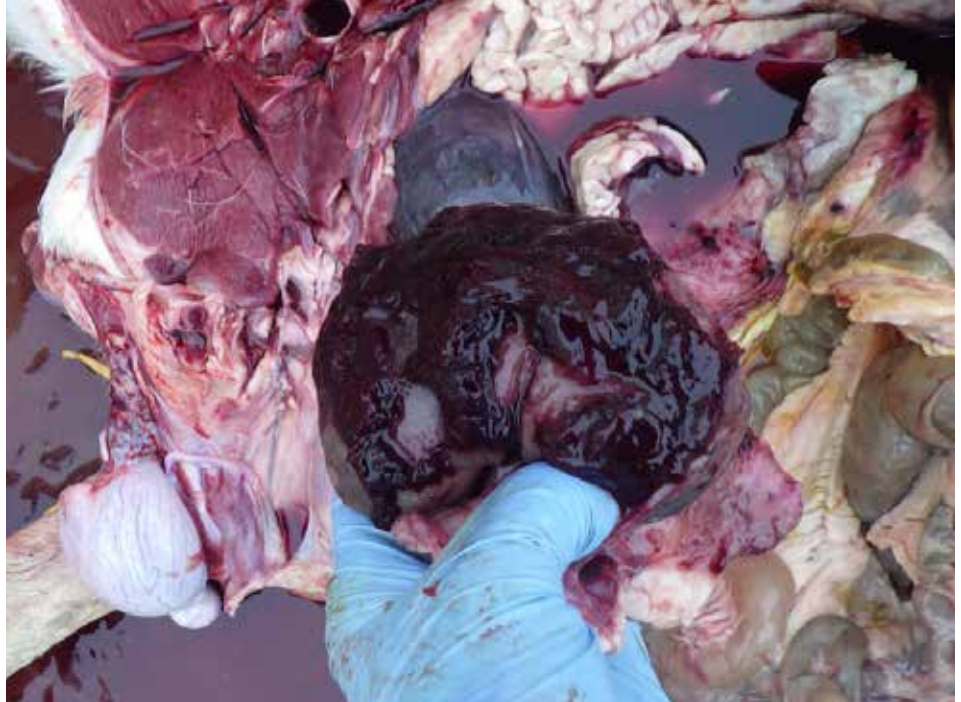Red and severely distended urinary bladder due to stone obstructing penile urethra (Urolithiasis) in a lamb. (Courtesy Ravi. M, AAF)



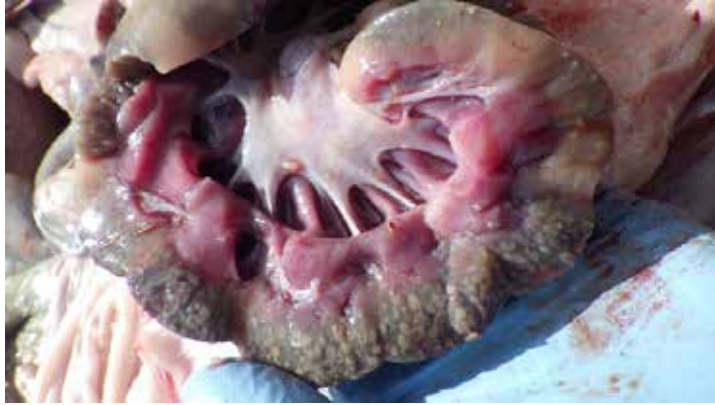## 5.2. Perirenal Hemorrhage

**Figure 5.2.1.**

Ruptured renal artery in a waterbelly. If the bladder or ureter ruptures, urine is released into the abdomen and causes chemical peritonitis.

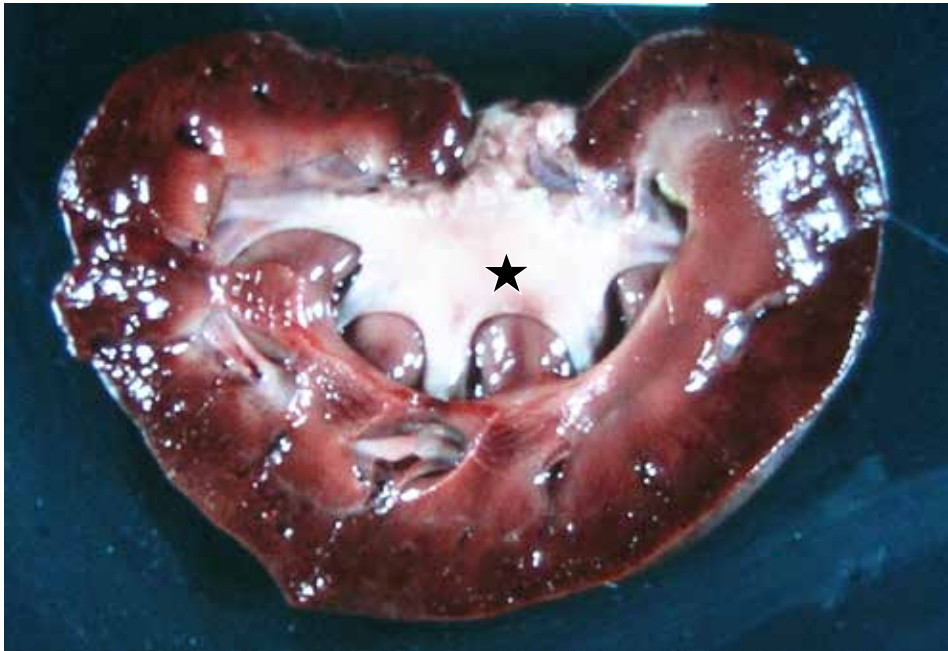

### 5.3. Hydronephrosis



**Figure 5.3.1.**

Hydronephrosis in a lamb due to obstruction of ureter showing renal cortex necrosis and distention of renal calyces and pelvis as a result of obstruction to urine outflow.



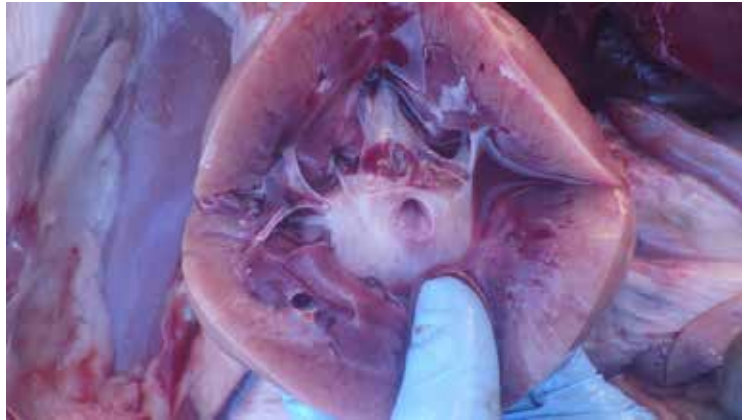**Figure 5.3.2.**

Hydronephrosis in a lamb showing dilated renal pelvis (star).

## 5.4. Bacterial Septicemia (Embolic nephritis)

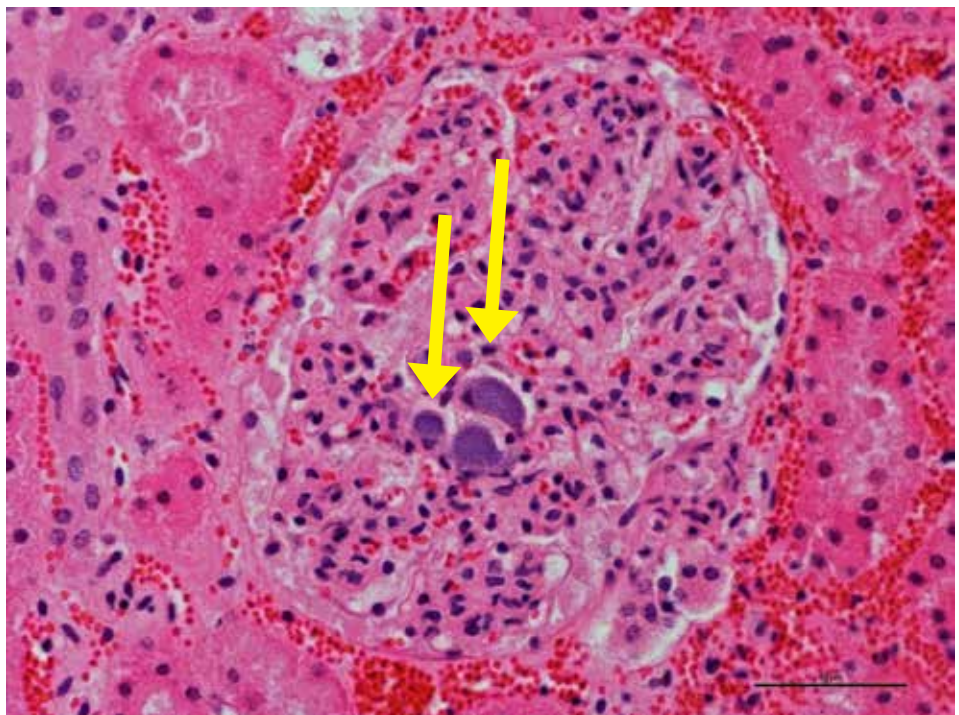
**Figure 5.4.1.**

Renal cortex can appear pale, or have one or more infarcts. Pelvic dilation is common. This lamb died due to bacterial septicemia.

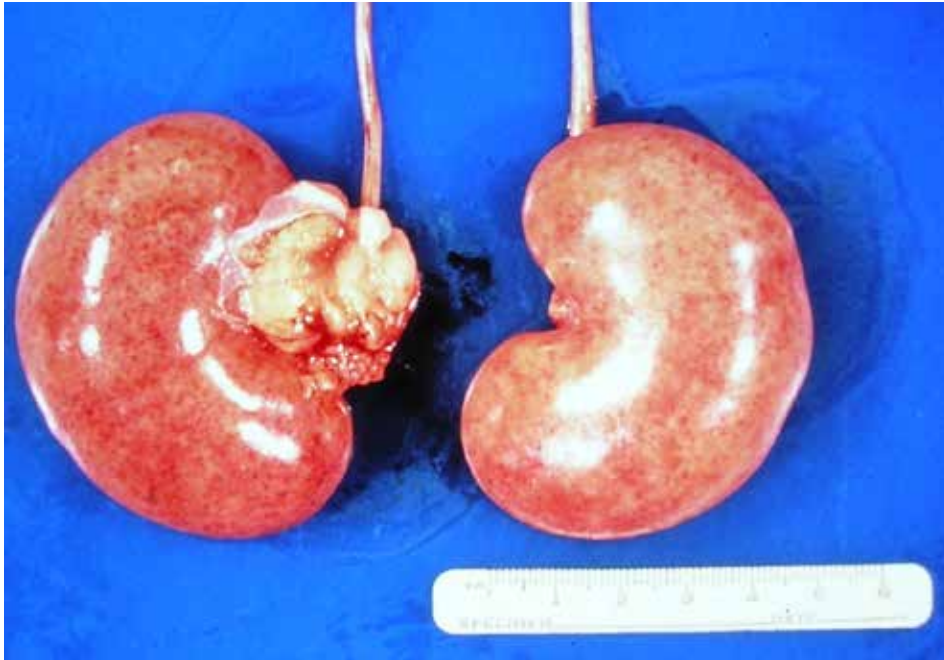

**Figure 5.4.2**

Glomeruli of kidney showing embolic showering of bacteria in capillaries (arrows) and periglomerular and interstitial hemorrhages observed in *E. coli* septicemia.







**Figure 5.4.3.**

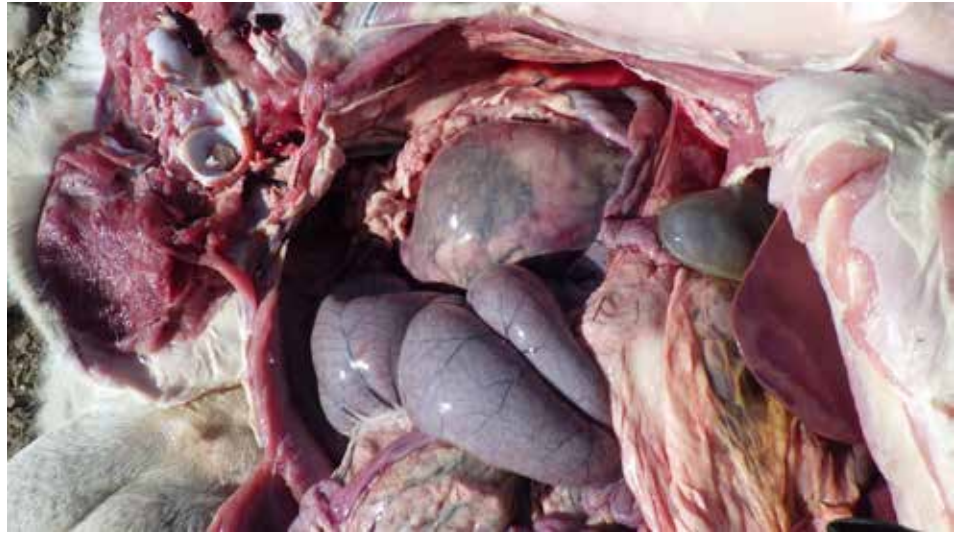Kidneys from a lamb that died due to septicemic Pasteurellosis showing enlarged kidneys with petechial hemorrhages.

## 5.5. Pyelonephritis

Pyelonephritis is inflammation of the kidney, typically due to a bacterial infection.

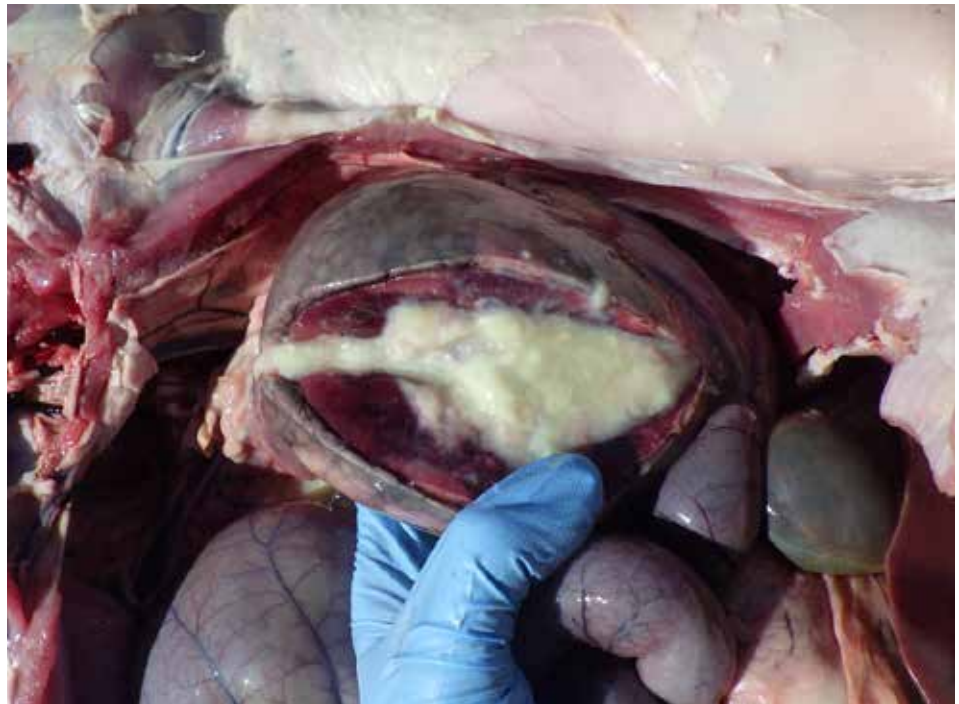
**Figure 5.5.1.**

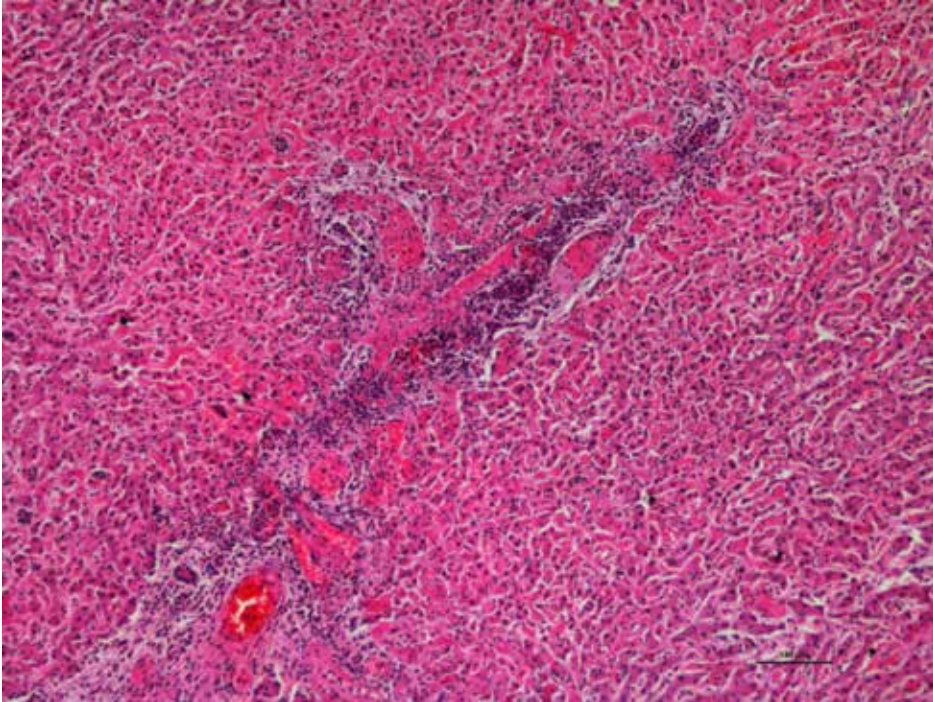
Enlarged kidney due to pyelonephritis in a lamb.



**Figure 5.5.2.**

Pyelonephritis in a lamb – section of kidney showing pus.





**Figure 5.5.3.**

Histology showing liver from same lamb (Fig. 5.5.1) with necrotizing vasculitis. *Histophilus somni* was isolated from the kidney.



## 5.6. Copper Toxicity

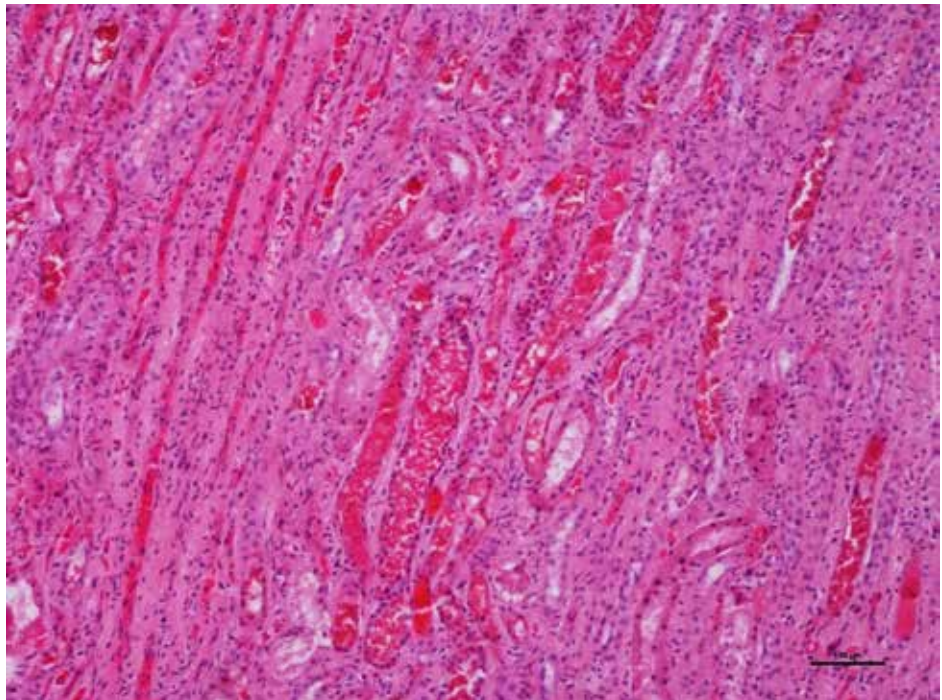
**Figure 5.6.1.**

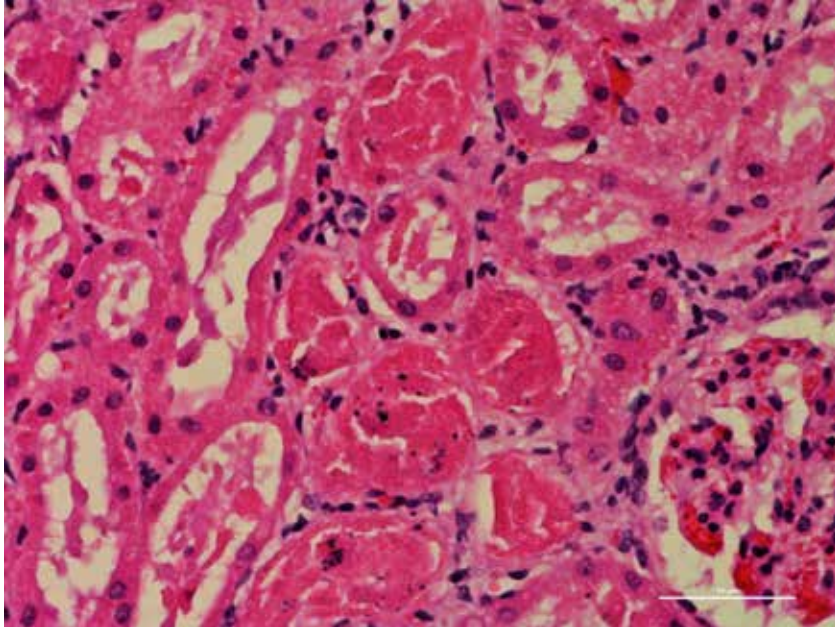
Gun metal colored kidneys  
from a lamb died  
due to copper toxicity.



**Figure 5.6.2.**

Copper toxicity in lamb  
showing kidney with dilated  
renal tubules with pigmentary  
casts (hemoglobin).





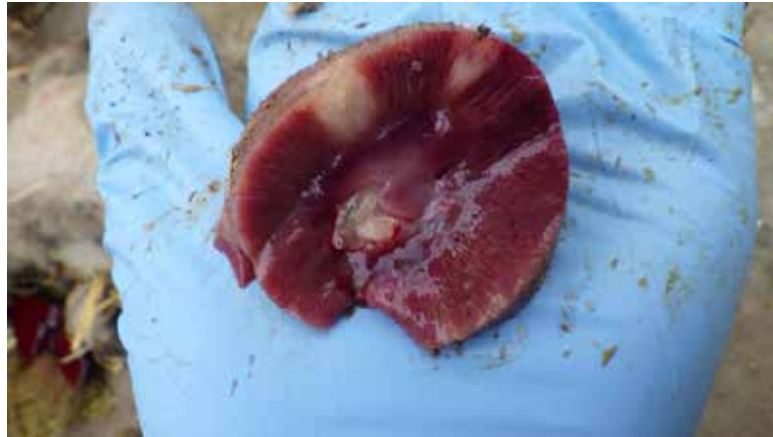
**Figure 5.6.3.**

Kidney: Extensive tubular necrosis with distended tubules filled with red globular (hemoglobin/myoglobin) material.

## 5.7. Renal Infarcts

**Figure 5.7.1.**

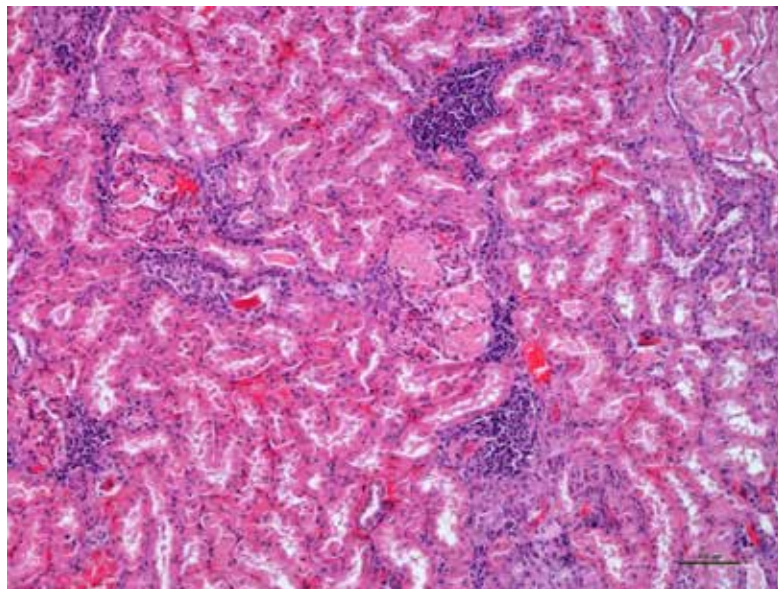
Infarcts in the kidney  
(pale white areas)



## 5.8. Glomerulonephritis

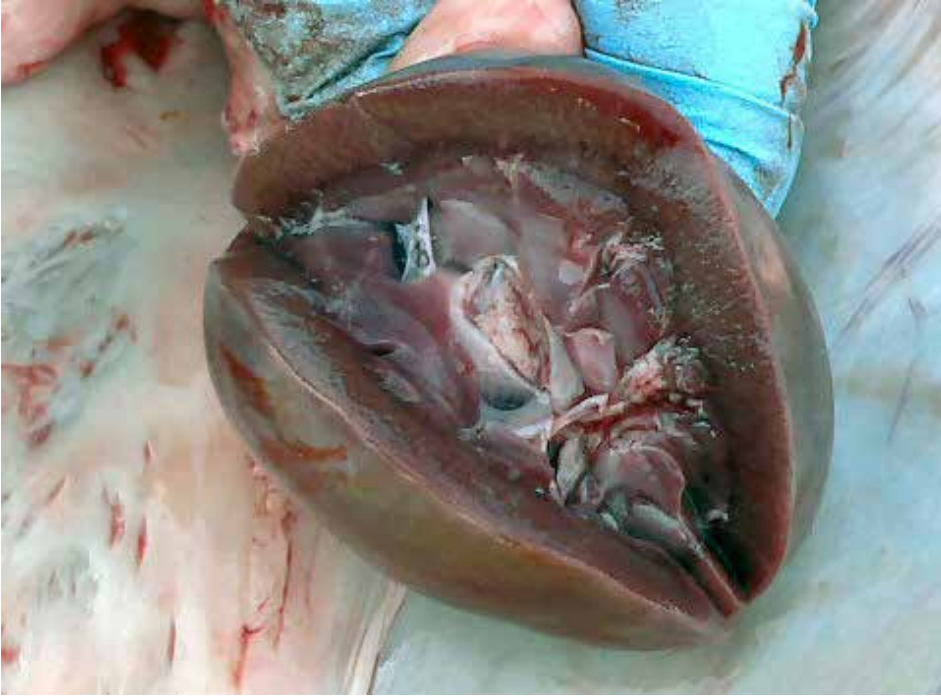
**Figure 5.8.1.**

Kidney showing  
lymphoplasmacytic  
glomerulonephritis due  
to chronic antigenic  
stimulation from  
multisystemic chronic  
abscessation.





## 5.9. Pulpy Kidney



**Figure 5.9.1.**

Pulpy kidney disease is enterotoxemia caused by *Clostridium perfringens* type D. Seen most commonly in rapidly growing lambs. Main clinical signs are sudden death in 4-10 week old lambs born to unvaccinated ewes or in weaned lambs 4 months old when passively derived antibody has waned and the lambs have not been vaccinated. Lambs are very dull, progress quickly to seizures and opisthotonus, followed rapidly by death. There is rapid decomposition of the carcass with excess serosanguinous fluid in the body cavities. The kidneys are very friable.

*Photo courtesy of P. Menzies.*

## VII. NERVOUS SYSTEM

1. Listeriosis .....	196
2. Polioencephalomalacia.....	201

## VII. NERVOUS SYSTEM



**Figure 7.1.0.**

Lamb with nervous disease. Animal is down and unable to rise. Head is flexed back and eyes either move from side to side (nystagmus) or are positioned abnormally (strabismus). Listeriosis and polioencephalomalacia (polio) are the most common causes of neurologic disease in feedlot lambs.



## 7.1. Listeriosis

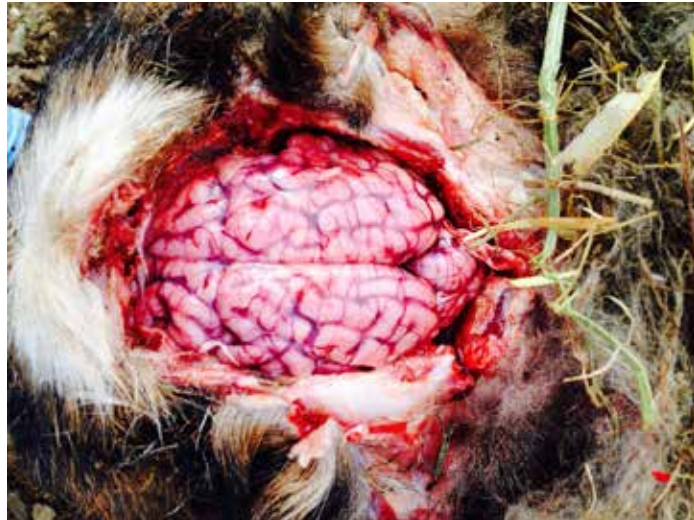**Figure 7.1.1.**

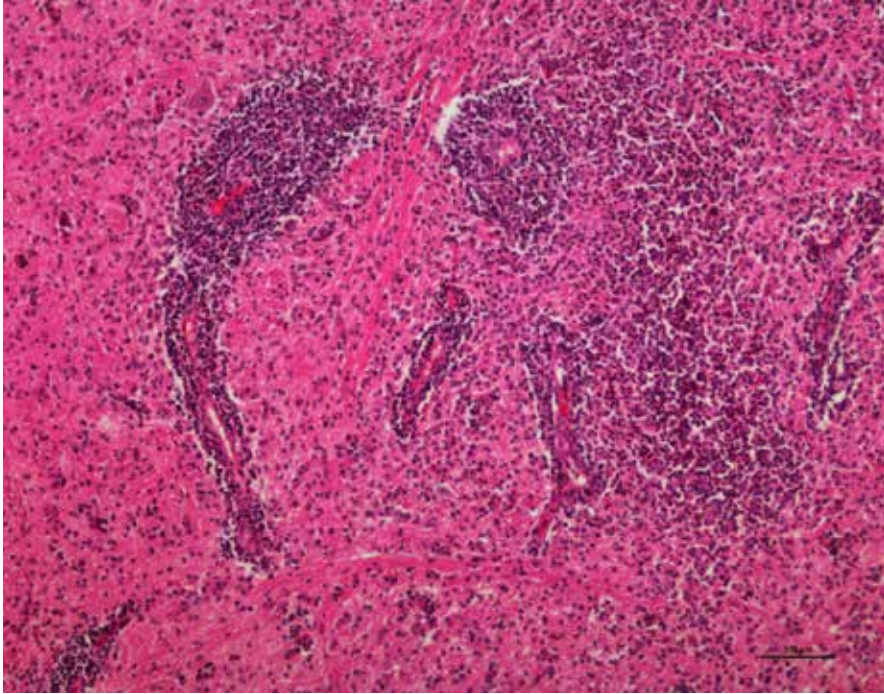
Sheep with listeriosis.  
*Photo courtesy of P. Menzies.*



**Figure 7.1.2.**

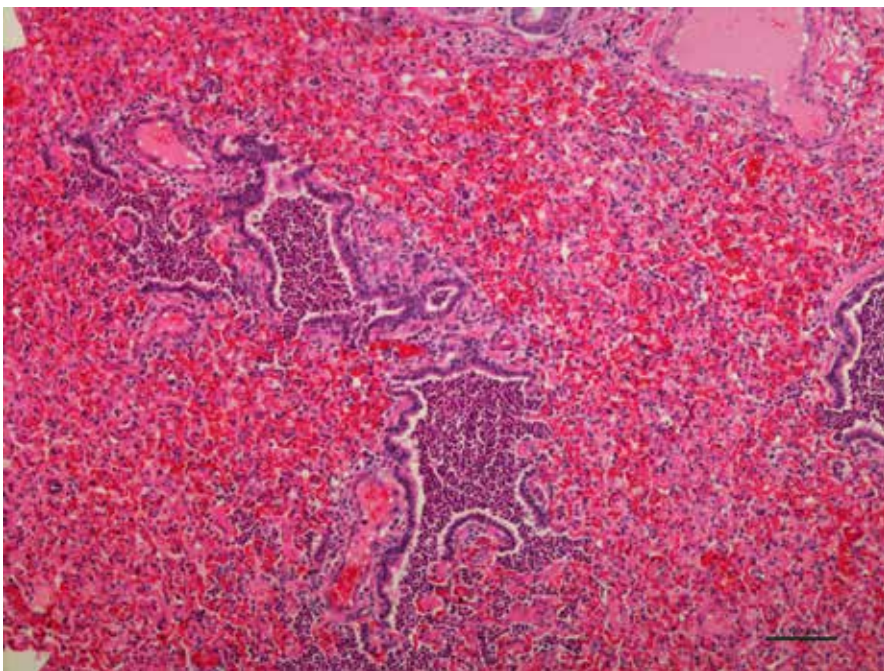
Meningitis with opacity of  
meninges of brain.





**Figure 7.1.3.**

Necro-suppurative meningoencephalitis with lymphocytic vasculitis. *Listeria monocytogenes* was isolated from brain of this lamb.



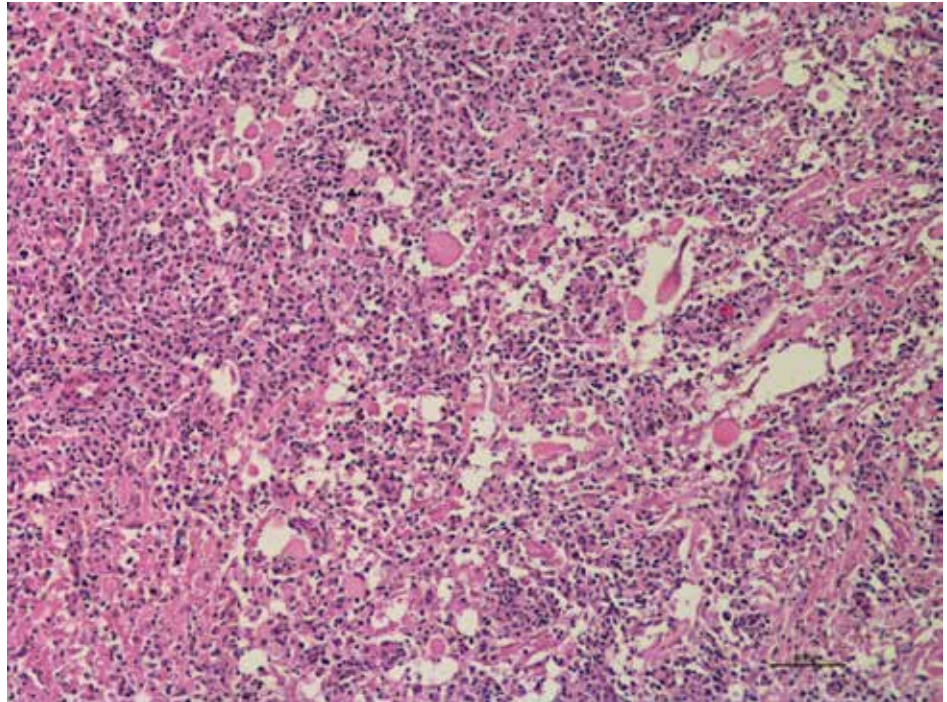
**Figure 7.1.4.**

Lung showing hemorrhagic bronchopneumonia from the same lamb affected with listeriosis.



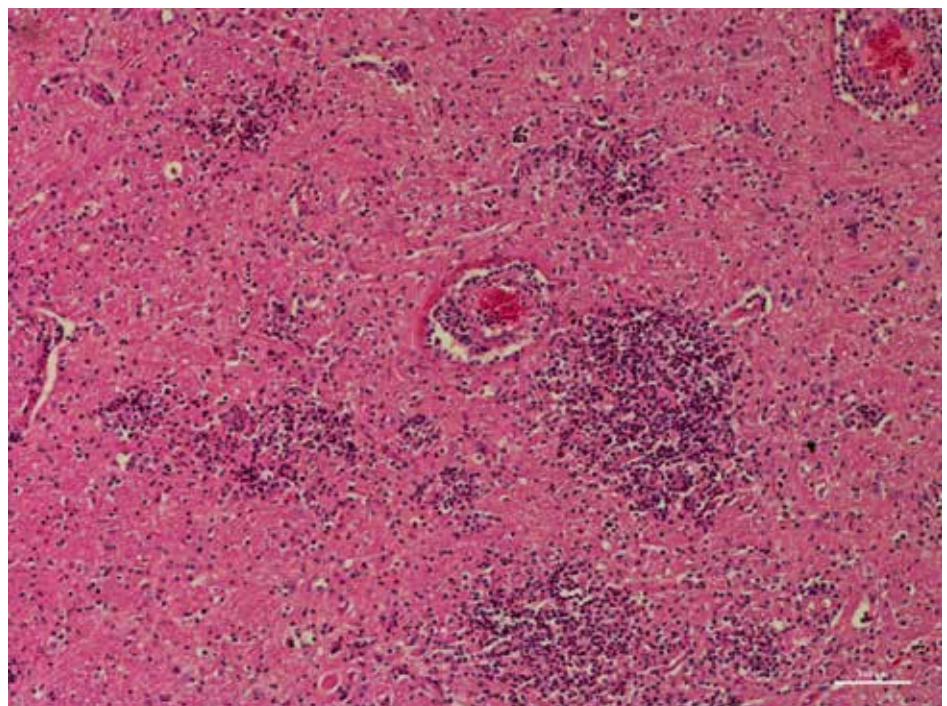
**Figure 7.1.5.**

Necrotizing meningoencephalitis  
in a lamb affected  
with listeriosis.

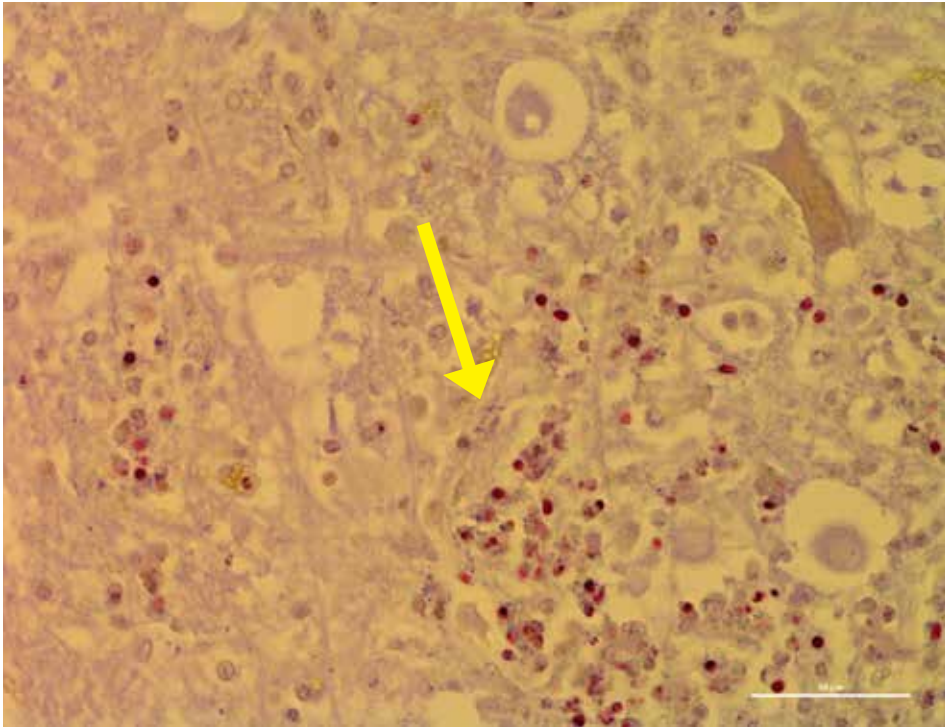


**Figure 7.1.6.**

Necrotizing meningoencephalitis  
with vasculitis, micro-abscesses,  
glial nodules and gram positive  
bacterial rods noted in the brain.







**Figure 7.1.7.**

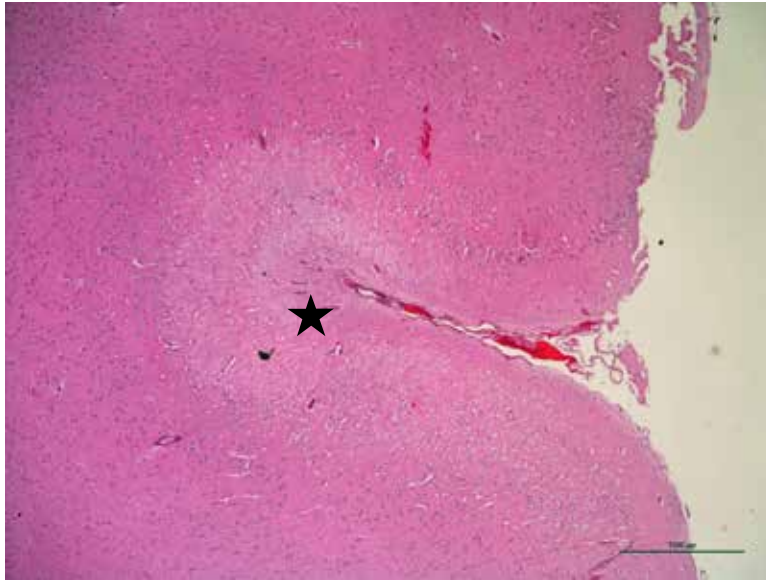
Gram positive bacteria (arrow) seen in the brain lesions of lamb that died due to listeriosis.

## 7.2. Polioencephalomalacia

**Figure 7.2.1.**

Sheep with polioencephalomalacia. Sheep unable to rise.  
*Photo courtesy of P. Menzies.*





**Figure 7.2.2.**

Laminar cortical necrosis in the brain of a lamb that died due to polioencephalomalacia. Histopathological examination will help to differentiate the condition from other causes of neurologic disease.



## VIII. INTEGUMENTARY AND MUSCULOSKELETAL SYSTEMS

### A. Integumentary System

1. Aural Hematoma .....	204
2. Dermatitis.....	204
3. Cellulitis.....	205
4. Contagious Ecthyma/Orf .....	205
5. Ringworm .....	207
6. Lice .....	207
7. Sheep Ked .....	208
8. Mange .....	209

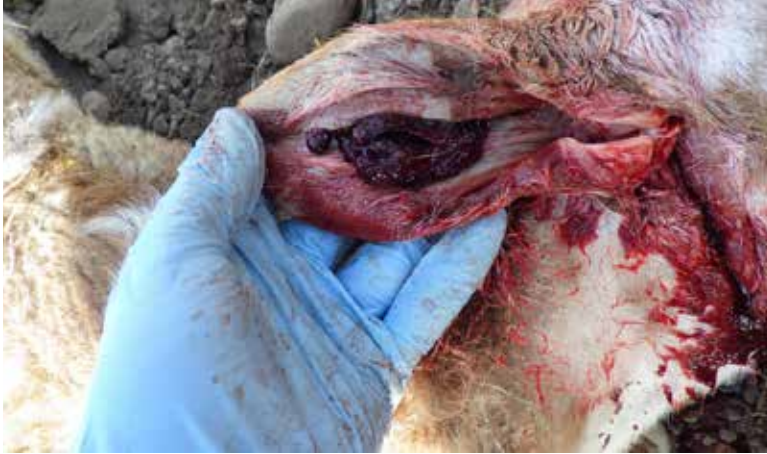### B. Musculoskeletal System

1. Arthritis .....	211
2. Claw abnormalities .....	213
3. Footrot.....	214
4. CODD (Hairy Heel Warts).....	217
5. Injuries .....	220
6. White Muscle Disease/Nutritional Myopathy	222
7. Ionophore Toxicity .....	224
8. Laminitis (Founder) .....	225

## VIII. INTEGUMENTARY SYSTEM AND MUSCLOSKELETAL SYSTEM

### 8A. INTEGUMENTARY SYSTEM

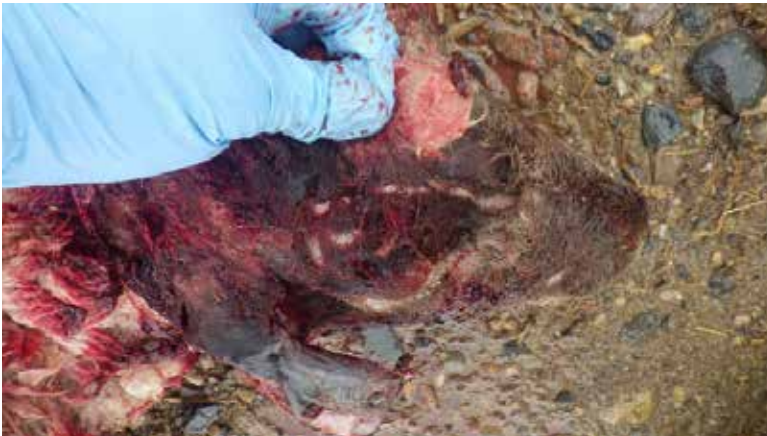#### 8a.1. Aural Hematoma



**Figure 8a.1.1.**

Aural hematoma in an animal with nervous disease.

#### 8a.2. Dermatitis



**Figure 8a.2.1.**

Infection of the skin.

### 8a.3. Cellulitis

**Figure 8a.3.1.**

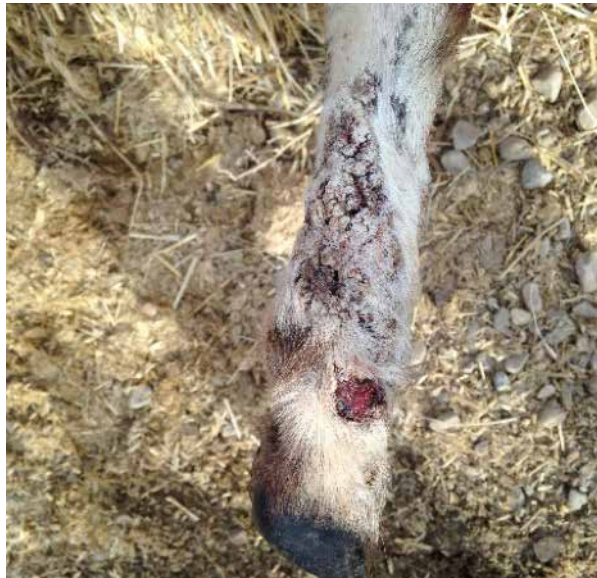Cellulitis around the nose.  
Severe bacterial infection  
under the skin.



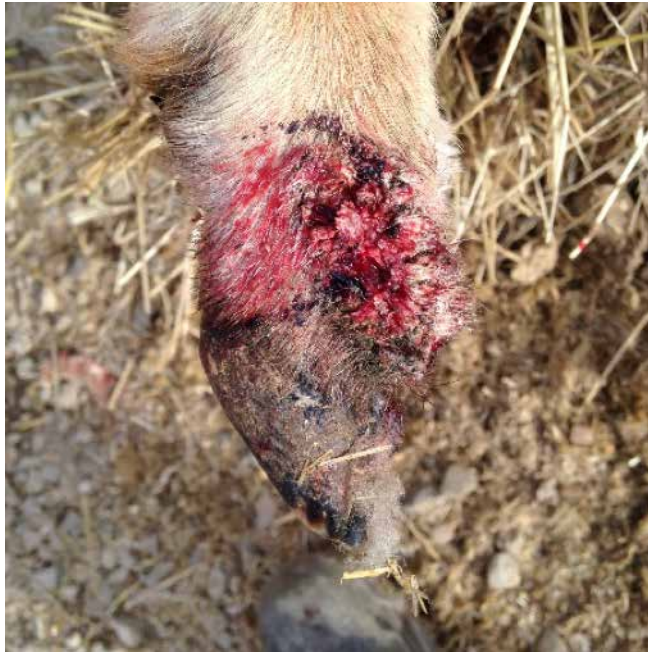### 8a.4. Contagious Ecthyma or “Orf”

**Figure 8a.4.1.**

Contagious ecthyma (orf)  
lesions on a leg. Virus  
that causes orf in sheep also  
causes disease in humans and  
so necessary protective clothing  
and hygienic measures should  
be followed.

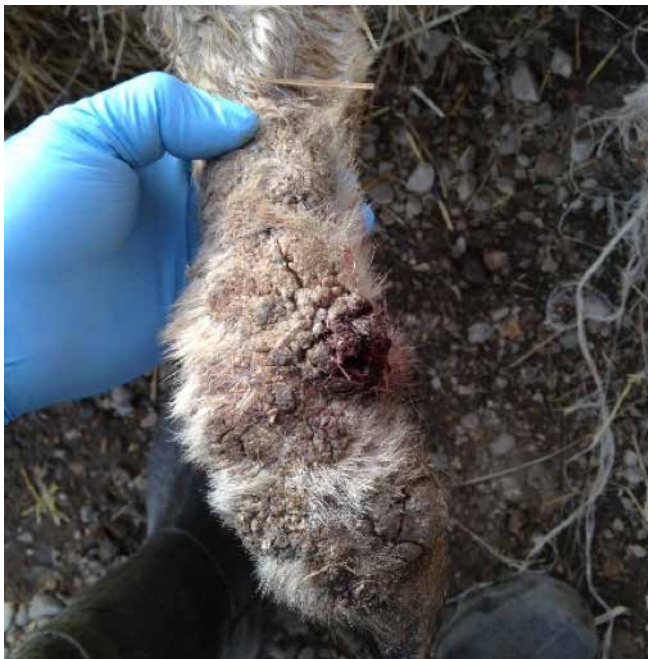





**Figure 8a.4.2.**

Contagious ecthyma or “orf” lesions are most common on the mouth but can also be seen on the lower limbs.



**Figure 8a.4.3**

Orf on a limb.

## 8a.5. Ringworm

**Figure 8a.5.1.**

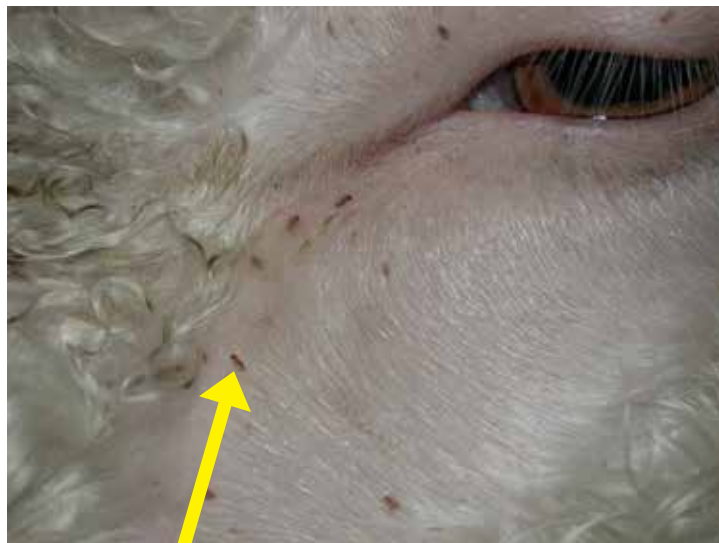Ringworm in a goat due to infection caused by the fungus *Trichophyton* species. The lesions are characterised by clearly demarcated areas of hair loss, sometimes covered by crusts. The lesions are common face, ears and neck. Ringworm can cause skin disease in human, so care should be taken when handling affected animals.  
*Photo courtesy of P. Menzies.*



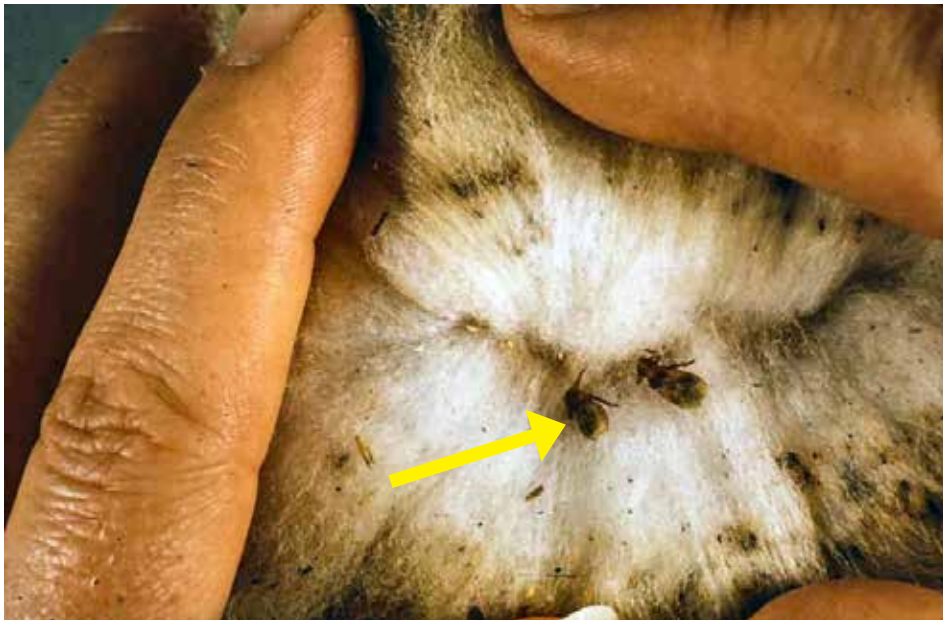## 8a.6. Lice

**Figure 8a.6.1.**

Biting lice on face of lambs (arrow).  
*Photo courtesy of P. Menzies.*



## 8a.7. Sheep Keds



**Figure 8a.7.1.**

Sheep keds (arrow) suck blood and can cause anemia.

*Photo courtesy of Andrew Peregrine, University of Guelph.*



**Figure 8a.7.2.**

Sheep ked.

*Photo courtesy of Andrew Peregrine, University of Guelph.*

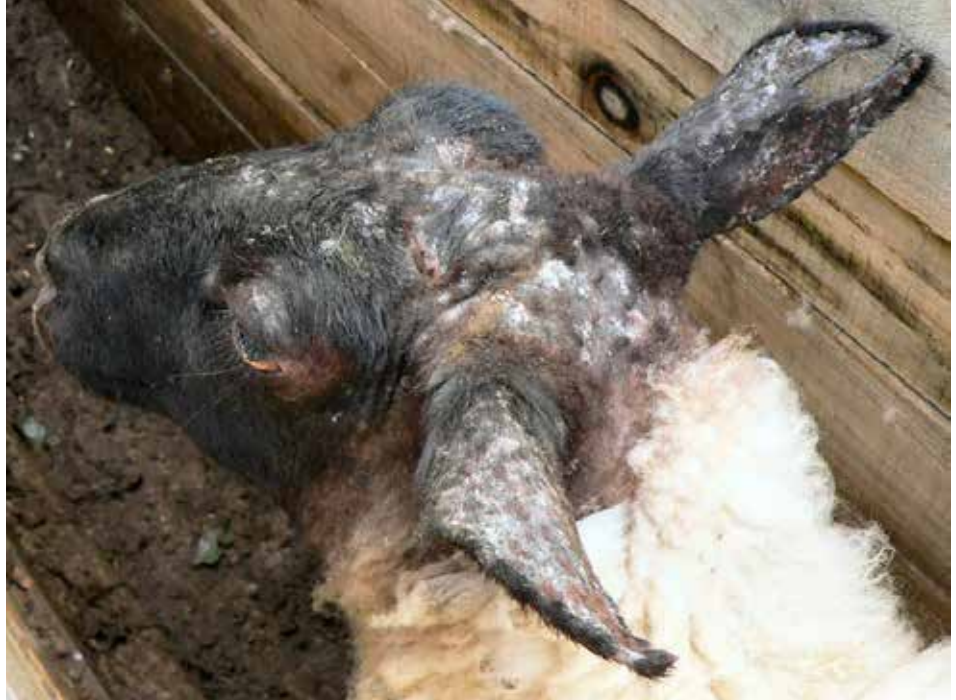

## 8a.8. Mange

**Figure 8a.8.1.**

Sarcoptes mange. Notice dry scabby lesions on head and ears.

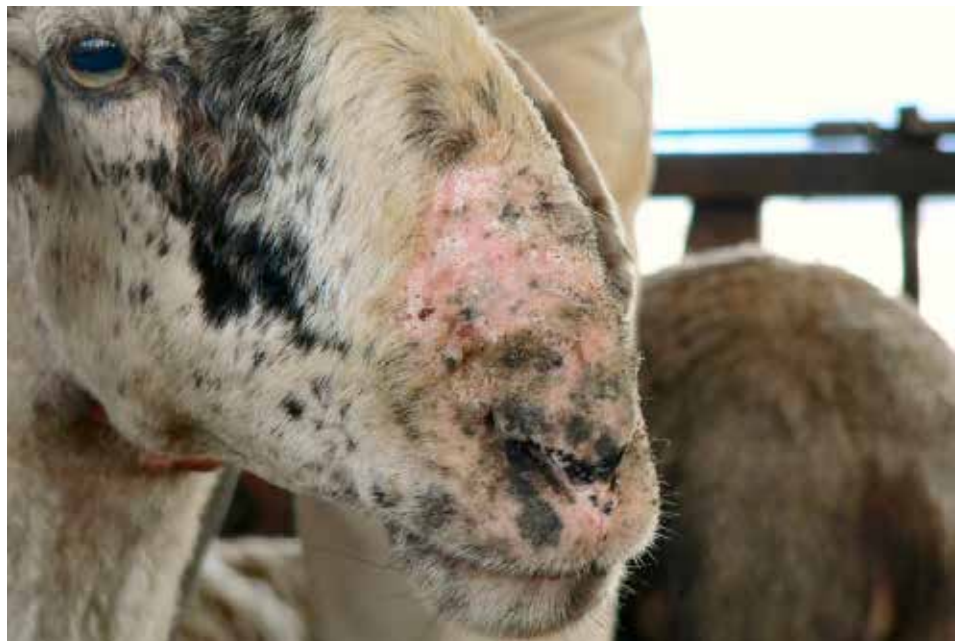*Photo courtesy of P. Menzies.*

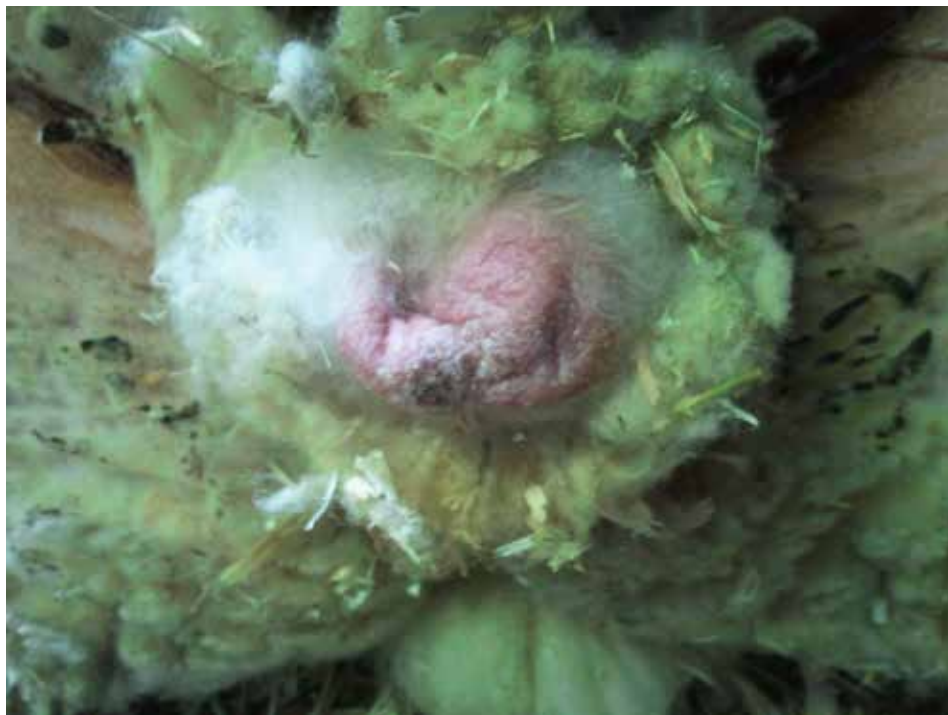

**Figure 8a.8.2.**

Sarcoptes mange on nose.

*Photo courtesy of P. Menzies.*





**Figure 8a.8.3.**

Mange on the scrotum.

*Photo courtesy of P. Menzies.*

## 8B. Musculoskeletal System

### 8b.1. Arthritis

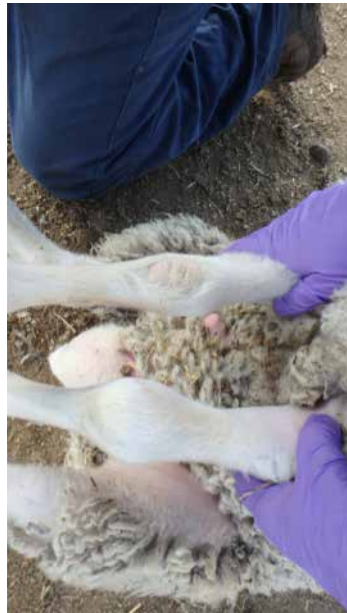**Figure 8b.1.1.**

Lame lamb with swollen front knee. Swelling of a joint is typically referred to as arthritis. Common causes of arthritis include *Histophilus sp.*, *Chlamydophilia sp.*, *Erysipelothrix sp.*, *Mycoplasma sp.*, and penetrating wounds.



**Figure 8b.1.2.**

Arthritis in knees. Notice swollen joints with hair rubbed off the knees, indicating the animal has been laying down frequently. Photos courtesy of Lethbridge Research Station.

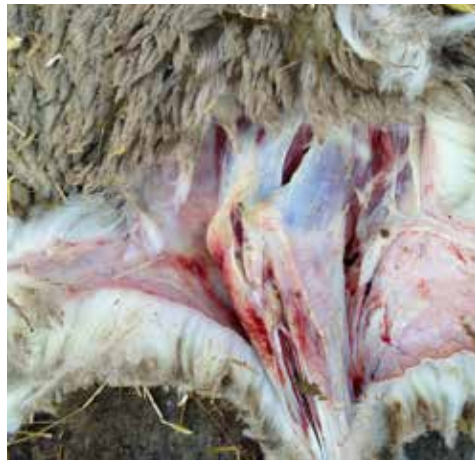





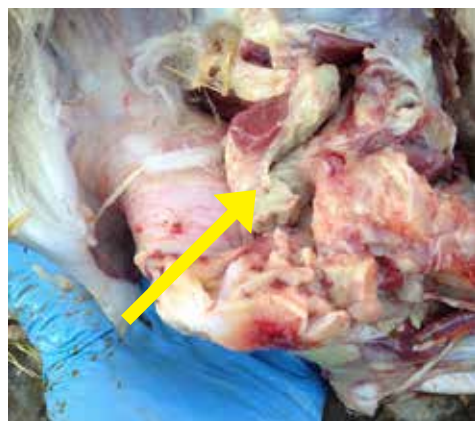**Figure 8b.1.3.**

Lameness is a common problem in sheep feedlots and can occur on front or hind limbs.



**Figure 8b.1.4.**

Arthritis. Notice swollen joint and some necrotic material around joint and extending into the joint.



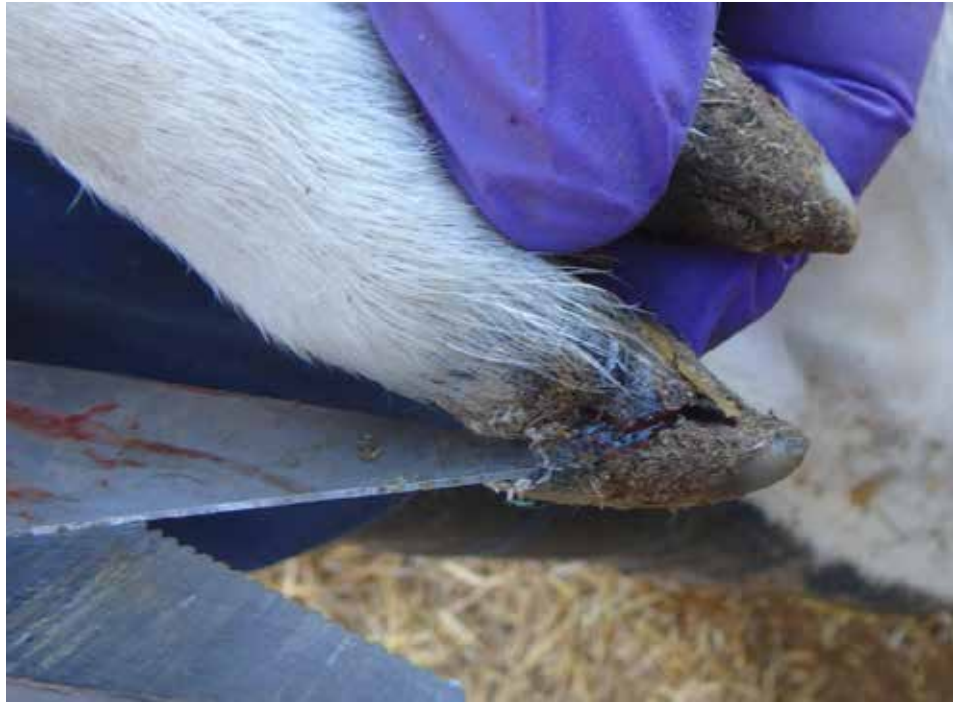**Figure 8b.1.5.**

Severe elbow chronic arthritis with thick purulent debris (fibrin) within and surrounding the joint.

## 8b.2. Claw Abnormalities

**Figure 8b.2.1.**

Cracked hoof.  
*Photo courtesy of  
Lethbridge Research Station.*



**Figure 8b.2.2.**

Overgrown claw  
that needs trimming.

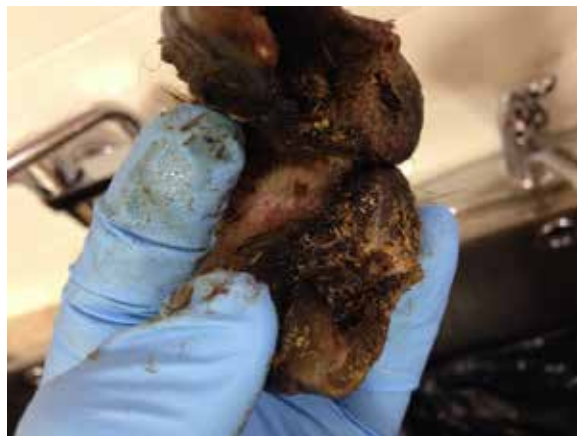

### 8b.3. Foot Rot



**Figure 8b.3.1.**

Footrot. Notice lesions between the claws.



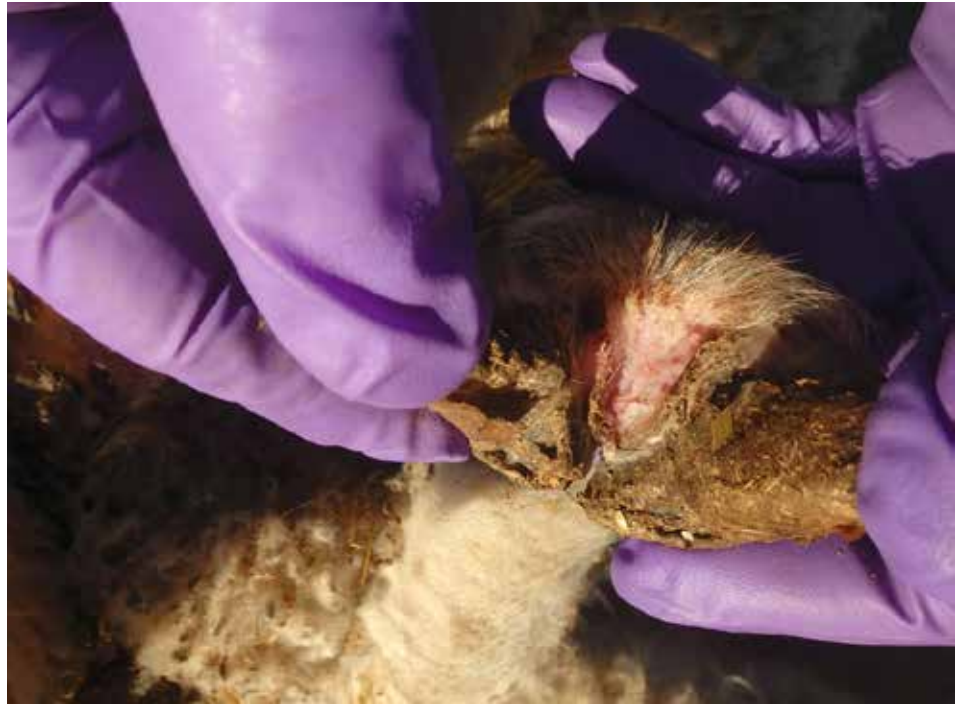**Figure 8b.3.2.**

Footrot. Notice lesions between the claws.



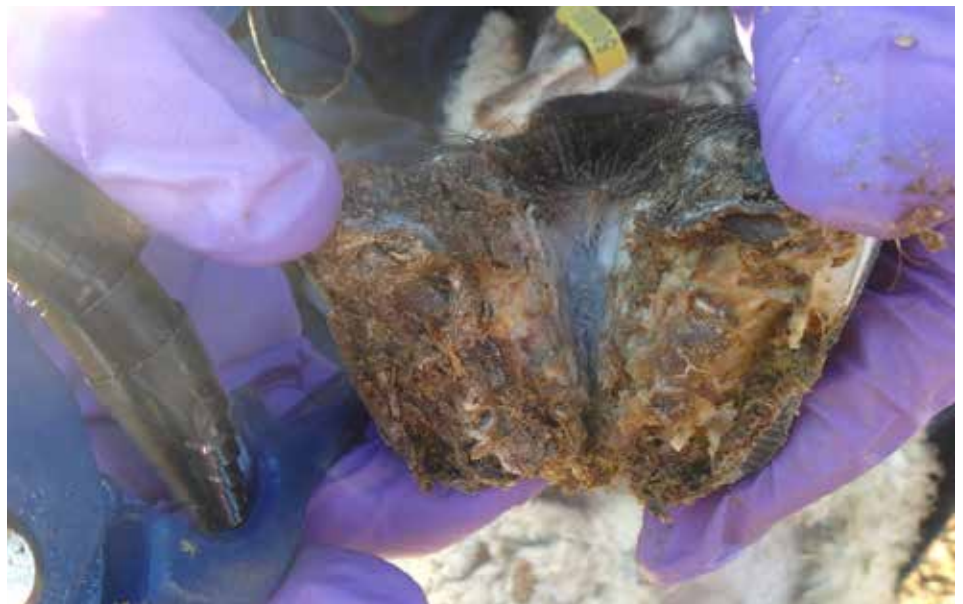**Figure 8b.3.3.**

Footrot. Note lesion between the claws.  
*Photo courtesy of Lethbridge Research Station.*



**Figure 8b.3.4.**

Severe footrot. Notice soft undermined soles with necrotic (dead) tissue.  
*Photo courtesy of Lethbridge Research Station.*





**Figure 8b.3.5.**

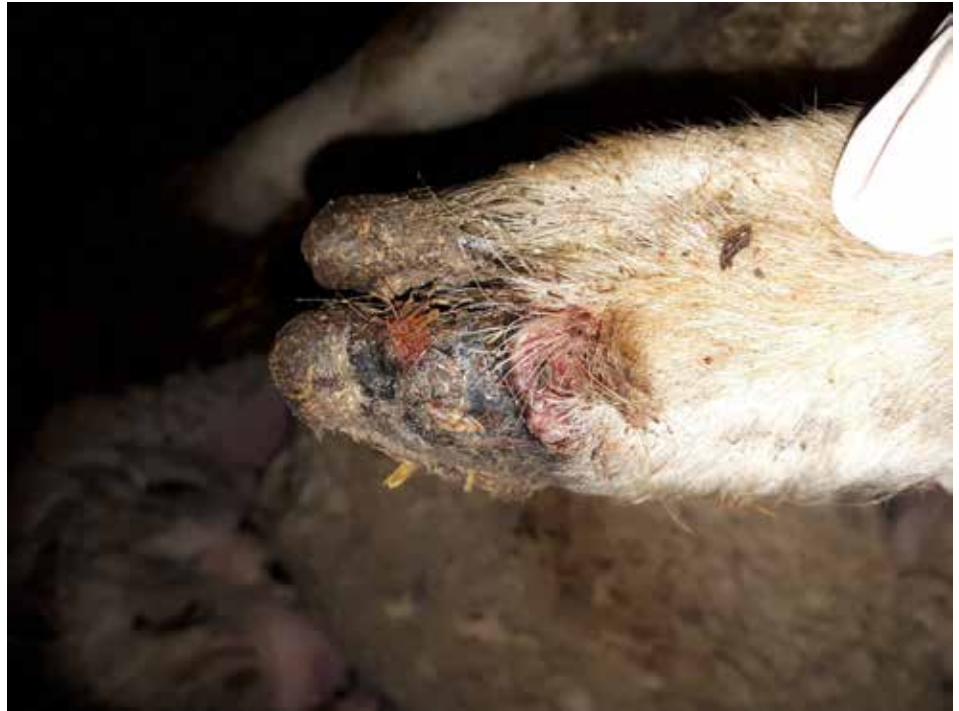Footrot in sheep. *Dichelobacter nodosus* and *Fusobacterium necrophorum* are the primary pathogens, though a variety of bacteria have been isolated, including *Treponema* which causes hairy heel warts.

### 8b.4. Contagious Ovine Digital Dermatitis (Hairy Heel Warts)

**Figure 8b.4.1.**

This disease is caused by a bacterium called *Treponema*. It is more commonly observed in dairy cattle and in feedlot cattle. The disease is very infectious causing sore raw areas to develop on the skin around the heels. Affected sheep will be reluctant to walk and have lameness. Raw red shiny lesions which are erosive/ulcerative develop and there can be proliferative lesions as well.

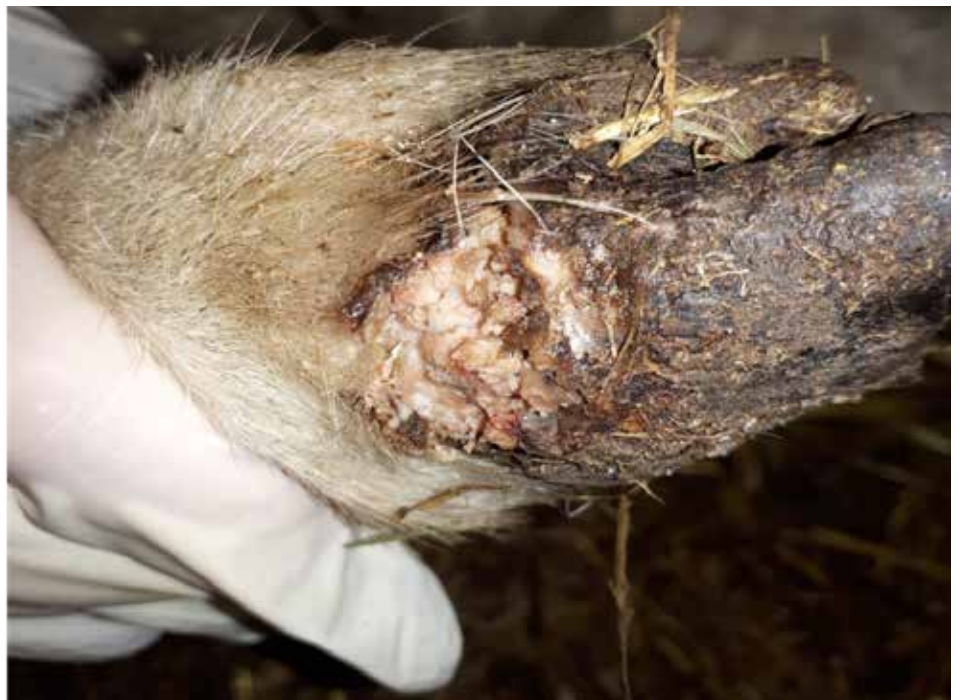*Photo courtesy of Fiona Lovatt.*



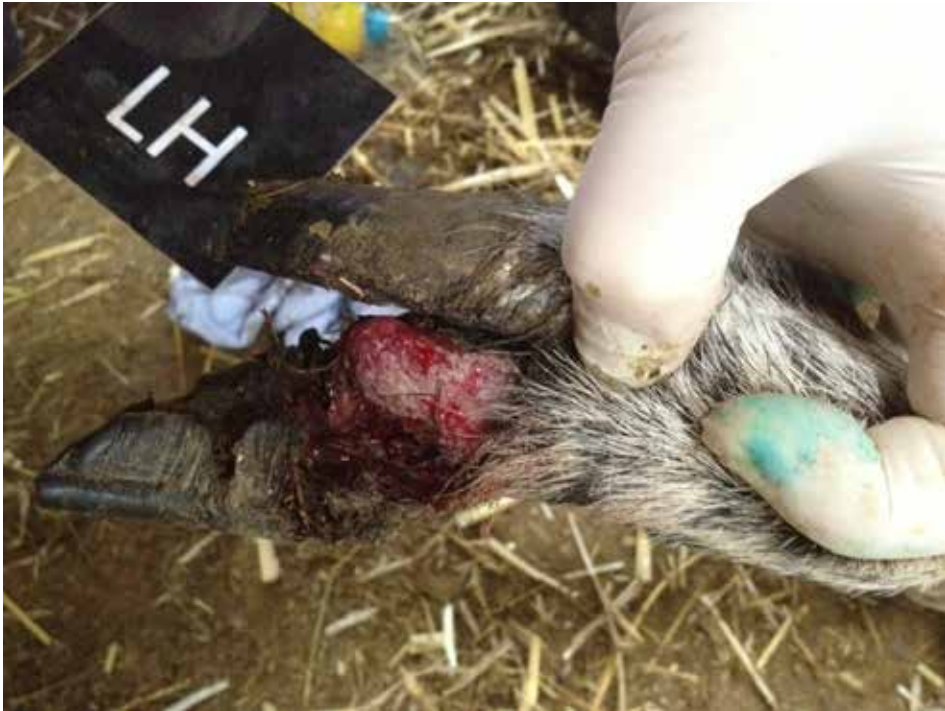**Figure 8b.4.2.**

The lesions of CODD can be very severe and result in bleeding. *Treponema* has been identified by PCR in lambs with foot lesions from Alberta.

*Photo courtesy of Fiona Lovatt.*

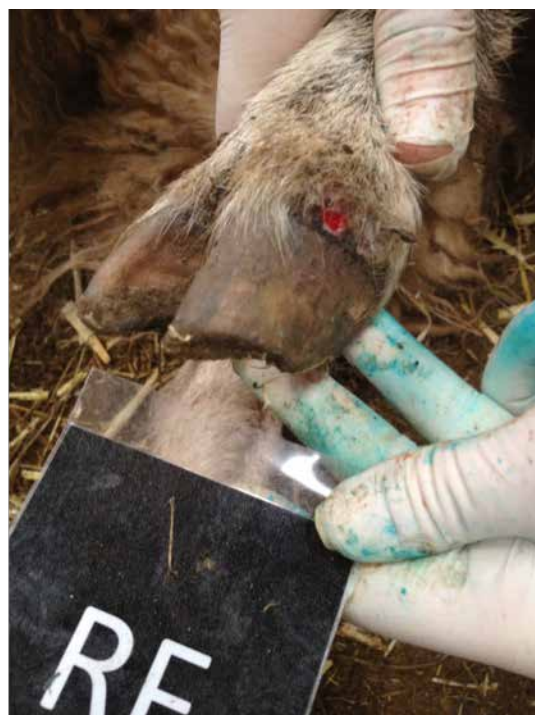





**Figure 8b.4.3.**

Severe foot lesions with loss of the claw in a lamb with CODD.  
*Photo courtesy of Fiona Lovatt.*



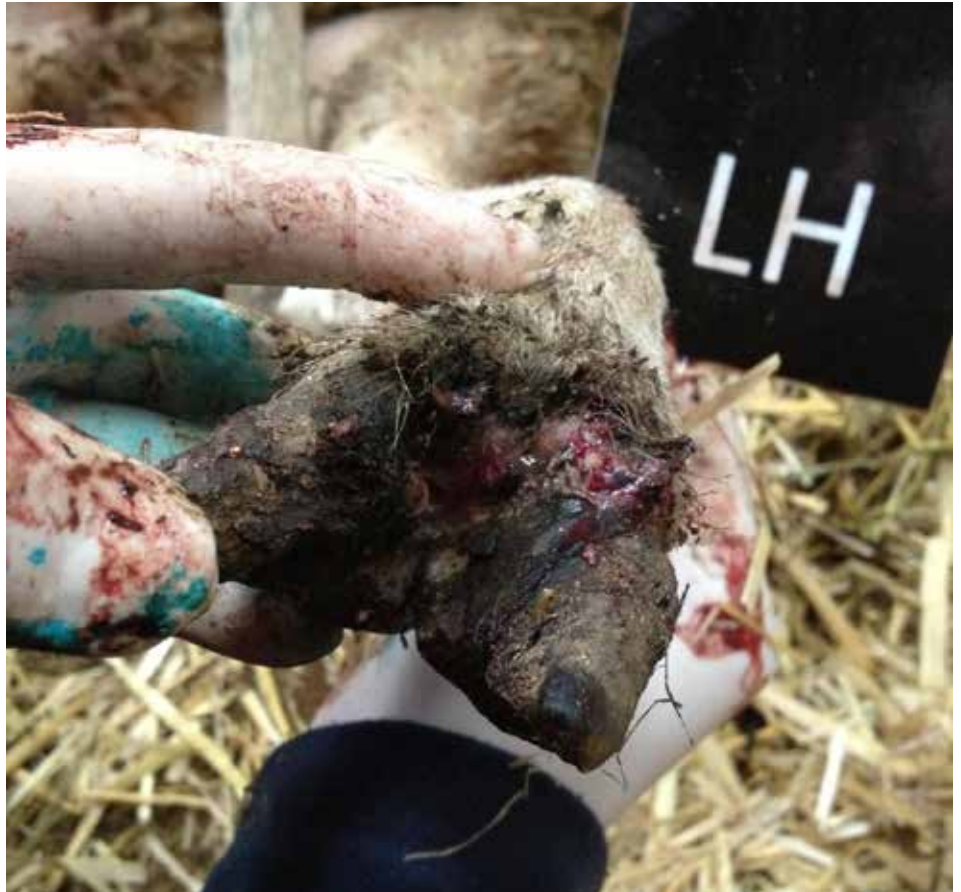**Figure 8b.4.4.**

Early CODD lesion.  
*Photo courtesy of Fiona Lovatt.*

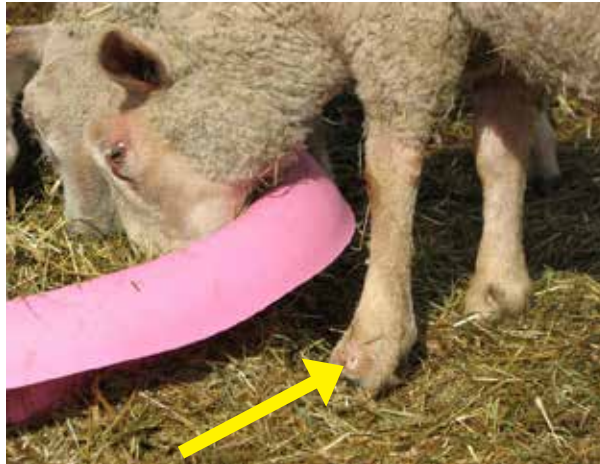
**Figure 8b.4.5.**

Older CODD lesion.

*Photo courtesy of Fiona Lovatt.*



## 8b.5. Injuries



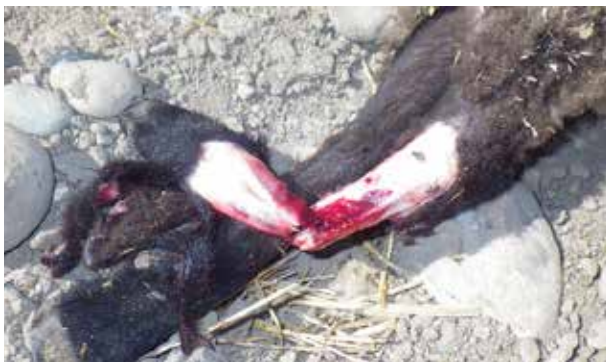**Figure 8b.5.1.**

Puncture wound on side of left foot.



**Figure 8b.5.2.**

Broken leg. Notice angular limb deformity.



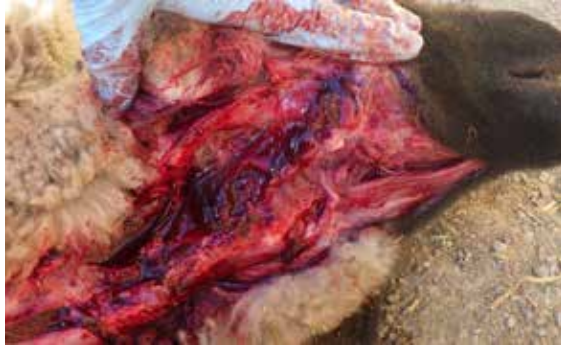**Figure 8b.5.3.**

Fractured limbs are not commonly repaired and animals are humanely euthanized.



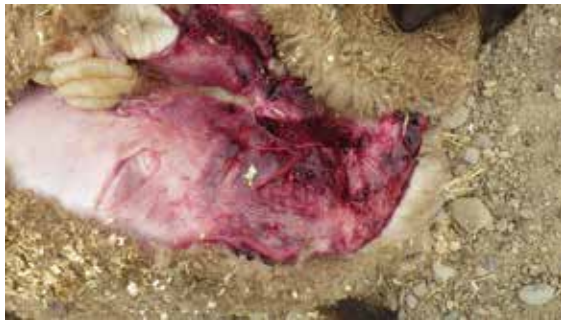**Figure 8b.5.4.**

Bruising and edema in the neck  
– history of “died by the bunk”.  
Probably choked itself  
in the feed bunk.



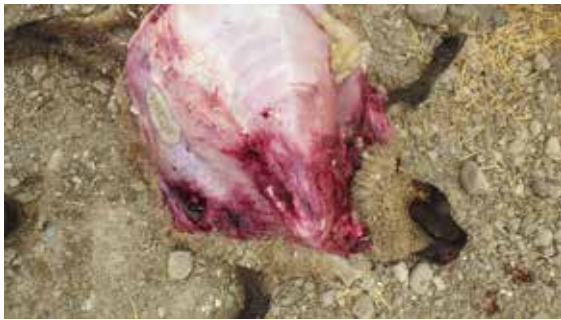**Figure 8b.5.5.**

Severe bruising in neck area  
from trauma.



**Figure 8b.5.6.**

Bruising and edema around  
the neck and chest - lamb died  
from an injury.

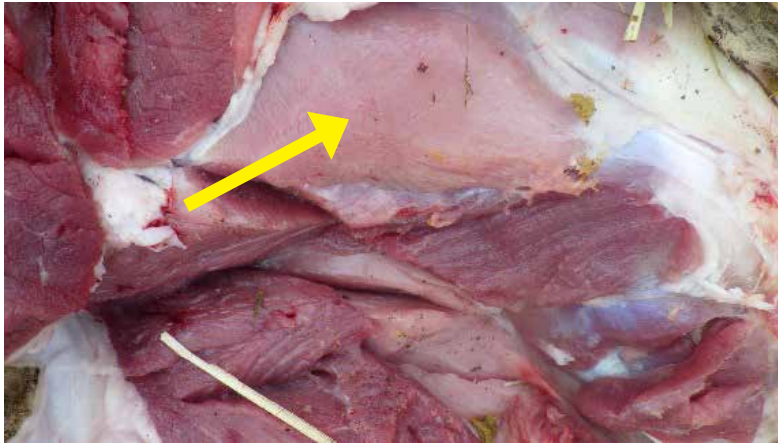


**Figure 8b.5.7.**

Feed bunk crowding is a  
significant issue in sheep  
feedlots – it is important  
to have enough bunk space  
for every lamb to eat  
at the same time.

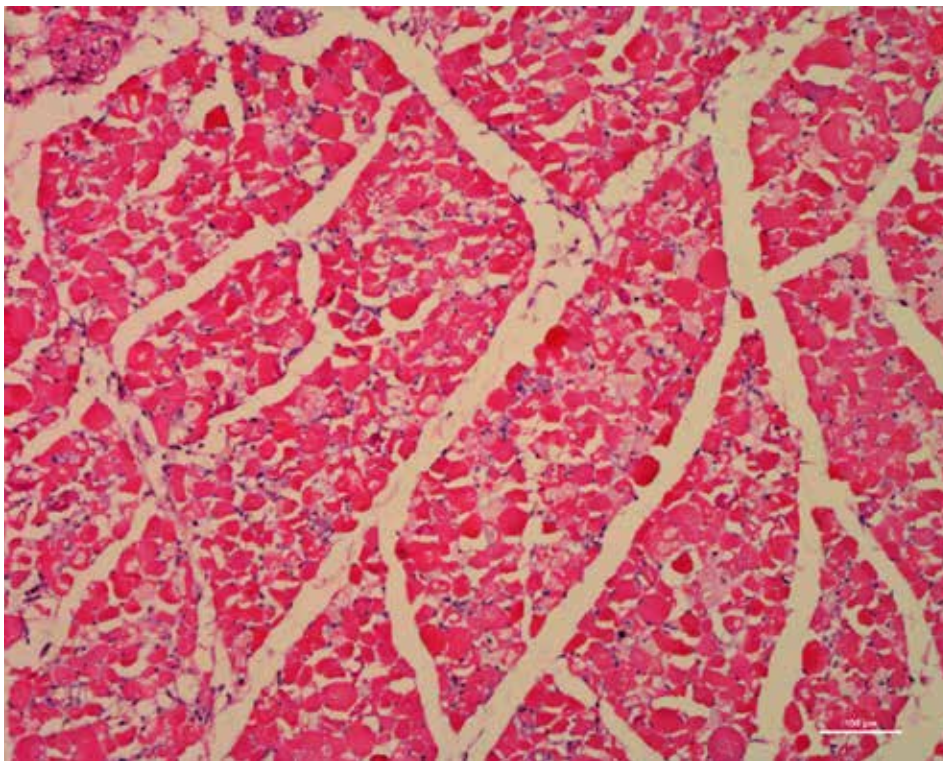


## 8b.6. White Muscle Disease/Nutritional Myopathies



**Figure 8b.6.1.**

Newly arrived lamb with a history of unable to rise. Pale hind leg muscles. Some muscles affected, and others not. Animal was euthanized.



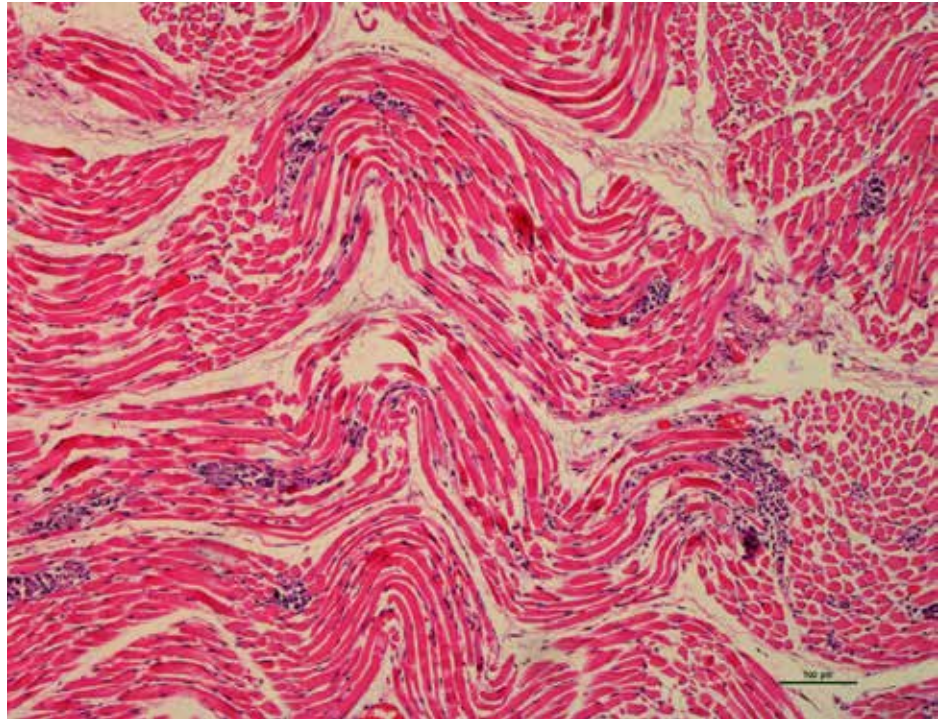
**Figure 8b.6.2.**

Skeletal muscle showing degeneration and necrosis in a lamb with White Muscle Disease caused by vitamin E and/or Selenium deficiency.



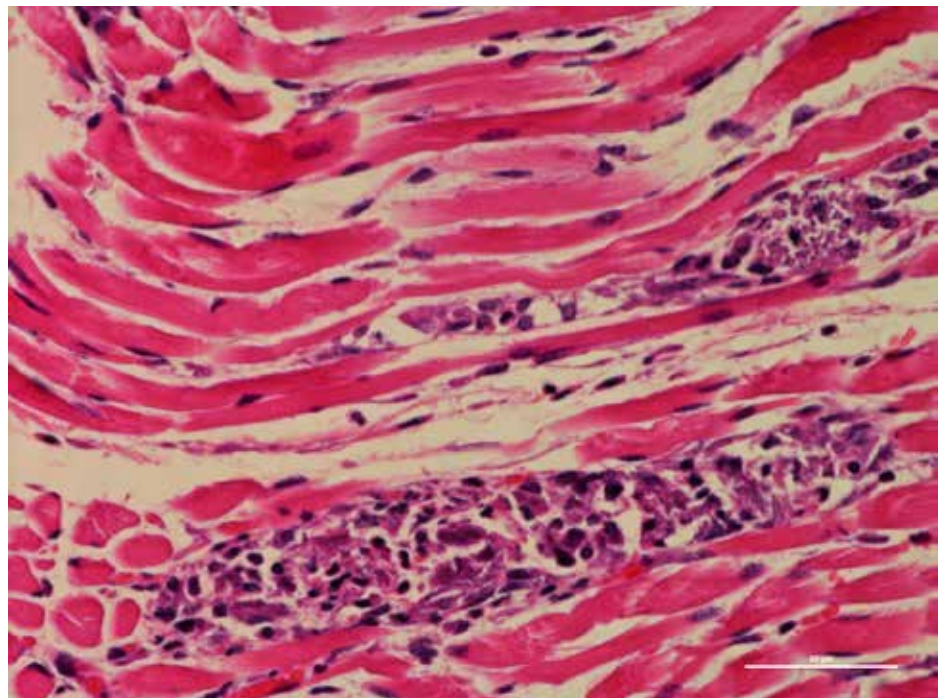
**Figure 8b.6.3.**

Diaphragm showing wavy myofibers with degeneration, necrosis and mineralization.



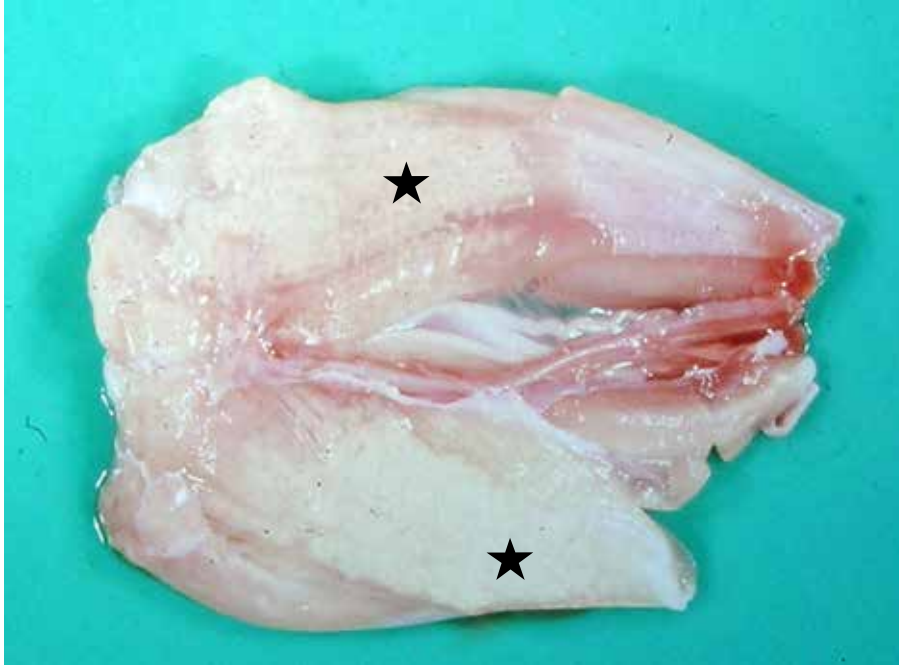**Figure 8b.6.4.**

Diaphragm showing myofiber degeneration and necrosis with mineralization. Liver analysis revealed deficiency of vitamin E. Often these lambs have normal selenium levels. Selenium deficiency can also concurrently occur in these lambs.



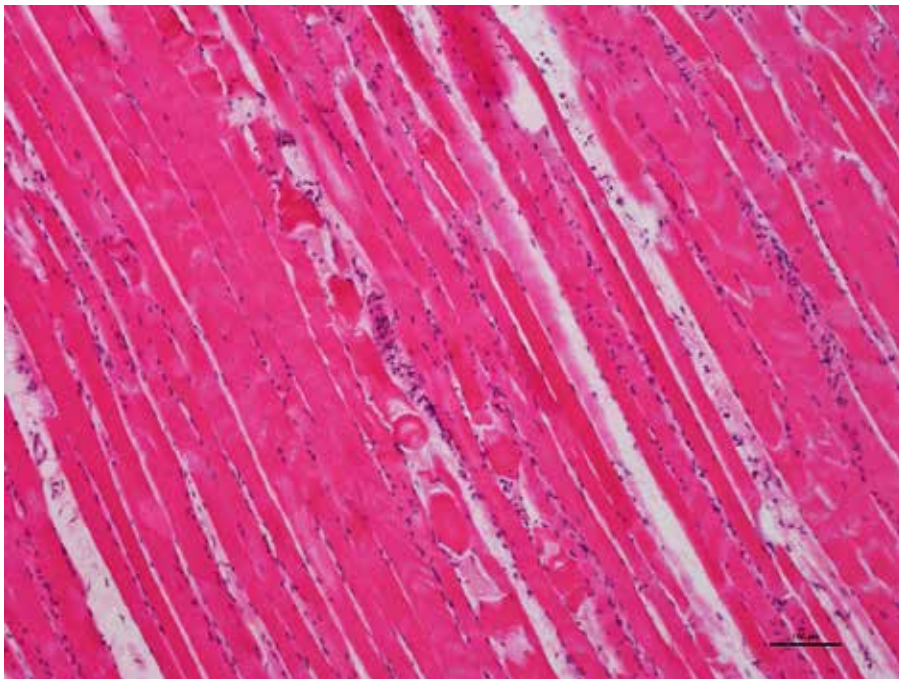


## 8b.7. Ionophore Toxicity



**Figure 8b.7.1.**

Thigh muscle showing extensive areas of necrosis (stars) in a lamb that died due to ionophore (monensin) toxicity.



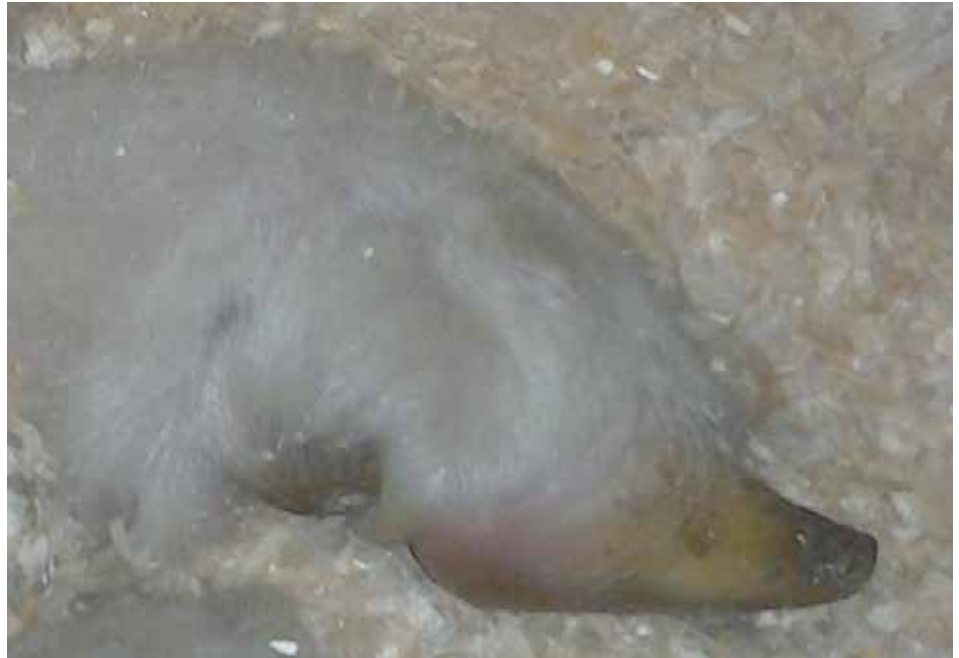**Figure 8b.7.2.**

Low power view of skeletal muscle collected from the thigh of a lamb that died due to ionophore (monensin) toxicity. Degenerative and necrotic muscle fibers shown.

## 8b.8. Laminitis (Founder)

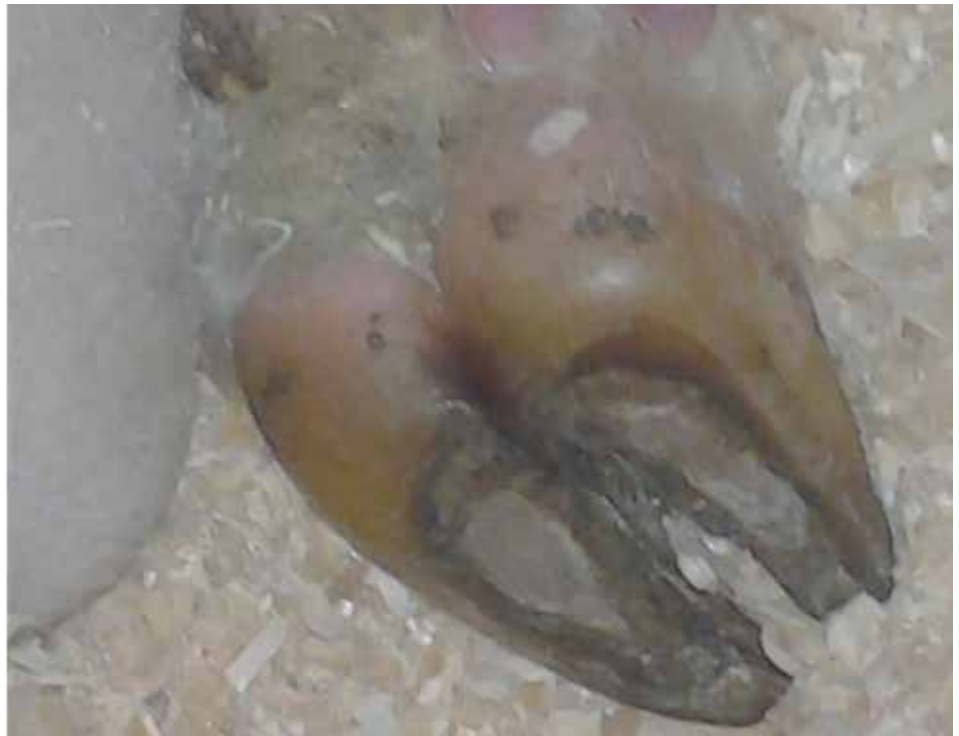**Figure 8b.8.1.**

Acute founder.  
*Photo courtesy of P. Menzies.*



**Figure 8b.8.2.**

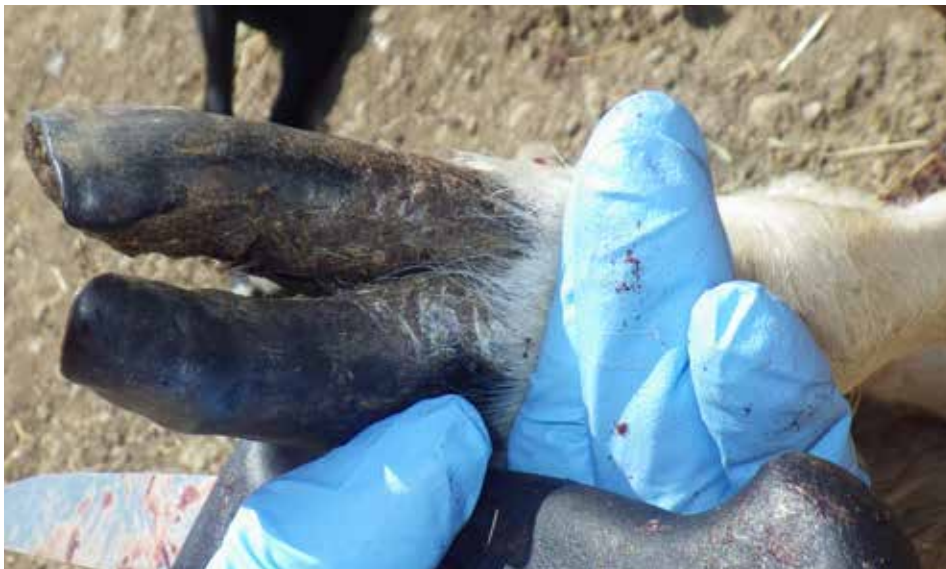Acute founder in a lamb.  
Animals are stiff to walk and  
sore on all 4 feet.  
*Photo courtesy of P. Menzies.*





**Figure 8b.8.3.**

Animal with long hooves caused by chronic laminitis due to grain overload (ruminitis). These animals will walk stiffly on the back of their heels.



**Figure 8b.8.4.**

Long claws with ridges on the surface of the claw typically seen with founder.



**Figure 8b.8.5.**

Long claws from chronic founder (laminitis) as a result of grain overload..



## IX. MISCELLANEOUS

### A. Teeth

- 1. Abscess.....228
- 2. Missing.....228

### B. Eye

- 1. Pinkeye.....229
- 2. Entropion.....229

### C. Congenital Defects

- 1. Cleft Palate.....231
- 2. Rectal Fistula .....231
- 3. Other .....232

## IX. Miscellaneous

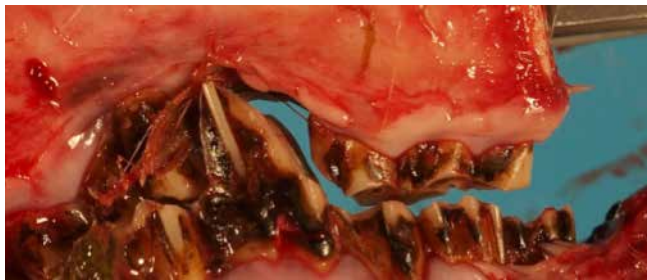### 9A. Teeth



**Figure 9a.1.1.**

Abscessed tooth. Notice swelling in jaw (arrow).

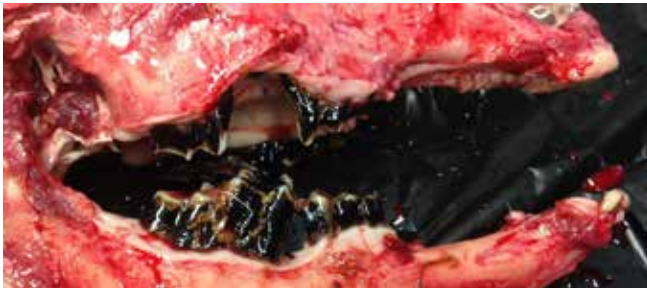*Photo courtesy of P. Menzies.*



**Figure 9a.2.1.**

Missing premolar.

*Photo courtesy of P. Menzies.*

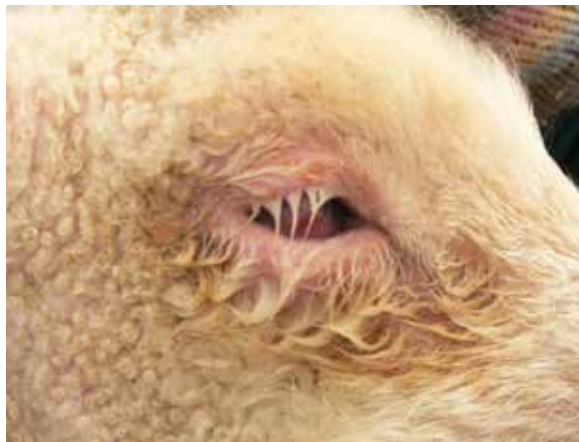

## 9B. Eye

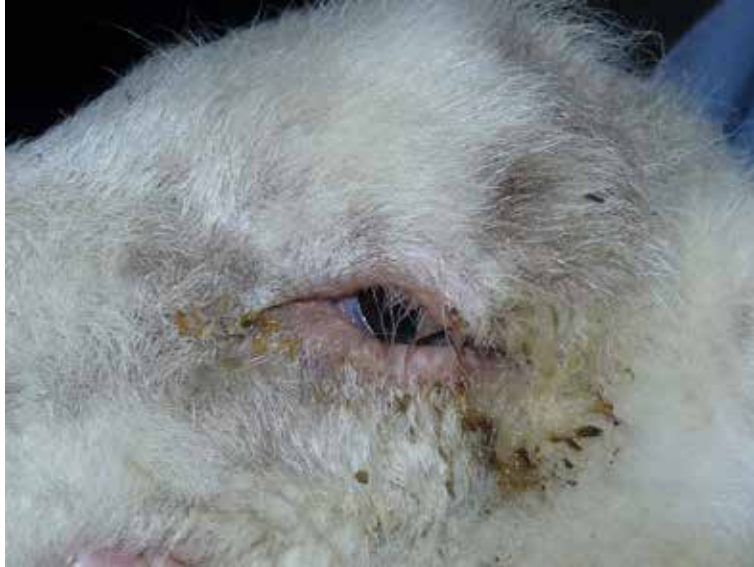**Figure 9b.1.1.**

Pinkeye or Infectious Keratoconjunctivitis is a highly infectious disease caused by various infectious agents include *Chlamydophila pecorum* and *Mycoplasma conjunctivae*. Affected animals will squint, tear, and may have a partially closed eye. There is hyperemia (redness) of the conjunctiva. The cornea of the eye becomes opaque (whitish in color) with vascularization. The disease can lead to corneal ulcers and blindness if not treated promptly.

*Photo courtesy of P. Menzies.*







**Figure 9b.2.1.**

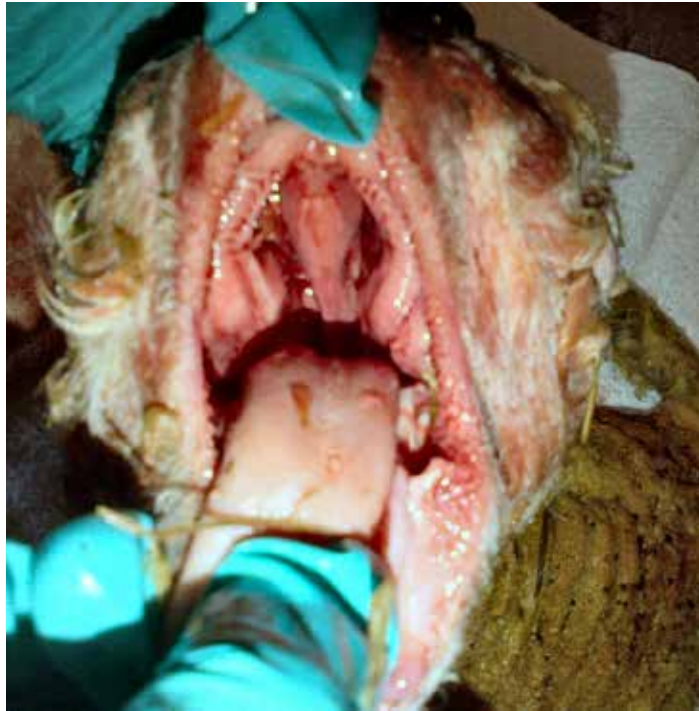Entropion of the eye is inversion of the lower eyelid. It is an inherited condition often seen in Suffolk-sired lambs and related to particular rams. There is epiphora, blepharospasm, and photophobia. Ocular discharge quickly becomes purulent. Direct contact between the eyelashes and cornea causes a severe keratitis and can lead to ulceration.

*Photo courtesy of P. Menzies.*

## 9C. Congenital Defects

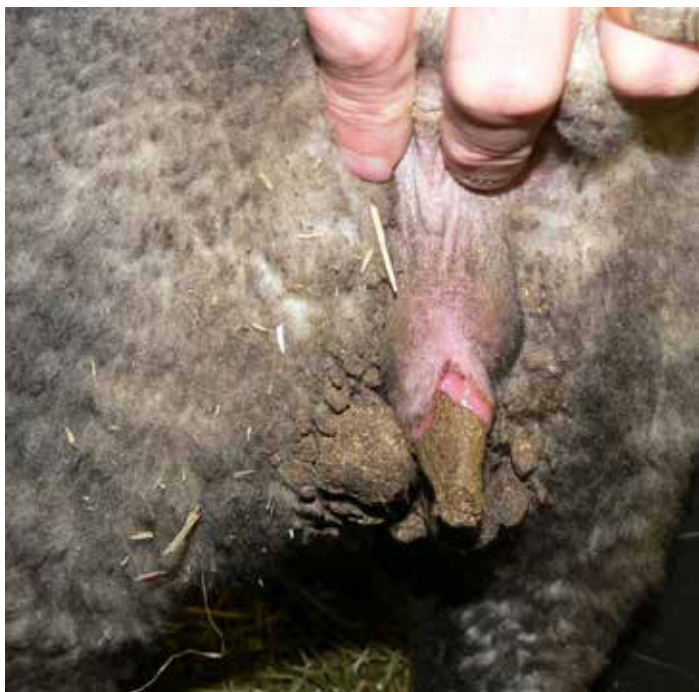**Figure 9c.1.1.**

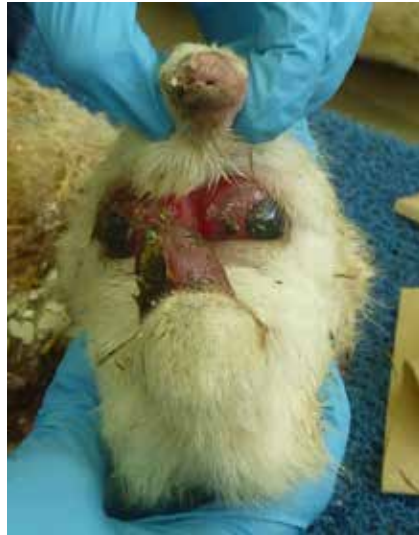Cleft palate  
*Photo courtesy of P. Menzies.*



**Figure 9c.2.1.**

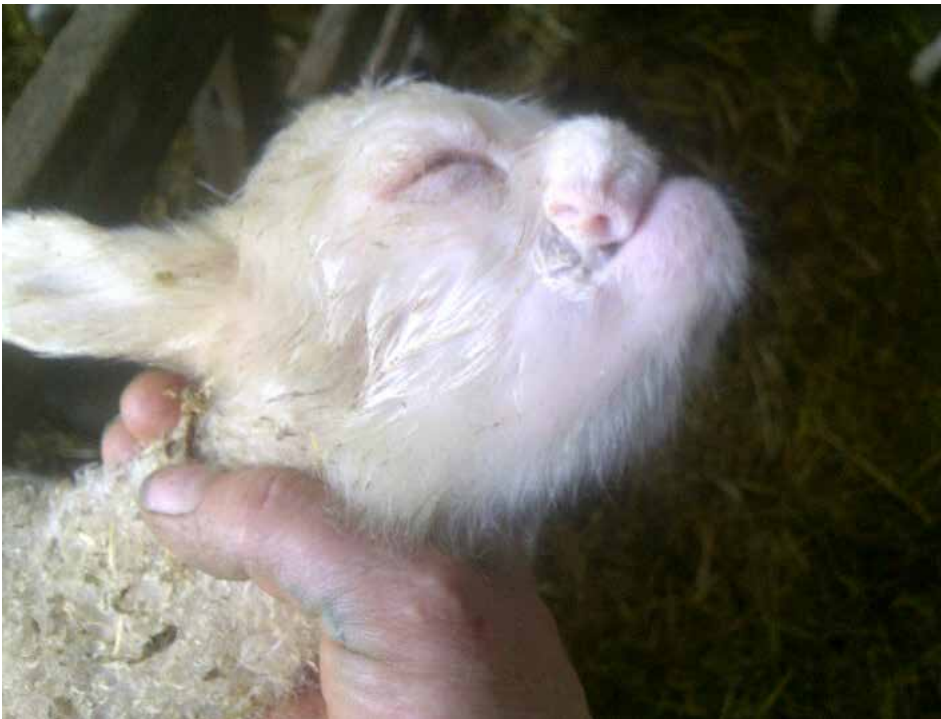Rectal Fistula.  
*Photo courtesy of P. Menzies.*





**Figure 9c.3.1.**

Congenital abnormalities at birth.  
*Photo courtesy of P. Menzies.*





<b>A</b>	
Abomasitis .....	92-96
Abortion/Stillbirth .....	178
Anemia due to <i>Hamonchus contortus</i> .....	2
Arterial Aneurism and Rupture .....	7
Arthritis .....	211
Aural Hematoma .....	204
<b>B</b>	
Bloat .....	102
Border Disease .....	191
Bronchitis/Bronchiolitis - Chronic .....	78
Bronchopneumonia - Chronic .....	46
Bronchopneumonia - Fibrinous .....	31
Bronchopneumonia - Suppurative .....	34
<b>C</b>	
Cache Valley Virus .....	192
Campylobacteriosis ( <i>Vibriosis</i> ) .....	151, 185
Caseous Lymphadenitis .....	9, 90, 154
Caudal Vena Cava Thrombosis .....	149
Cellulitis .....	205
Cestodiasis - hepatic .....	153
Chlamydiosis (Enzootic Abortion) .....	185
Claw abnormalities .....	213
Coccidiosis .....	104
CODD (Hairy Heel Warts) .....	217
Contagious Ecthyma/Orf .....	205
Copper Toxicity .....	132, 169
Cysticercosis .....	10
<b>D</b>	
Dermatitis .....	204
<b>E</b>	
Enteritis and Enterotoxaemias .....	112
Epididymitis .....	174
<b>F</b>	
Footrot .....	214
<b>G</b>	
Glomerulonephritis .....	171
Goiter .....	189
<b>H</b>	
Hardware Disease (reticuloperitonitis) .....	126
Heart Failure - Left Side .....	21
Heart Failure - Right Side .....	13
Hepatic Necrobacillosis .....	155
Hernia - Inguinal .....	120
Hydronephrosis .....	164
<b>I</b>	
Injuries .....	220
Intestinal Torsion .....	123
Intussusception .....	121
Ionophore Toxicity .....	224
<b>J</b>	
Johne's Disease .....	116
<b>L</b>	
Laminitis (Founder) .....	225
Laryngitis - Necrotic .....	82
Lice .....	207
Listeriosis .....	196
Liver - Fatty .....	147
Liver Fluke Infestation .....	137
<b>M</b>	
Mange .....	209
Metritis/Pyometra .....	177
Myocardial Abscessation .....	25
Myocarditis - Intersitial .....	24
Myocarditis - Necrotizing .....	28
<b>N</b>	
Nasal Adenocarcinoma .....	85
Nose Bleed .....	89
<b>P</b>	
Pericarditis and Epicarditis .....	21
Perirenal Hemorrhage .....	163
Peritonitis .....	124
Pleuritis .....	59
Pneumonia - Aspiration .....	80
Pneumonia - Embolic .....	60
Pneumonia - Interstitial .....	73
Pneumonia - Ovine Progressive (OPP) .....	87
Pneumonia - Verminous .....	76
Polioencephalomalacia .....	201
Prolapse - Rectal .....	129
Pulmonary Abscessation .....	84
Pulpy Kidney .....	172
Pyelonephritis .....	167
<b>Q</b>	
Q fever ( <i>Coxiellosis</i> ) .....	194
<b>R</b>	
Renal Infarcts .....	171
Ringworm .....	207
Rumenitis .....	97
<b>S</b>	
Septicemia - bacterial .....	109, 141, 165
Sheep Keds .....	208
<b>T</b>	
Tapeworm Infestation .....	127
<b>U</b>	
Urolithiasis (Waterbelly) .....	158
<b>W</b>	
White Muscle Disease/Nutritional Myopathy .....	222











